



PATIENT

Kemosable Fleming

SPECIES

Feline

BREED

Domestic Shorthair

SEX

Neutered male

AGE

1 year

WEIGHT

7.7 lbs

INTERPRETED BY

Eric Lindquist, DMV
DABVP, Cert. IVUSS

IMAGING PERFORMED BY

Dr. Griffin

HOSPITAL NAME

Northside VC

REFERRING VET

Dr. Griffin

INVOICE

91300

DATE

8/17/21

PRESENTING CLINICAL SIGNS

History: Acute Vomiting and Diarrhea that started 8/11 and did not respond to medical management
CBC:WNL CHEM: K+ 3.4 FPL: WNL Rads: radiopaque material in colon, no evidence of obstructive pattern

ULTRASONOGRAPHIC EXAMINATION OF THE ABDOMEN

Urinary System

The **urinary bladder**, trigone, and pelvic urethra presented normal thicknesses and normal tone. The ureters were not visible which is normal. No uroliths or sediment were visualized and anechoic urine was present. No evidence of inflammatory or neoplastic changes was noted. Ureteral papillae were normal.

The **kidneys** revealed normal size and structure, corticomedullary definition and ratio for this age. The cortices presented largely uniform texture with normal echogenic relationship to liver and spleen. Medullary structure differed distinctly from the cortex. The capsules were acceptably uniform without significant irregularities. Trace pyelectasia was noted in the right.

Adrenal Glands

Both **adrenal glands** were visualized and recognized as having normal shape, size, position and echogenicity for this breed. The phrenic vasculature, glandular echogenicity and detail were unremarkable. Capsule, cortex, and medullary definition were normal for this age patient. The left adrenal gland measured 0.4 cm. The right adrenal gland measured 0.3 cm.

Spleen

The **spleen** presented a smooth homogeneous parenchyma hyperechoic to liver and renal cortical parenchyma. The capsule was smooth without noticeable expansion or deviation from within the spleen or adjacent pathology. The splenic vasculature demonstrated normal volume without signs of congestion or thrombosis. No sonographic evidence of acute or chronic inflammatory, neoplastic, or infarctual changes was noted.

Liver

The **liver** images submitted revealed subjectively normal liver size, contour, and structure. Parenchymal echogenicity was naturally coarse and hypoechoic to the spleen. Vascular and biliary tracts were of normal volume with no evidence of congestion. Duplicated gallbladder was noted, yet not pathological.

Gastrointestinal

Examination of the **gastrointestinal tract** revealed a stomach and intestine free of stasis, of normal wall thickness, acceptable curvilinear mural detail, and peristaltic activity. Small and large intestine



PATIENT
Kemosable Fleming

SPECIES
Feline

BREED
Domestic Shorthair

SEX
Neutered male

AGE
1 year

WEIGHT
7.7 lbs

demonstrated normal luminal chyme and stool consistency respectively. The mesenteric lymph nodes presented a reactive pattern measuring 1.0 x 0.5 cm.

Pancreas

The base and limbs of the **pancreas** were observed to be largely isoechoic to surrounding omental fat. Pancreatic duct and capsular contour were acceptably normal and parenchyma respected normal curvilinear patterns. No overt evidence of active inflammatory or neoplastic disease was noted.

ULTRASONOGRAPHIC FINDINGS

Slight mesenteric lymphadenopathy, reactive.

Normal abdomen with slight right renal pyelectasia.

Duplicated gallbladder, which is a normal variant.

INTERPRETATION OF THE FINDINGS & FURTHER RECOMMENDATIONS

Urinalysis is warranted to assess for any evidence of urinary tract infection. Supportive GI care should prove effective.

INTERPRETED BY

Eric Lindquist, DMV
DABVP, Cert. IVUSS

IMAGING PERFORMED BY

Dr. Griffin

HOSPITAL NAME

Northside VC

REFERRING VET

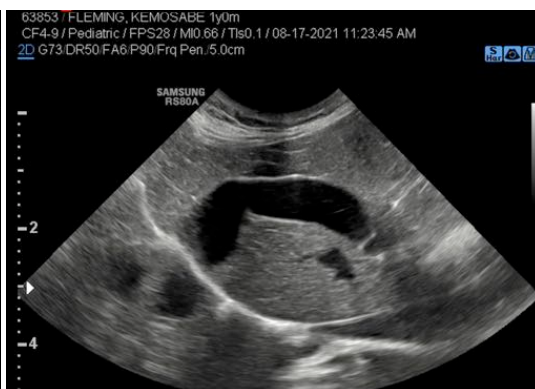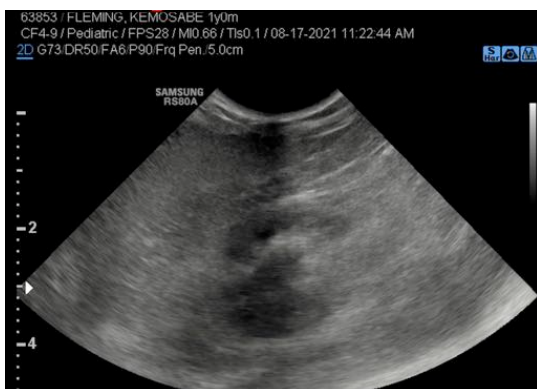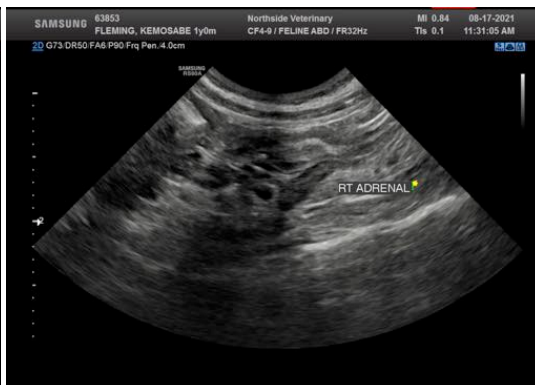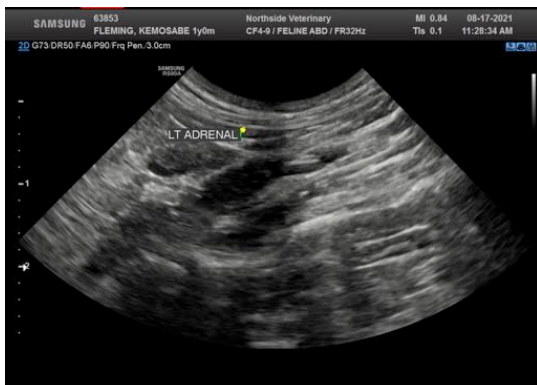Dr. Griffin

INVOICE

91300

DATE

8/17/21





PATIENT

Kemosable Fleming

SPECIES

Feline

BREED

Domestic Shorthair

SEX

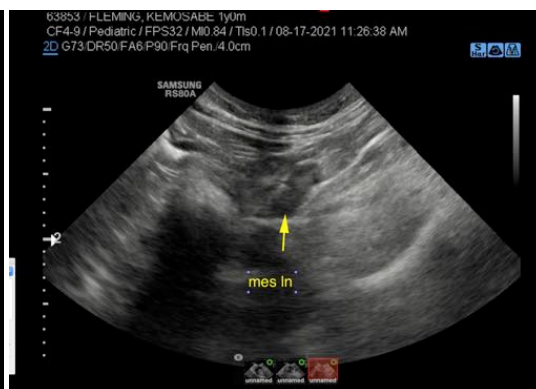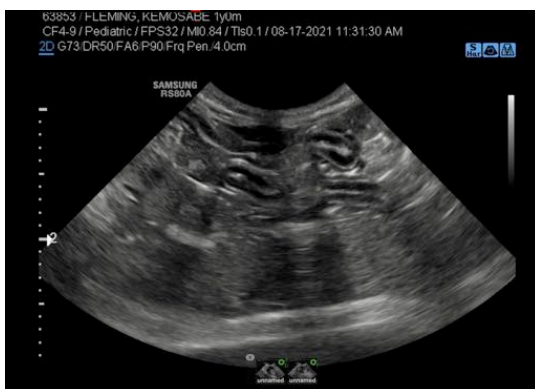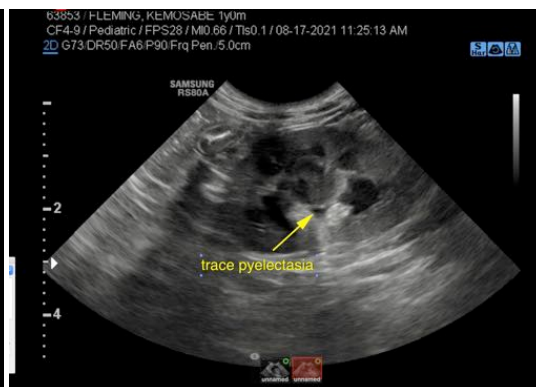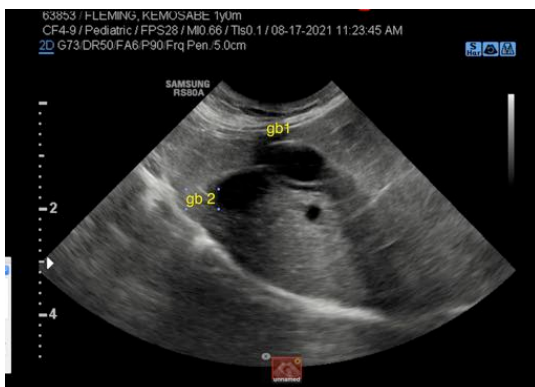
Neutered male

AGE

1 year

WEIGHT

7.7 lbs



INTERPRETED BY

Eric Lindquist, DMV
DABVP, Cert. IVUSS

IMAGING PERFORMED BY

Dr. Griffin

HOSPITAL NAME

Northside VC

REFERRING VET

Dr. Griffin

INVOICE

91300

DATE

8/17/21

The information and recommendations provided are based on the images presented by the referring veterinarian. No evaluation can be communicated regarding pathology that was not visible in the image/video clips provided.

Thank you for this referral. If the clinical or image interpretation does not parallel your findings or if I can be of any further assistance please contact me.

Eric Lindquist, DMV, DABVP, Cert. IVUSS, CEO of SonoPath.com
info@SonoPath.com