

PATIENT

Gabe Polansky

PRESENTING CLINICAL SIGNS

History: recheck , dog has been NPO for 24 hours , surgery ??

SPECIES

Canine

ULTRASONOGRAPHIC EXAMINATION OF THE ABDOMEN

Gastrointestinal

The **gastrointestinal tract** revealed persistent, progressively shadowing material such as cloth, rubber or similar. This material measured up to 2.5 cm and is similar to the prior sonogram. The small intestine and colon were unremarkable.

BREED

Terrier Mix

ULTRASONOGRAPHIC FINDINGS

Progressively shadowing material.

SEX

Male

INTERPRETATION OF THE FINDINGS & FURTHER RECOMMENDATIONS

Endoscopy or gastrotomy with evacuation of the GI tract and biopsies are indicated.

AGE

6 years

WEIGHT

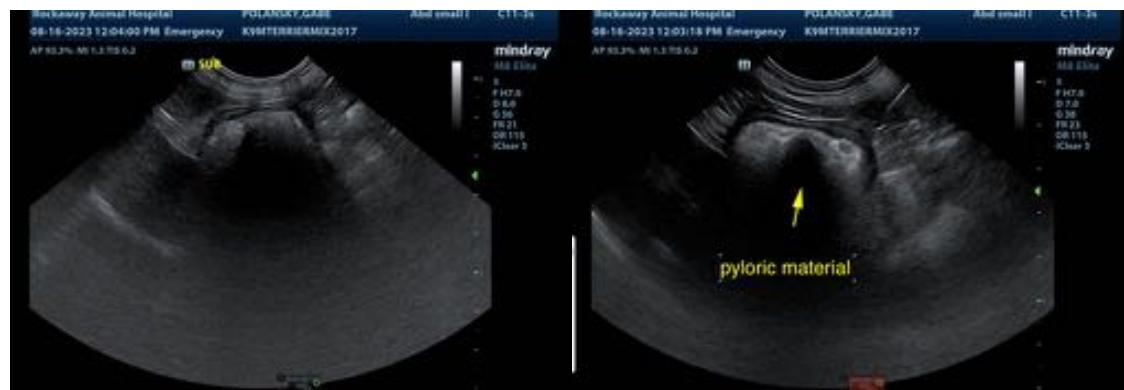
17.8 lbs

INTERPRETED BY

Eric Lindquist, DMV
DABVP, Cert. IVUSS

IMAGING PERFORMED BY

Jenn



HOSPITAL NAME

Rockaway AH

The information and recommendations provided are based on the images presented by the referring veterinarian/sonographer. No evaluation can be communicated regarding pathology that was not visible in the image/video clips provided.

REFERRING VET

Dr. Maniar

Thank you for this referral. If the clinical or image interpretation does not parallel your findings or if I can be of any further assistance please contact me.

Eric Lindquist, DMV, DABVP, Cert. IVUSS, CEO of SonoPath.com
info@SonoPath.com

INVOICE

46629

DATE

8/15/23