



PATIENT PRESENTING CLINICAL SIGNS

Blake Maher Recheck, was fed dinner last night accidentally, but has been NPO since

SPECIES LIMITED ULTRASONOGRAPHIC EXAMINATION

Canine **Gastrointestinal**

BREED The stomach revealed partially shadowing material up to 1.5 cm along with ingesta. The small intestine and colon were unremarkable.

Mix **ULTRASONOGRAPHIC FINDINGS**

- Delayed outflow pattern with likely small residual foreign matter

Spayed Female **INTERPRETATION OF THE FINDINGS & FURTHER RECOMMENDATIONS**

AGE Depending on what the patient ate prior to the sonogram, this is likely persistent foreign matter. However, endoscopy indicated.

3

WEIGHT

25

INTERPRETED BY

Eric Lindquist, DMV
DABVP, Cert. IVUSS

IMAGING PERFORMED BY

Jenn

HOSPITAL NAME

Rockaway AH

REFERRING VET

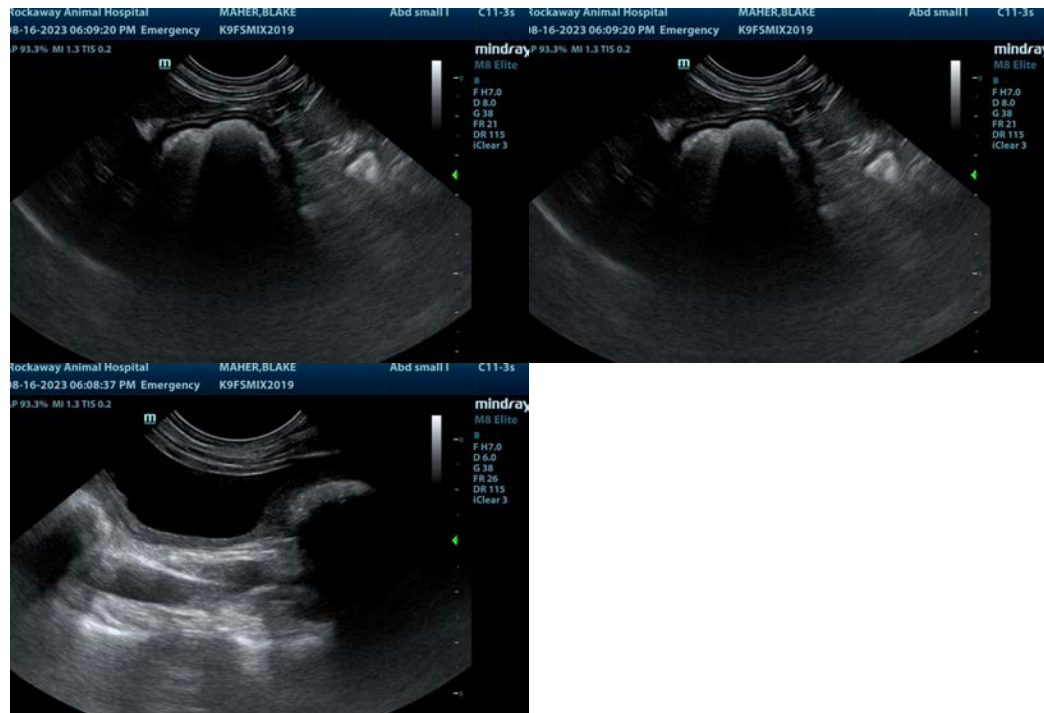
Dr. Maniar

INVOICE

44701

DATE

8/16/23



The information and recommendations provided are based on the images presented by the referring veterinarian/sonographer. No evaluation can be communicated regarding pathology that was not visible in the image/video clips provided.

Thank you for this referral. If the clinical or image interpretation does not parallel your findings or if I can be of any further assistance please contact me.

Eric Lindquist, DMV, DABVP, Cert. IVUSS, CEO of SonoPath.com

info@SonoPath.com