



PATIENT PRESENTING CLINICAL SIGNS

PATIENT Tiaga Fireside

SPECIES Canine

BREED Malamute

SEX Neutered Male

AGE 7 Years

WEIGHT 131.8 Pounds

INTERPRETED BY Eric Lindquist, DMV
DABVP, Cert. IVUSS

IMAGING PERFORMED BY Jenna Walsh, CVT

HOSPITAL NAME The Ark Vet Clinic

REFERRING VET Dr. Sangl

INVOICE 40527

DATE 8/16/22

Ambulatory x 3. Non weight bearing on R forelimb. Firm and painful swelling at R shoulder. Not well delineated as far as affected vs non-affected tissues. P is very painful and reactive when this area is touched. Did not attempt ROM evaluation. Reviewed prior DVM rads - showed normal bone structure in this area in beginning of June. Digit 2 had some visible bone changes and likely some mild medial carpal arthritic change present. Specialist is wanting FNA and chest rads be done. Gabapentan 600mg, Acepromazine 25mg, carprofen 100mg

ULTRASONOGRAPHIC EXAMINATION RIGHT SHOULDER REGION

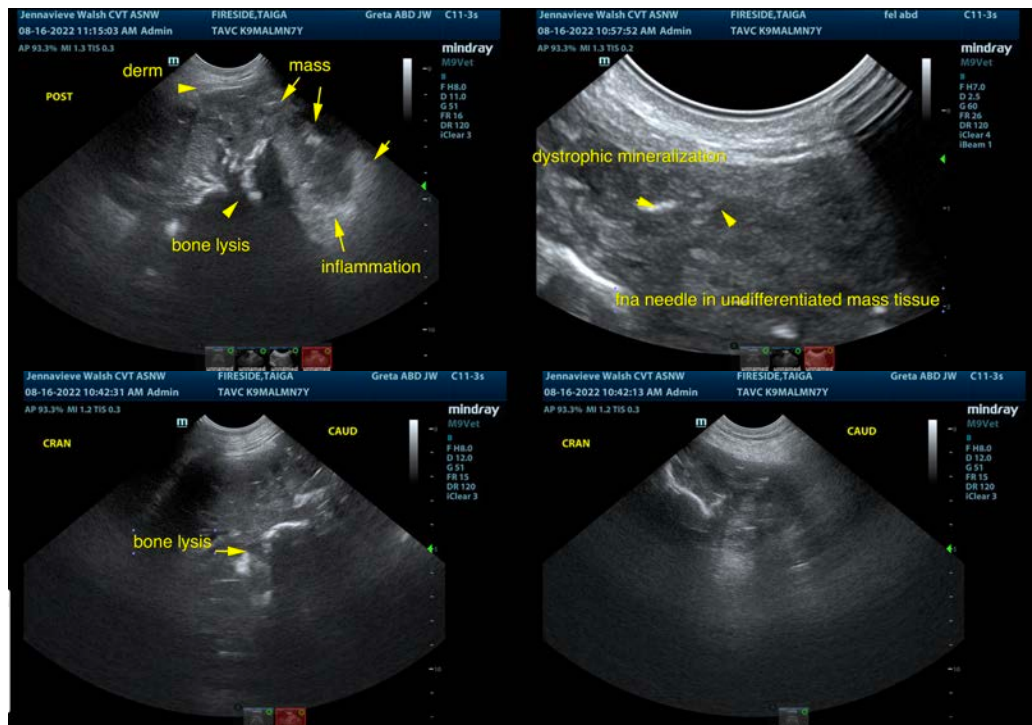
A mineralized hypochoic expansive, undifferentiated mass was noted in the shoulder region with underlying periosteal reactivity and irregular contour. The tissue portion of the mass thickness reached to a level of 3.0 cm of depth. Strongly suggestive for carcinoma such as chondrosarcoma or similar. The margins of the mass were unable to be defined well, yet involves bone as well as tissue extending to the subcutaneous space. Reactive fat also noted, consistent with inflammation.

ULTRASONOGRAPHIC FINDINGS

- Undifferentiated chondrosarcoma type mass with regional inflammation

INTERPRETATION OF THE FINDINGS & FURTHER RECOMMENDATIONS

CT evaluation for potential surgical planning warranted regarding limb sparing versus amputation. Abdominal sonogram and chest radiographs warranted if not already performed. Areas of lytic bone also noted. Regional lymph nodes should be evaluated for metastatic disease.





PATIENT

Tiaga Fireside

SPECIES

Canine

BREED

Malamute

SEX

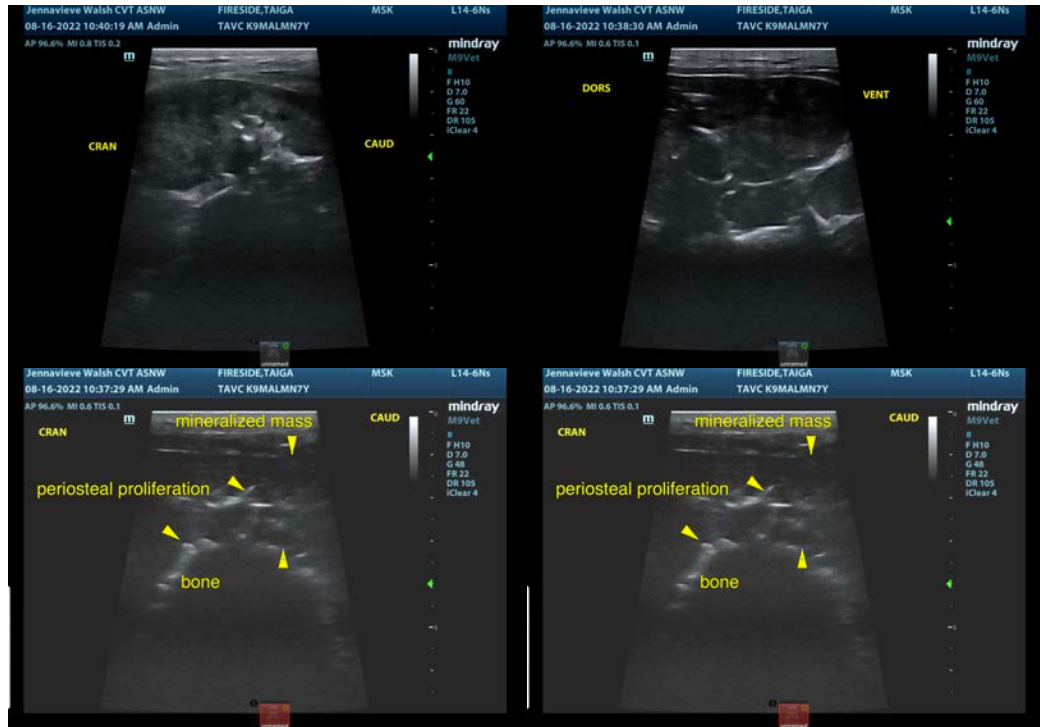
Neutered Male

AGE

7 Years

WEIGHT

131.8 Pounds



INTERPRETED BY

Eric Lindquist, DMV
DABVP, Cert. IVUSS

IMAGING PERFORMED BY

Jenna Walsh, CVT

HOSPITAL NAME

The Ark Vet Clinic

REFERRING VET

Dr. Sangl

INVOICE

40527

DATE

8/16/22

The information and recommendations provided are based on the images presented by the referring veterinarian/sonographer. No evaluation can be communicated regarding pathology that was not visible in the image/video clips provided.

Thank you for this referral. If the clinical or image interpretation does not parallel your findings or if I can be of any further assistance please contact me.

Eric Lindquist, DMV, DABVP, Cert. IVUSS, CEO of SonoPath.com
info@SonoPath.com