



PATIENT

Millie Snell

SPECIES

Canine

BREED

Mix

SEX

Spayed Female

AGE

14 Years

WEIGHT

6.3 Pounds

INTERPRETED BY

Eric Lindquist, DMV
DABVP, Cert. IVUSS

IMAGING PERFORMED BY

Eric Lindquist, DMV
DABVP, Cert. IVUSS

HOSPITAL NAME

All Creatures Great and
Small, Denville

REFERRING VET

Dr. Ashmore

INVOICE

16879

DATE

8/16/22

PRESENTING CLINICAL SIGNS

Hematuria, hematochezia, CPL- Abnormal

Current meds: Flagyl, Amox, Famotidine, Simethicone

ULTRASONOGRAPHIC EXAMINATION OF THE ABDOMEN

Urinary System

The **urinary bladder**, trigone, and pelvic urethra presented normal thicknesses and normal tone. The ureters were not visible which is normal. No uroliths or sediment were visualized and anechoic urine was present. No evidence of inflammatory or neoplastic changes were noted. Ureteral papillae were normal.

The **kidneys** revealed largely normal size and structure, corticomedullary definition and ratio (cortex 1/3 of medulla) were essentially maintained with some minor age-related loss of curvilinear patterns regarding the capsule and C/M junction. The cortices presented largely uniform texture with some increased echogenicity expected for his age patient. Medullary structure differed distinctly from that of the cortex and no evidence of pelvic dilation was present. Mineralization was present in the kidneys. The left kidney measured 3.26 cm. The right kidney measured 3.22 cm.

Adrenal Glands

Both **adrenal glands** were visualized and recognized as having normal shape, size, position and echogenicity for this breed. The phrenic vasculature, glandular echogenicity and detail were unremarkable. Capsule, cortex, and medullary definition were normal for this age patient. The left adrenal gland measured 1.81 cm x 0.64 cm. The right adrenal gland measured 1.25 cm x 0.7 cm at the cranial pole and 0.5 cm at the caudal pole.

Spleen

The **spleen** presented a smooth homogeneous parenchyma hyperechoic to liver and renal cortical parenchyma. The capsule was smooth without noticeable expansion or deviation from within the spleen or adjacent pathology. The splenic vasculature demonstrated normal volume without signs of congestion or thrombosis. No sonographic evidence of acute or chronic inflammatory, neoplastic, or infarctual changes were noted.

Liver

The **liver** images from right and left intercostal as well as subcostal views revealed subjectively normal contour, and structure. The liver was slightly subnormal in size. Some minor age-related parenchymal remodeling was noted but likely not clinically significant at this time. Vascular and biliary tracts were of normal volume and no evidence of congestion was noted. The gallbladder presented some dependent debris with essentially normal contour. The cystic and common bile ducts were normal. No overt evidence of active inflammatory, infiltrative or regenerative pathology was noted but should be paired with current or past LE elevations regarding any clinical significance to this presentation. The hepatic lymph nodes were unremarkable.

Gastrointestinal



PATIENT

Millie Snell

SPECIES

Canine

BREED

Mix

SEX

Spayed Female

AGE

14 Years

WEIGHT

6.3 Pounds

INTERPRETED BY

Eric Lindquist, DMV
DABVP, Cert. IVUSS

IMAGING PERFORMED BY

Eric Lindquist, DMV
DABVP, Cert. IVUSS

HOSPITAL NAME

All Creatures Great and
Small, Denville

REFERRING VET

Dr. Ashmore

INVOICE

16879

DATE

8/16/22

The upper **gastrointestinal tract** in this patient revealed minor, edematous wall. There was no evidence of foreign bodies. Minor areas of fluctuant fluid accumulation were noted within the lumen with hyperperistalsis. The colonic wall was significantly thickened, measuring 0.58 cm without loss of mural detail. Hypertrophied mucosal was noted. This presentation is most consistent with gastrointestinal irritation/inflammation without obstruction. No evidence of masses.

Pancreas

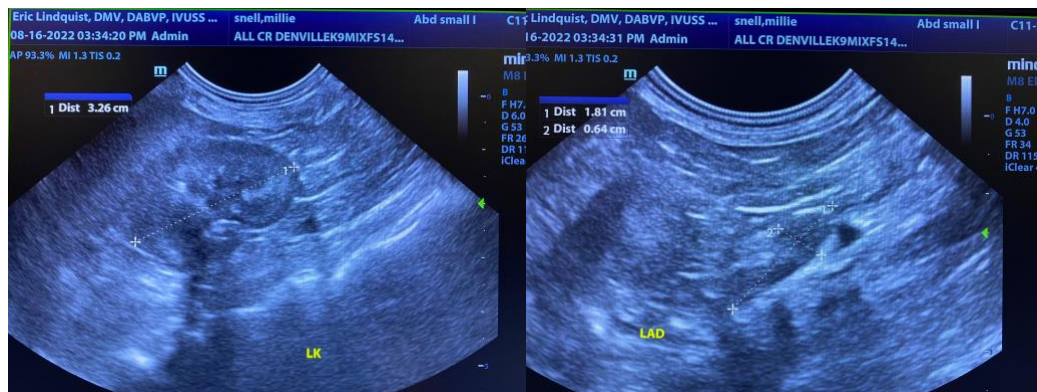
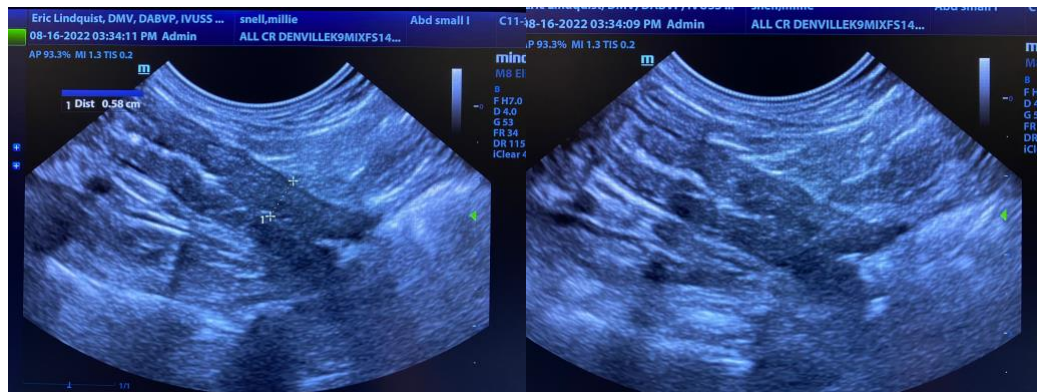
The base and limbs of the **pancreas** were observed to be largely isoechoic to surrounding omental fat. Pancreatic duct and capsular contour were acceptably normal and parenchyma respected normal curvilinear patterns. No overt evidence of active inflammatory or neoplastic disease was noted.

ULTRASONOGRAPHIC FINDINGS

- Gastroenteritis/colitis pattern
- Minor nonobstructive nephrolithiasis
- Age-related hepatic changes with slightly subnormal liver size
- Age-related abdominal changes otherwise

INTERPRETATION OF THE FINDINGS & FURTHER RECOMMENDATIONS

No neoplastic criteria is present. Colonoscopy would be ideal in this patient. I recommend a fresh fecal smear and fecal floatation analysis. Broad spectrum antiparasitic protocol, hydrolyzed diet, enrofloxacin/metronidazole combination and treatment for Baytril responsive and other types of colitis. Recheck sonogram in 7-10 days if clinical signs are persistent.





PATIENT

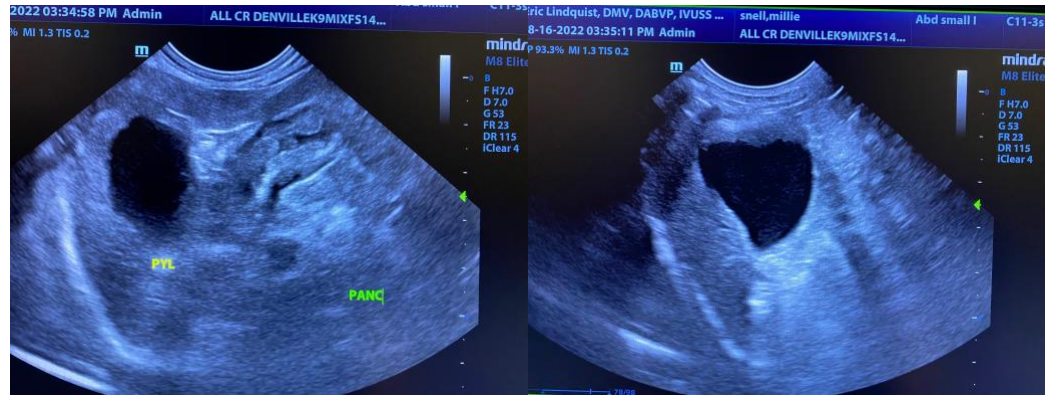Millie Snell

SPECIES

Canine

BREED

Mix



SEX

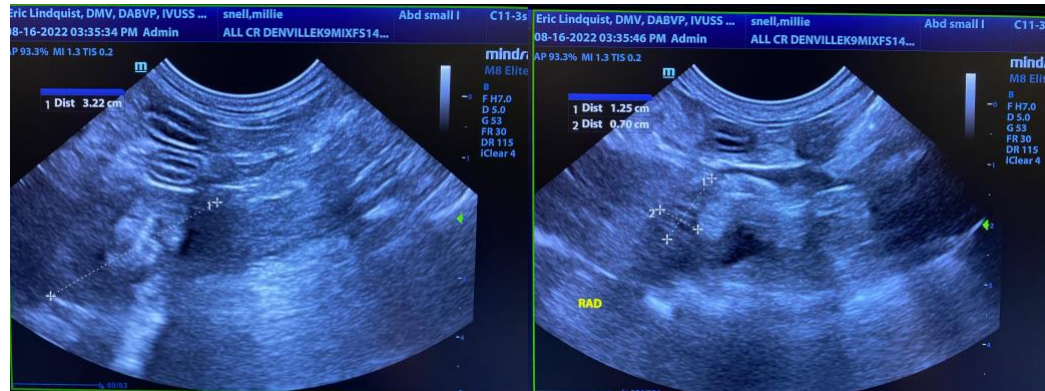
Spayed Female

AGE

14 Years

WEIGHT

6.3 Pounds

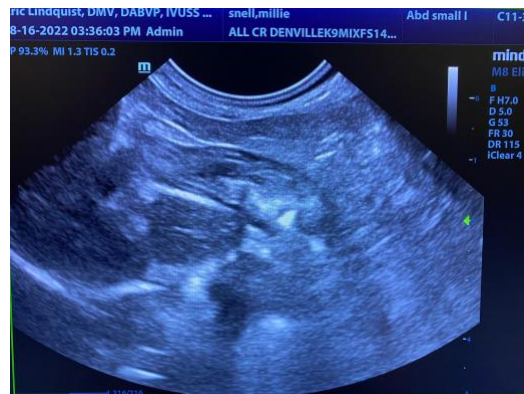


INTERPRETED BY

Eric Lindquist, DMV
DABVP, Cert. IVUSS

IMAGING PERFORMED BY

Eric Lindquist, DMV
DABVP, Cert. IVUSS



HOSPITAL NAME

All Creatures Great and
Small, Denville

REFERRING VET

Dr. Ashmore

INVOICE

16879

DATE

8/16/22

The information and recommendations provided are based on the images presented by the referring veterinarian. No evaluation can be communicated regarding pathology that was not visible in the image/video clips provided.

Thank you for this referral. If the clinical or image interpretation does not parallel your findings or if I can be of any further assistance please contact me.

Eric Lindquist, DMV, DABVP, Cert. IVUSS, CEO of SonoPath.com
info@SonoPath.com