



**PATIENT PRESENTING CLINICAL SIGNS**

Kitty Hernandez increased SDMA, coughing alot at home

**SPECIES ULTRASONOGRAPHIC EXAMINATION OF THE HEART**

Canine

BREED

Poodle

SEX

Spayed Female

AGE

12 Years

WEIGHT

18 Pounds

CANINE CARDIAC PARAMETERS	MR VMAX (m/s)	TR VMAX (m/s)	LA/AO (Boon method)	LA/AO (Heart Base; Swe)	FS (%)	EF (%)	EPSS (cm)
NORMAL PARAMETER	4.5-5.5	<2.7	1.3	<1.6	28-40	40-100	<0.6
PATIENT			1.0	--	35	65	NM
CANINE CARDIAC PARAMETERS	HR (BPM)	AV VMAX (m/s)	PV MAX (m/s)	BODY WEIGHT (kg)	LA 2D short axis Base view (cm)	LVIDd Avg; 2D and m-mode short axis (cm)	LVIDs Avg; 2D and m-mode short axis (cm)
NORMAL PARAMETER	50-100	0.7-1.7	0.7-1.6	BELOW	BELOW	BELOW	BELOW
PATIENT	--	1.3	1.1		2.3	1.8	

**Cardiac Presentation**

**INTERPRETED BY**

Eric Lindquist, DMV

DABVP, Cert. IVUSS

**IMAGING PERFORMED BY**

Jenn

**HOSPITAL NAME**

Rockaway AH

**REFERRING VET**

Dr. Maniar

**INVOICE**

40487

**DATE**

8/16/22

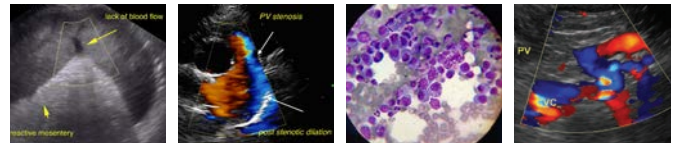
The **echocardiogram** presented a prominent **right heart** with concentric **right ventricular** hypertrophy, likely owing to increased respiratory pressures, without significant **tricuspid** regurgitation, and with normal **right atrial** size. No evidence of neoplasia was noted in the right auricle, or elsewhere in the heart. The **pulmonary artery** was uniformly prominent with mildly depressed pulmonic velocity measured on PW Doppler. No overt heartworms were noted in the main or visible deep pulmonary arteries. Yet, theoretically heartworms could be present in the deep pulmonary vasculature out of visible sonographic range. More likely, however, this prominent right heart is due to excessive intra-thoracic pressures caused by chronic respiratory disease or potentially excessive intra-thoracic fat (Pickwickian syndrome). The **left heart** demonstrated a linear **ventricular septum**. Contractility was functionally adequate demonstrated by the FS% measurement. Trivial mitral insufficiency noted. No significant **left atrial** dilation was noted. The **left ventricular outflow** demonstrated normal flow patterns and velocities through the aortic valve. No evidence of tumor, pericardial or pleural effusion was noted. The visible **extra-cardiac** tissues were uniformly linear without evidence of masses, infiltrative or inflammatory mediastinal tissue. No evident arrhythmic activity was noted during the exam.

**ULTRASONOGRAPHIC FINDINGS**

- Cor pulmonale presentation
- Trivial mitral insufficiency

**INTERPRETATION OF THE FINDINGS & FURTHER RECOMMENDATIONS**

The cough is non-cardiogenic in this patient. Primary respiratory protocol warranted. Assessment for tracheal collapse or other primary respiratory disease indicated.



**PATIENT**

Kitty Hernandez

**SPECIES**

Canine

**BREED**

Poodle

**SEX**

Spayed Female

**AGE**

12 Years

**WEIGHT**

18 Pounds

**INTERPRETED BY**

Eric Lindquist, DMV  
DABVP, Cert. IVUSS

**IMAGING PERFORMED BY**

Jenn

**HOSPITAL NAME**

Rockaway AH

**REFERRING VET**

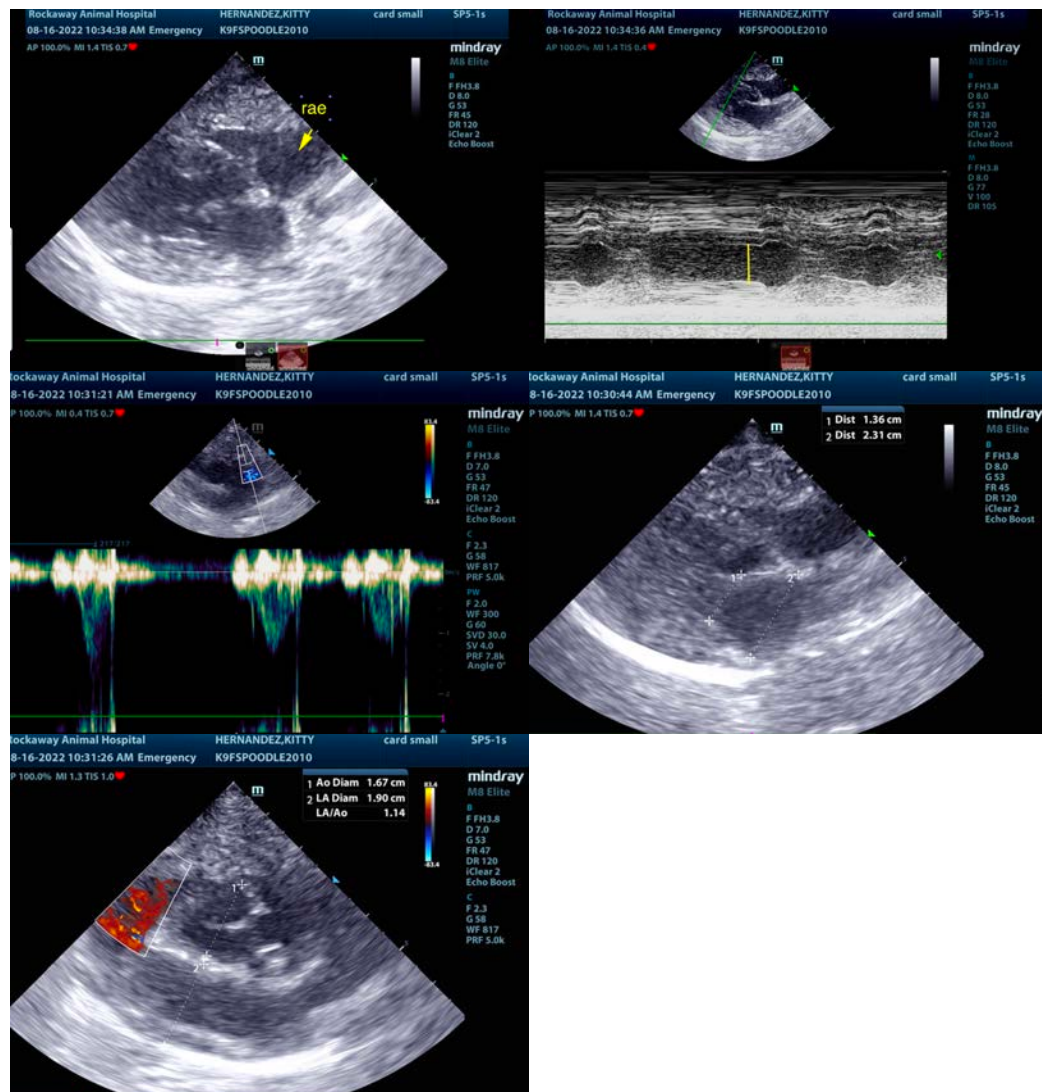
Dr. Maniar

**INVOICE**

40487

**DATE**

8/16/22



The information and recommendations provided are based on the images presented by the referring veterinarian/sonographer. No evaluation can be communicated regarding pathology that was not visible in the image/video clips provided.

Thank you for this referral. If the clinical or image interpretation does not parallel your findings or if I can be of any further assistance please contact me.

Eric Lindquist, DMV, DABVP, Cert. IVUSS, CEO of SonoPath.com

[info@SonoPath.com](mailto:info@SonoPath.com)