



**PATIENT**

Gus Rinier

**SPECIES**

Canine

**BREED**

Labradoodle

**SEX**

Neutered Male

**AGE**

2 Years

**WEIGHT**

64.2 Pounds

**INTERPRETED BY**

Eric Lindquist, DMV

DABVP, Cert. IVUSS

**IMAGING PERFORMED BY**

Jack Reese

**HOSPITAL NAME**

Willow Run VC

**REFERRING VET**

Dr. Molly Arnold

**INVOICE**

40489

**DATE**

8/16/22

**PRESENTING CLINICAL SIGNS**

Acute history of vomiting and lethargy. P vomited 15-20 times yesterday - liquid and mucus. No food contents. Anorexic with severe lethargy. BW and radiographs were conducted at referral and were unremarkable. Today, P is quiet but responsive. Has laid around all day and shown no interest in food or water. There has been no further vomiting since cerenia injection last night. Abdomen remains painful on palpation.

Abnormal PE/Chem/CBC/UA Results: CBC/Chem 17/Lytes - WNL

**ULTRASONOGRAPHIC EXAMINATION OF THE ABDOMEN**

**Urinary System**

The **urinary bladder**, trigone, and pelvic urethra presented normal thicknesses and normal tone. The ureters were not visible which is normal. No uroliths or sediment were visualized and anechoic urine was present. No evidence of inflammatory or neoplastic changes were noted. Ureteral papillae were normal.

The **kidneys** revealed normal size and structure, corticomedullary definition and ratio for this age. The cortices presented largely uniform texture with normal echogenic relationship to liver and spleen. Medullary structure differed distinctly from the cortex and no evidence of pelvic dilation was present. The capsules were acceptably uniform without significant irregularities. The right kidney measured 6.4 cm. The left kidney measured 6.1 cm.

**Adrenal Glands**

Both **adrenal glands** were visualized and recognized as having normal shape, size, position and echogenicity for this breed. The phrenic vasculature, glandular echogenicity and detail were unremarkable. Capsule, cortex, and medullary definition were normal for this age patient. The left adrenal gland measured 0.30 cm. The right adrenal gland measured 0.65 cm at the caudal pole and 1.46 cm at the cranial pole.

**Spleen**

The **spleen** presented a smooth homogeneous parenchyma hyperechoic to liver and renal cortical parenchyma. The spleen was folded upon itself cranially. The capsule was smooth without noticeable expansion or deviation from within the spleen or adjacent pathology. The splenic vasculature demonstrated normal volume without signs of congestion or thrombosis. No sonographic evidence of acute or chronic inflammatory, neoplastic, or infarctual changes were noted.

**Liver**

The **liver** images submitted revealed subjectively normal liver size, contour, and structure. Parenchymal echogenicity was naturally coarse and hypoechoic to the spleen. Vascular and biliary tracts were of normal volume with no evidence of congestion. The gallbladder presented acceptably thin walls with primarily anechoic content. The cystic and common bile ducts were normal. No pathological hepatic lymphadenopathy was evident. No overt structural evidence of inflammatory, infiltrative or regenerative pathology was evident.

**Gastrointestinal**

Minor fluid and gas filled **gastric** lumen, yet no obstructive pattern. The gastric wall was slightly thickened at 1.0 cm. The small intestine and colon were unremarkable.



**PATIENT**

**Pancreas**

Gus Rinier

The base and limbs of the **pancreas** were observed to be largely isoechoic to surrounding omental fat. Pancreatic duct and capsular contour were acceptably normal and parenchyma respected normal curvilinear patterns. No overt evidence of active inflammatory or neoplastic disease was noted.

**SPECIES**

Canine

**ULTRASONOGRAPHIC FINDINGS**

- Non-specific gastritis

**BREED**

Labradoodle

**INTERPRETATION OF THE FINDINGS & FURTHER RECOMMENDATIONS**

24 hour NPO, anti-parasitic protocol, and a clinical trial of the following may prove effective.

**SEX**

Neutered Male

**Helicobacter/Gastritis protocol**

A clinical trial of **Zithromax** (Dogs: 5-10 mg/kg p.o. q24h. May increase dosing interval to q48h after 3-5 days of treatment), **Metronidazole** (10-20 mg/kg p.o. b.i.d.), **Pepcid** (0.5-1 mg/kg s.i.d.) and **Sucralfate** (0.5-2 g/dog PO) or **Omeprazole** (1 mg/kg p.o. s.i.d.) over the next 3 weeks along with a **novel-protein or hydrolyzed diet** with slurry feeding b.i.d./t.i.d. over the next 2-4 days and then increase to canned diet bid. Dry food should be avoided over the next 4 weeks. A recheck sonogram to assess GI improvement or progression would be ideal in 4 weeks.

**AGE**

2 Years

**WEIGHT**

64.2 Pounds

**INTERPRETED BY**

Eric Lindquist, DMV

DABVP, Cert. IVUSS

**IMAGING PERFORMED BY**

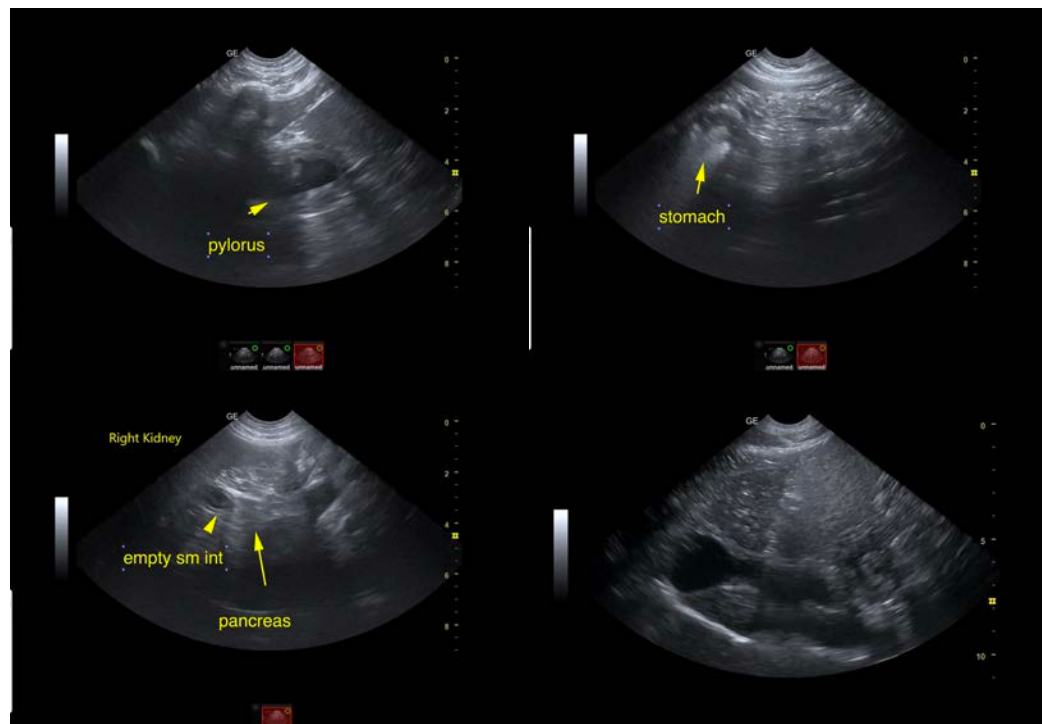
Jack Reese

**HOSPITAL NAME**

Willow Run VC

**REFERRING VET**

Dr. Molly Arnold



**INVOICE**

40489

**DATE**

8/16/22



**PATIENT**

Gus Rinier

**SPECIES**

Canine

**BREED**

Labradoodle

**SEX**

Neutered Male

**AGE**

2 Years

**WEIGHT**

64.2 Pounds

**INTERPRETED BY**

Eric Lindquist, DMV

DABVP, Cert. IVUSS

**IMAGING PERFORMED BY**

Jack Reese

**HOSPITAL NAME**

Willow Run VC

**REFERRING VET**

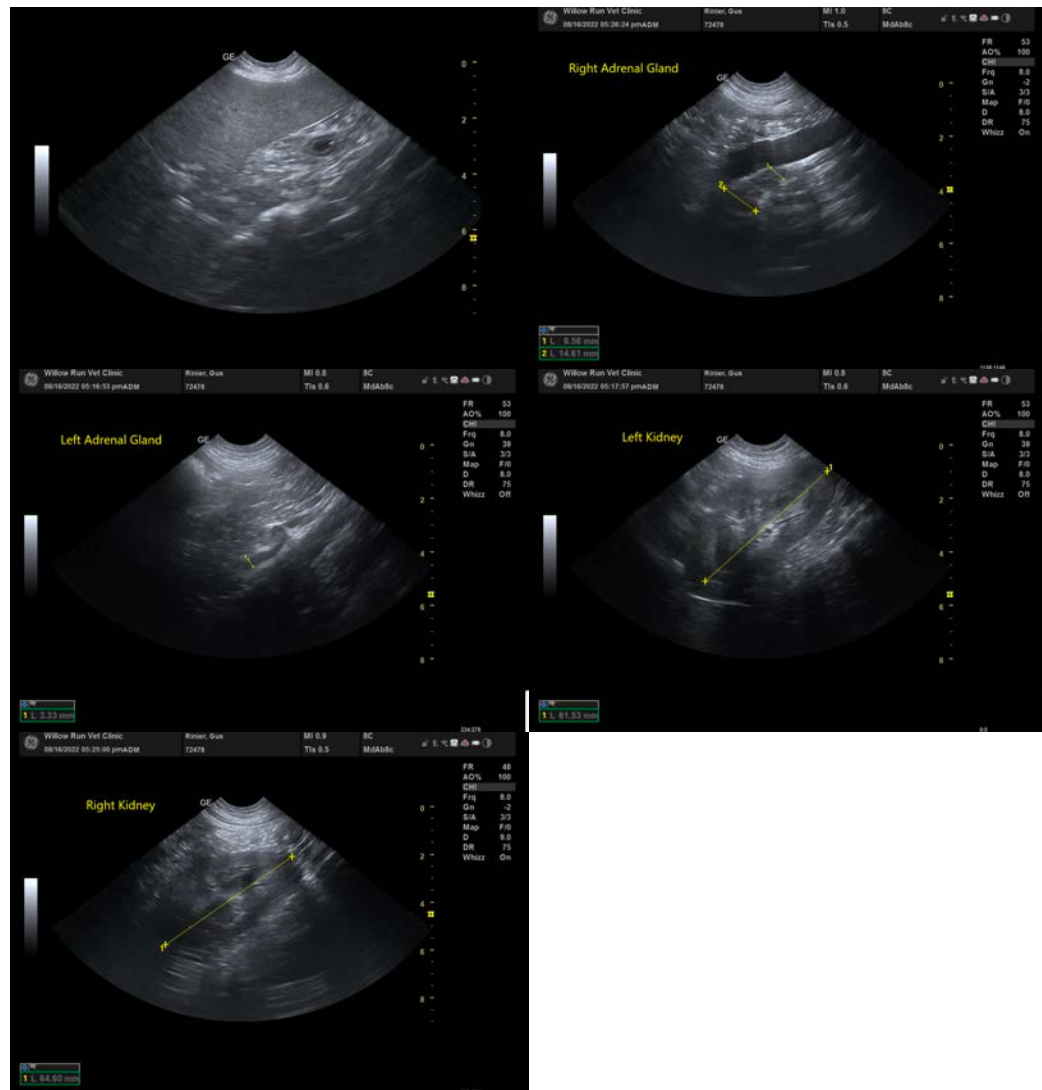
Dr. Molly Arnold

**INVOICE**

40489

**DATE**

8/16/22



The information and recommendations provided are based on the images presented by the referring veterinarian/sonographer. No evaluation can be communicated regarding pathology that was not visible in the image/video clips provided.

Thank you for this referral. If the clinical or image interpretation does not parallel your findings or if I can be of any further assistance please contact me.

**Eric Lindquist, DMV, DABVP, Cert. IVUSS, CEO of SonoPath.com**

[info@SonoPath.com](mailto:info@SonoPath.com)