



**PATIENT**

Ellie Golden Bond  
Rescue

**SPECIES**

Canine

**BREED**

Golden Retriever

**SEX**

Spayed female

**AGE**

5 ½ years

**WEIGHT**

57 lbs

**INTERPRETED BY**

Eric Lindquist, DMV  
DABVP, Cert. IVUSS

**IMAGING PERFORMED BY**

Dr. Preston

**HOSPITAL NAME**

All Creatures AH South  
Hill

**REFERRING VET**

Dr. Preston

**INVOICE**

32364

**DATE**

8/17/22

**PRESENTING CLINICAL SIGNS**

History: Newly acquired from Korea. Previously diagnosed and treated for heartworm. Currently positive for anaplasmosis. Increased liver enzymes

Abnormal PE/Chem/CBC/UA Results: ALT 290, ALKP 794

**ULTRASONOGRAPHIC EXAMINATION OF THE ABDOMEN**

**Urinary System**

The **urinary bladder**, trigone, and pelvic urethra presented normal thicknesses and normal tone. The ureters were not visible which is normal. No uroliths or sediment were visualized and anechoic urine was present. No evidence of inflammatory or neoplastic changes was noted. Ureteral papillae were normal.

The uterine stump was uniform and measured 0.4 cm.

The **kidneys** revealed normal size and structure, corticomedullary definition and ratio for this age. The cortices presented largely uniform texture with normal echogenic relationship to liver and spleen. Medullary structure differed distinctly from the cortex and no evidence of pelvic dilation was present. The capsules were acceptably uniform without significant irregularities. The kidneys measured 6.0 cm each.

**Adrenal Glands**

The left adrenal gland was slightly heterogenous and slightly swollen at the cranial pole. The left adrenal gland measured 1.8 cm and the caudal pole measured 0.75 cm. The right adrenal gland was uniform and measured 2.15 x 0.53 cm.

**Spleen**

The **spleen** presented a smooth homogeneous parenchyma hyperechoic to liver and renal cortical parenchyma. The capsule was smooth without noticeable expansion or deviation from within the spleen or adjacent pathology. The splenic vasculature demonstrated normal volume without signs of congestion or thrombosis. No sonographic evidence of acute or chronic inflammatory, neoplastic, or infarctual changes was noted.

**Liver**

The **liver** images submitted revealed subjectively normal liver size, contour, and structure. Parenchymal echogenicity was naturally coarse and hypoechoic to the spleen. Vascular and biliary tracts were of normal volume with no evidence of congestion. The gallbladder presented acceptably thin walls with primarily anechoic content. The cystic and common bile ducts were normal. No pathological hepatic lymphadenopathy was evident. No overt structural evidence of inflammatory, infiltrative or regenerative pathology was evident.



**PATIENT**

Ellie Golden Bond  
Rescue

**SPECIES**

Canine

**BREED**

Golden Retriever

**SEX**

Spayed female

**AGE**

5 ½ years

**WEIGHT**

57 lbs

**INTERPRETED BY**

Eric Lindquist, DMV  
DABVP, Cert. IVUSS

**IMAGING PERFORMED BY**

Dr. Preston

**HOSPITAL NAME**

All Creatures AH South  
Hill

**REFERRING VET**

Dr. Preston

**INVOICE**

32364

**DATE**

8/17/22

**Gastrointestinal**

Examination of the **gastrointestinal tract** revealed a stomach and intestine free of stasis, of normal wall thickness, acceptable curvilinear mural detail, and peristaltic activity. Small and large intestine demonstrated normal luminal chyme and stool consistency respectively. No obstructive or overt infiltrative disease was noted. No associated abnormal lymphatic activity was noted.

**Pancreas**

The base and limbs of the **pancreas** were observed to be largely isoechoic to surrounding omental fat. Pancreatic duct and capsular contour were acceptably normal and parenchyma respected normal curvilinear patterns. No overt evidence of active inflammatory or neoplastic disease was noted.

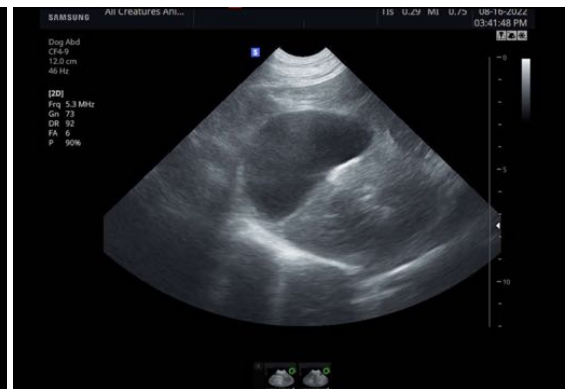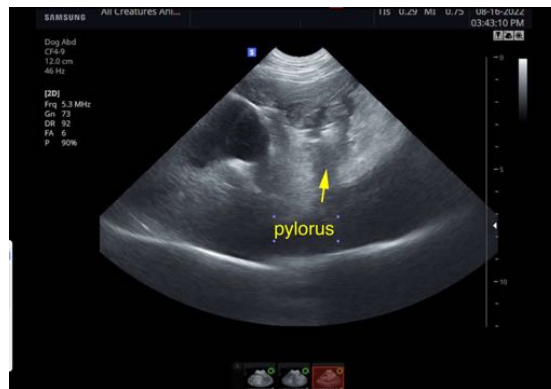
**ULTRASONOGRAPHIC FINDINGS**

Structurally unremarkable abdomen with slightly swollen cranial pole of the left adrenal gland.

Benign hepatopathy.

**INTERPRETATION OF THE FINDINGS & FURTHER RECOMMENDATIONS**

There was no evidence of significant pathology. Blood pressure measurements are warranted. FNA of the liver could be considered further definition. Leptospirosis titers are warranted to rule out subclinical disease.





**PATIENT**

Ellie Golden Bond  
Rescue

**SPECIES**

Canine

**BREED**

Golden Retriever

**SEX**

Spayed female

**AGE**

5 ½ years

**WEIGHT**

57 lbs

**INTERPRETED BY**

Eric Lindquist, DMV  
DABVP, Cert. IVUSS

**IMAGING  
PERFORMED BY**

Dr. Preston

**HOSPITAL NAME**

All Creatures AH South  
Hill

**REFERRING VET**

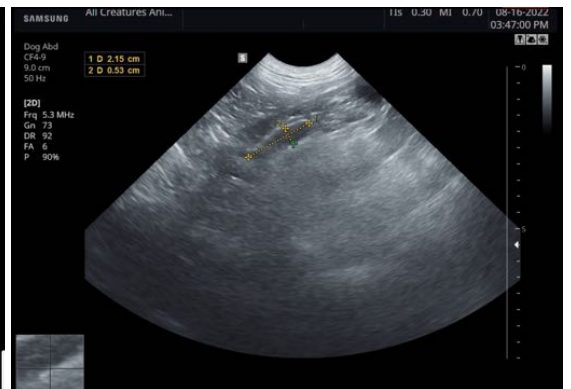
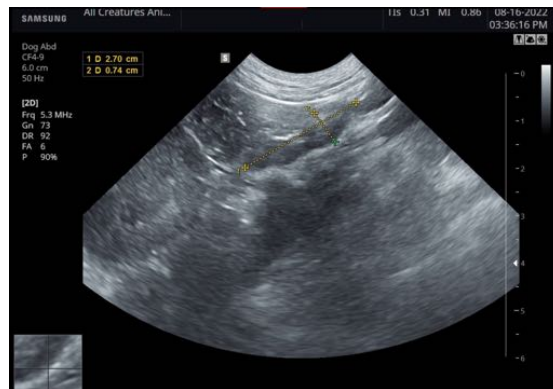
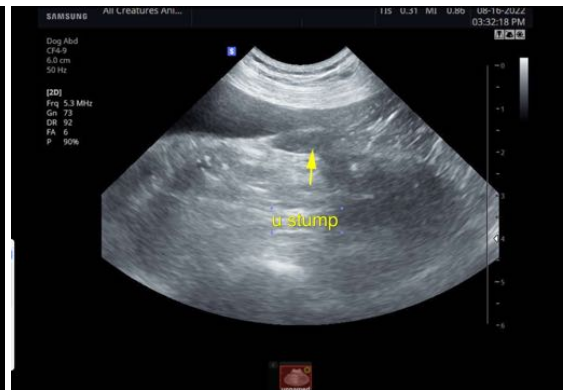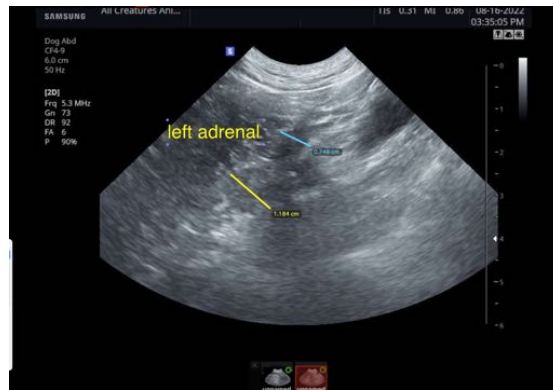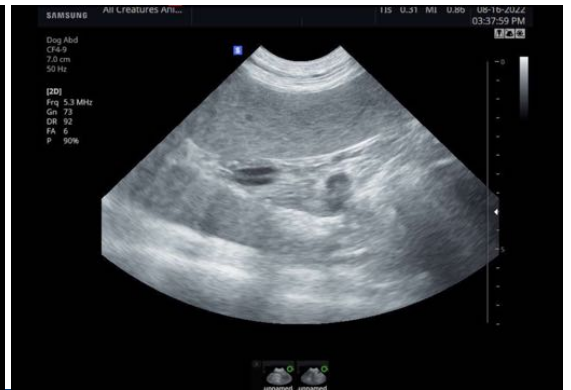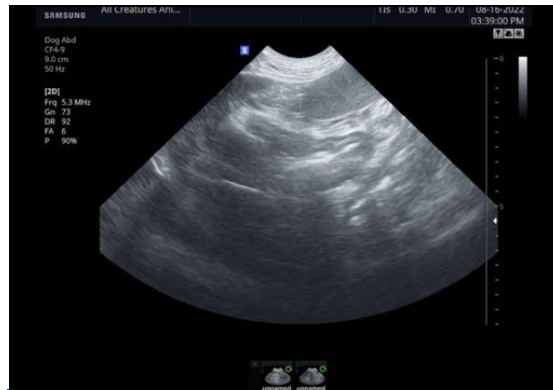Dr. Preston

**INVOICE**

32364

**DATE**

8/17/22



The information and recommendations provided are based on the images presented by the referring veterinarian/sonographer. No evaluation can be communicated regarding pathology that was not visible in the image/video clips provided.

Thank you for this referral. If the clinical or image interpretation does not parallel your findings or if I can be of any further assistance please contact me.

**Eric Lindquist, DMV, DABVP, Cert. IVUSS, CEO of SonoPath.com**  
info@SonoPath.com