

**DATE PRESENTING CLINICAL SIGNS**

8/16/21 History: Presenting for a several-week history of progressive lethargy, hyporexia, and weight loss. Previous history of right TPLO. Pale mucous membranes noted on exam with mild cranial abdominal organomegaly.

PATIENT

Lucy Brassler
Current Medications: Yunnan Baiyao 2 capsules PO q12hr, started 8/13
No other medications.

SPECIES

Canine

Lab Results: 8/13/2021: HCT 29%, retics 310,000, plts 64,00 with clumping, neuts 14.11, lymphs 7.63, monos 3.2, TP 5.9, alb 2.6, ALT 189, SDMA 16. 10/02/2020: HCT 56%, TP 6.0.

Radiographs: Not provided by the veterinarian.

Date of Previous IntraPet Ultrasound: No previous IntraPet scans.

Sedation: not needed

BREED

Stat Report: **STAT report is requested for this case.**

Bernese Mountain Dog

ULTRASONOGRAPHIC EXAMINATION OF THE ABDOMEN**SEX**

Spayed Female

Urinary System

The **urinary bladder**, trigone, and pelvic urethra presented normal thicknesses and normal tone. The ureters were not visible which is normal. No uroliths or sediment were visualized and anechoic urine was present. No evidence of inflammatory or neoplastic changes were noted. Ureteral papillae were normal.

AGE

2/8/15

The **kidneys** revealed normal size and structure, corticomedullary definition and ratio for this age. The cortices presented largely uniform texture with normal echogenic relationship to liver and spleen. Medullary structure differed distinctly from the cortex and no evidence of pelvic dilation was present. The capsules were acceptably uniform without significant irregularities. The kidneys measured 6.8 cm each.

WEIGHT

111 Pounds

Adrenal Glands

The **right adrenal gland** was visualized and recognized as having normal shape, size, position and echogenicity for this breed. The phrenic vasculature, glandular echogenicity and detail were unremarkable. Capsule, cortex, and medullary definition were normal for this age patient. The right adrenal gland measured 2.71 cm x 0.96 cm at the caudal pole and 0.85 cm at the cranial pole.

INTERPRETED BY

Eric Lindquist, DMV
DABVP, Cert. IVUSS

The **left adrenal gland** appeared slightly subnormal in size, measuring 3.05 cm x 0.6 cm at the caudal pole and 0.5 cm at the cranial pole.

HOSPITAL NAME

Eastern AH

Spleen

The **spleen** presented multifocal, hypoechoic nodules, which were ill-defined. A large splenic nodule measured 2.18 cm. Mild irregular contour noted.

REFERRING VET

Dr. Deininger

Liver

The **liver** revealed mild coarse architecture and slight increased portal markings. The gallbladder and common bile duct were unremarkable.

INVOICE

24709

Gastrointestinal

Examination of the **gastrointestinal tract** revealed a stomach and intestine free of stasis, of normal wall thickness, acceptable curvilinear mural detail, and peristaltic activity. Small and large intestine demonstrated normal luminal chyme and stool consistency respectively. No obstructive or overt infiltrative disease was noted. No associated abnormal lymphatic activity was noted.

Pancreas

The base and limbs of the **pancreas** were observed to be largely isoechoic to surrounding omental fat. Pancreatic duct and capsular contour were acceptably normal and parenchyma respected normal curvilinear patterns. No overt evidence of active inflammatory or neoplastic disease was noted.

Free Abdomen

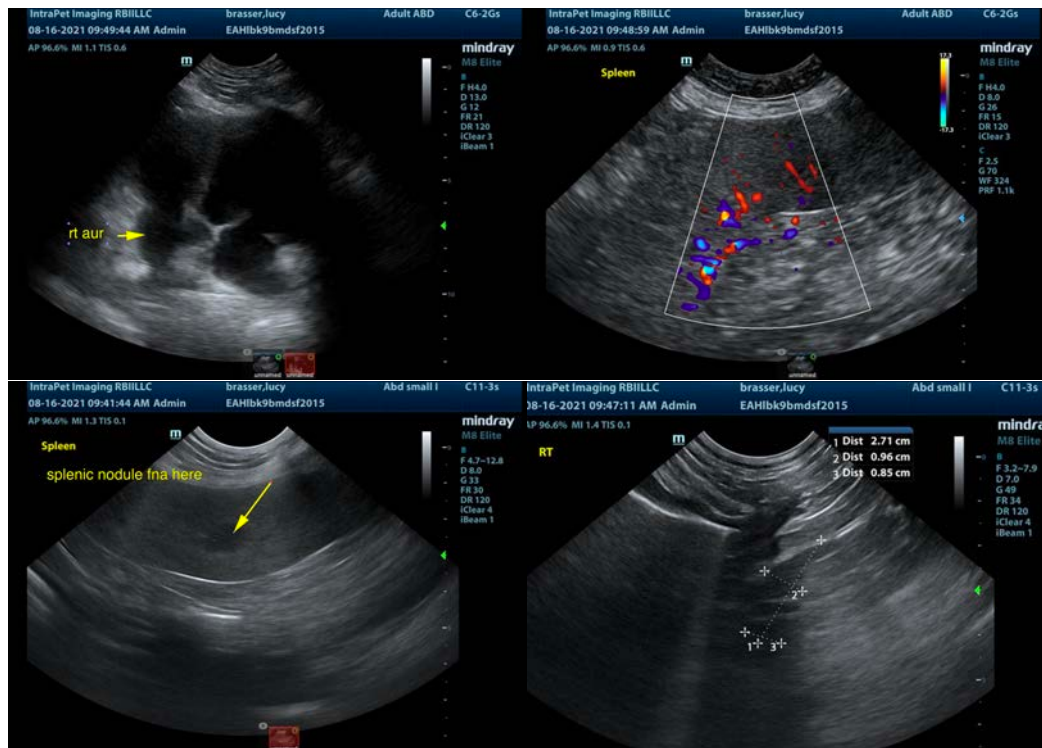
Rapid view of the heart (SDEP 3 position) revealed subjectively normal function without pathology in the right auricle or pericardium.

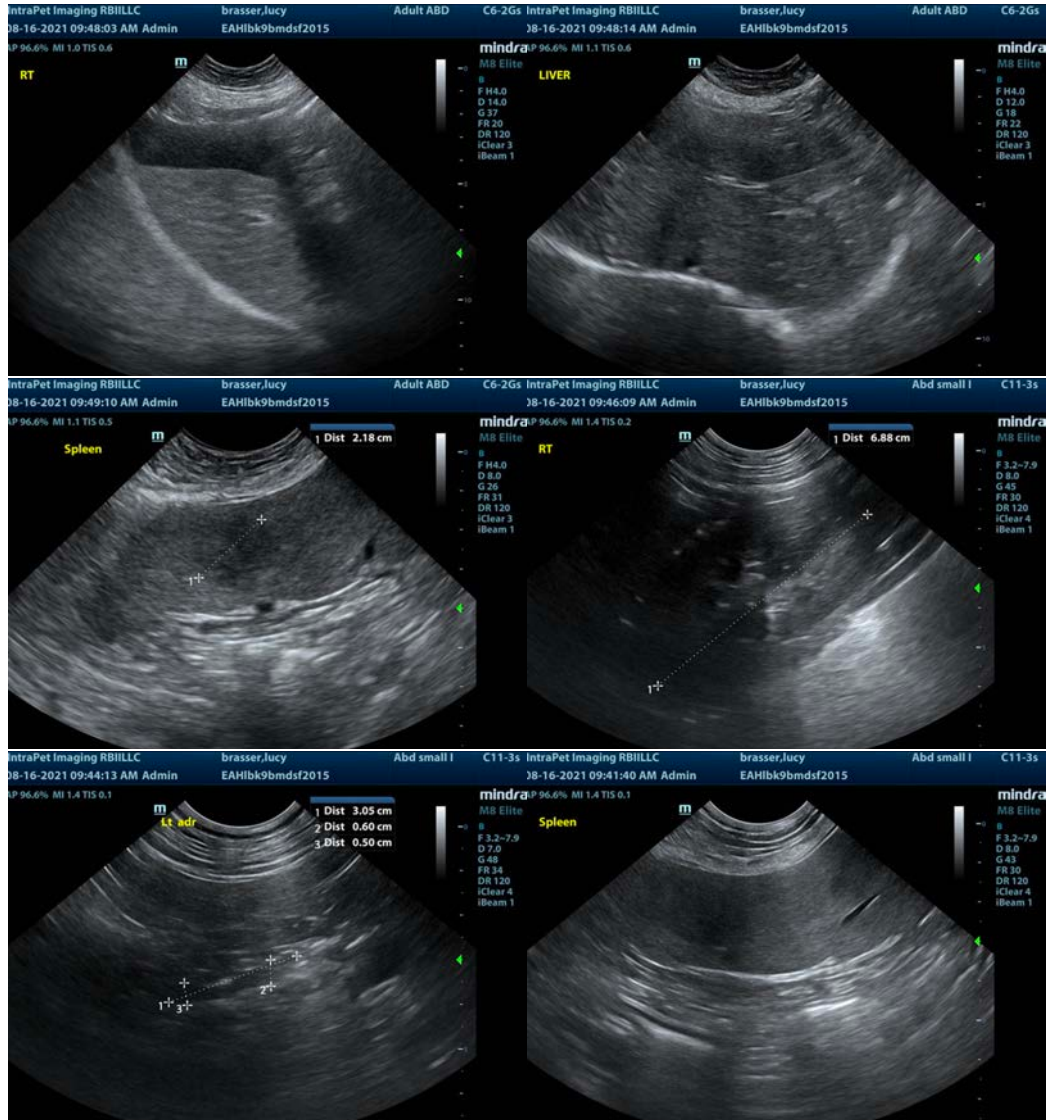
ULTRASONOGRAPHIC FINDINGS

- Irregular, nodular spleen
- Subnormal left adrenal size

INTERPRETATION OF THE FINDINGS & FURTHER RECOMMENDATIONS

No evidence of peritoneal effusion or overt masses. However, I am strongly concerned for an infiltrative process in the spleen, possibly involving the bone marrow. FNA of the spleen would be appropriate with potential need for bone marrow aspirates. Differentials include round cell neoplasia, emerging hemangiosarcoma, nodular hyperplasia. Other than the spleen, the remainder of the abdomen is largely expected for this age patient. Given the slightly subnormal albumin and unexplained anemia, screening for Addison's would also be appropriate with baseline cortisol or ACTH stimulation. 3-view chest radiographs warranted if not already performed.





The information and recommendations provided are based on the images presented by the referring veterinarian. No evaluation can be communicated regarding pathology that was not visible in the image/video clips provided.

Thank you for this referral. If the clinical or image interpretation does not parallel your findings or if I can be of any further assistance please contact me.

Eric Lindquist, DMV, DABVP, Cert. IVUSS, CEO of SonoPath.com
info@SonoPath.com