



PATIENT

Mischief Capner

SPECIES

Canine

BREED

American Eskimo Cross

SEX

Spayed female

AGE

3 years

WEIGHT

17.3 kg

INTERPRETED BY

Eric Lindquist, DMV
DABVP, Cert. IVUSS

IMAGING PERFORMED BY

Dr. Biederbeck

HOSPITAL NAME

Lomsnes VH

REFERRING VET

Dr. Biederbeck

INVOICE

46627

DATE

8/15/23

PRESENTING CLINICAL SIGNS

History: Shelter dog that was just adopted. July 11 was spayed and had severely cystic ovaries, repro tract sent for histo and interpretation is: Ovaries: - a. (bilateral) - Ovarian cysts, multifocal, marked, chronic - b. (bilateral) - Papillary hyperplasia of the subsurface endothelial structures - c. (unilateral) - Granulosa cell tumor Uterus: Endometrial hyperplasia with prominent vascularity -so is here today for met check for granulosa cell tumor -Thoracic rads taken today and normal
Abnormal PE/Chem/CBC/UA Results: Thin bcs but shelter dog, otherwise normal on exam

ULTRASONOGRAPHIC EXAMINATION OF THE ABDOMEN

Urinary System

The **urinary bladder**, trigone, and pelvic urethra presented normal thicknesses and normal tone. The ureters were not visible which is normal. No uroliths or sediment were visualized and anechoic urine was present. No evidence of inflammatory or neoplastic changes was noted. Ureteral papillae were normal.

The **kidneys** revealed normal size and structure, corticomedullary definition and ratio for this age. The cortices presented largely uniform texture with normal echogenic relationship to liver and spleen. Medullary structure differed distinctly from the cortex and no evidence of pelvic dilation was present. The capsules were acceptably uniform without significant irregularities. The left kidney measured 5.6 cm.

Adrenal Glands

Both **adrenal glands** were visualized and recognized as having normal shape, size, position and echogenicity for this breed. The phrenic vasculature, glandular echogenicity and detail were unremarkable. Capsule, cortex, and medullary definition were normal for this age patient. The left adrenal gland measured 0.63 cm at the cranial pole and 0.68 cm at the caudal pole. The right adrenal gland measured 0.82 cm at the cranial pole and 0.6 cm at the caudal pole.

Spleen

The **spleen** in this patient was mildly enlarged with uniform parenchyma and was folded upon itself caudally. This is a positional variant and is not pathological. There was no evidence of significant disease.

Liver

The **liver** images submitted revealed subjectively normal liver size, contour, and structure. Parenchymal echogenicity was naturally coarse and hypoechoic to the spleen. Vascular and biliary tracts were of normal volume with no evidence of congestion. The gallbladder presented acceptably thin walls with primarily anechoic content. The cystic and common bile ducts were normal. No pathological hepatic lymphadenopathy was evident. No overt structural evidence of inflammatory, infiltrative or regenerative pathology was evident.



PATIENT

Mischief Capner

SPECIES

Canine

BREED

American Eskimo Cross

SEX

Spayed female

AGE

3 years

WEIGHT

17.3 kg

INTERPRETED BY

Eric Lindquist, DMV
DABVP, Cert. IVUS

IMAGING PERFORMED BY

Dr. Biederbeck

HOSPITAL NAME

Lomsnes VH

REFERRING VET

Dr. Biederbeck

INVOICE

46627

DATE

8/15/23

Gastrointestinal

Examination of the **gastrointestinal tract** revealed a stomach and intestine free of stasis, of normal wall thickness, acceptable curvilinear mural detail, and peristaltic activity. Small and large intestine demonstrated normal luminal chyme and stool consistency respectively. No obstructive or overt infiltrative disease was noted. No associated abnormal lymphatic activity was noted.

Pancreas

The base and limbs of the **pancreas** were observed to be largely isoechoic to surrounding omental fat. Pancreatic duct and capsular contour were acceptably normal and parenchyma respected normal curvilinear patterns. No overt evidence of active inflammatory or neoplastic disease was noted.

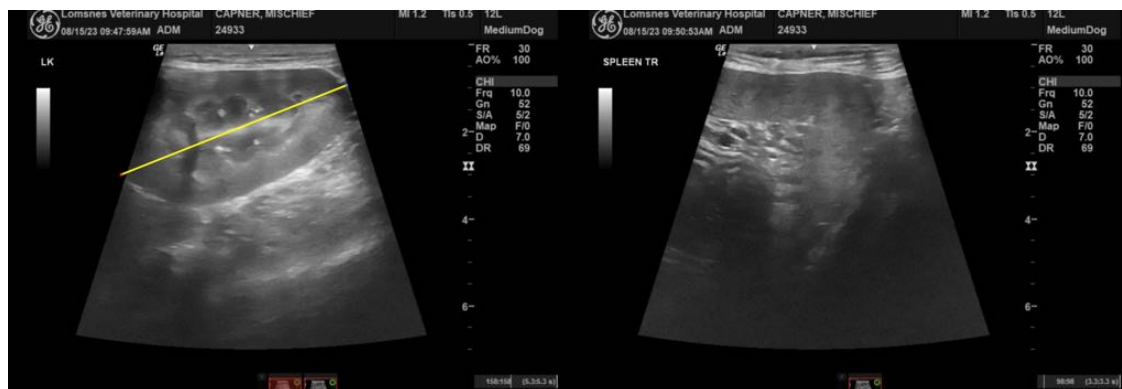
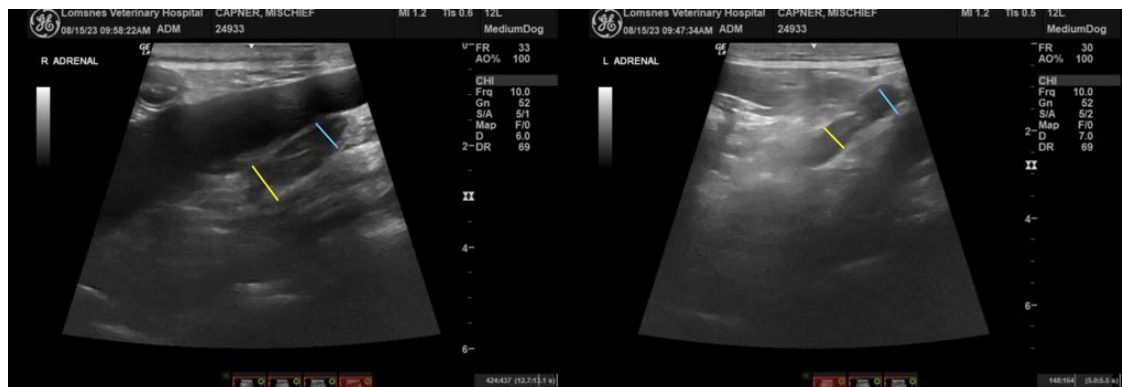
ULTRASONOGRAPHIC FINDINGS

Structurally unremarkable abdomen.

Folded spleen.

INTERPRETATION OF THE FINDINGS & FURTHER RECOMMENDATIONS

There was no evidence of reproductive or other pathology.





PATIENT

Mischief Capner

SPECIES

Canine

BREED

American Eskimo Cross

SEX

Spayed female

AGE

3 years

WEIGHT

17.3 kg

INTERPRETED BY

Eric Lindquist, DMV
DABVP, Cert. IVUSS

IMAGING PERFORMED BY

Dr. Biederbeck

HOSPITAL NAME

Lomsnes VH

REFERRING VET

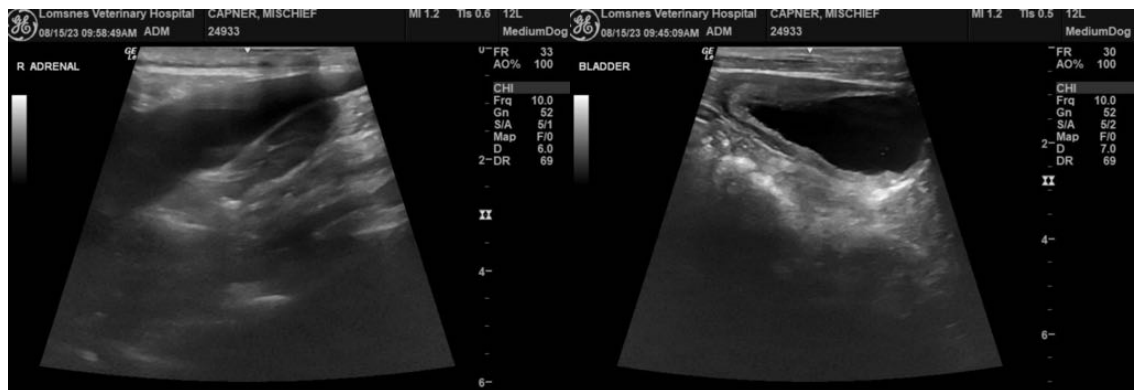
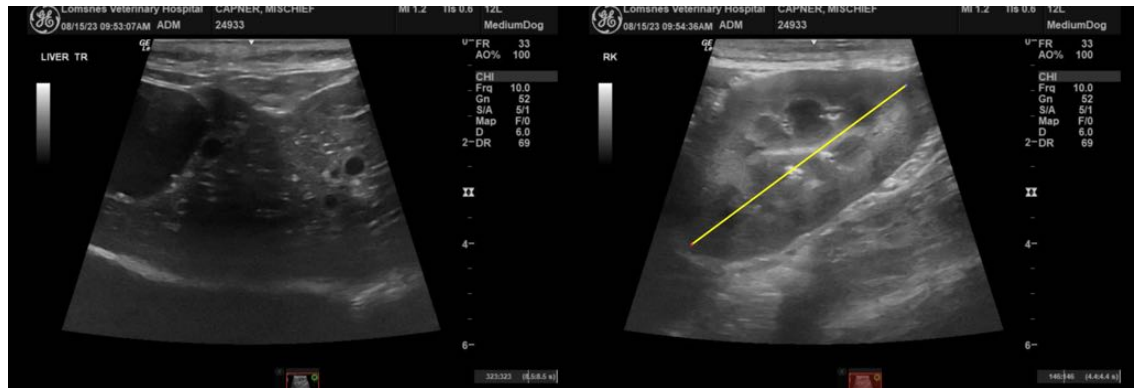
Dr. Biederbeck

INVOICE

46627

DATE

8/15/23



The information and recommendations provided are based on the images presented by the referring veterinarian/sonographer. No evaluation can be communicated regarding pathology that was not visible in the image/video clips provided.

Thank you for this referral. If the clinical or image interpretation does not parallel your findings or if I can be of any further assistance please contact me.

Eric Lindquist, DMV, DABVP, Cert. IVUSS, CEO of SonoPath.com
info@SonoPath.com