



**PATIENT** **PRESENTING CLINICAL SIGNS**

Georgia Gay

History: Presented yesterday for a couple days duration of hematuria and straining to urinate. Hematuria and dribbling of urine while sleeping. Malodorous perivulvar area with a moderate amount of moist debris

**SPECIES**

Mild elevation of TP and globulin Urinalysis results pending Lateral abdominal radiograph; bladder completely full of large stones

Canine

**BREED**

Labrador

**ULTRASONOGRAPHIC EXAMINATION OF THE ABDOMEN**

**Urinary System**

The **urinary bladder** wall was mildly thickened. The ureters were not visible which is normal. Multiple calculi were noted and measured up to 2.8 cm in length.

**SEX**

Spayed female

The **kidneys** revealed largely normal size and structure, corticomedullary definition and ratio (cortex 1/3 of medulla) were essentially maintained with some age-related loss of curvilinear patterns regarding the capsule and C/M junction. The cortices presented largely uniform texture with some increased echogenicity expected for his age patient. Medullary structure differed distinctly from that of the cortex and no evidence of pelvic dilation was present. The left kidney measured 6.7 cm. The right kidney measured 7.17 cm.

**AGE**

9 years

**WEIGHT**

71 lbs

**Adrenal Glands**

The left **adrenal gland** was visualized and recognized as having normal shape, size, position and echogenicity for this breed. The phrenic vasculature, glandular echogenicity and detail were unremarkable. Capsule, cortex, and medullary definition were normal for this age patient. The left adrenal gland measured 0.5 cm. The region of the right adrenal gland was imaged with no evidence of pathology.

**INTERPRETED BY**

Eric Lindquist, DMV  
DABVP, Cert. IVUSS

**IMAGING PERFORMED BY**

Carter

**Spleen**

The **spleen** in this patient was mildly enlarged with uniform parenchyma and was folded upon itself cranially. This is a positional variant and is not pathological. There was no evidence of significant disease.

**HOSPITAL NAME**

Willamette VH

**Liver**

The **liver** images from right and left intercostal as well as subcostal views revealed subjectively normal liver size, contour, and structure. Some age-related parenchymal remodeling was noted but likely not clinically significant at this time. Vascular and biliary tracts were of normal volume and no evidence of congestion was noted. Coalesced gallbladder sludge was noted.

**REFERRING VET**

Dr. Porter

**INVOICE**

46608

**Gastrointestinal**

There was some residual chyme and gas was noted in the **stomach**, yet not pathological. This is consistent with end post prandial presentation. Transit of chyme into the small intestine was normal. Curvilinear patterns were maintained throughout the GI tract. No evidence of pathology. Small and

**DATE**

8/15/23



**PATIENT**

Georgia Gay

large intestine demonstrated normal luminal chyme and stool consistency respectively. No obstructive or overt infiltrative disease was noted. No associated abnormal lymphatic activity was noted.

**SPECIES**

Canine

**Pancreas**

The base and limbs of the **pancreas** were observed to be largely isoechoic to surrounding omental fat. Pancreatic duct and capsular contour were acceptably normal and parenchyma respected normal curvilinear patterns. No overt evidence of active inflammatory or neoplastic disease was noted.

**BREED**

Labrador

**ULTRASONOGRAPHIC FINDINGS**

Large amount of bladder calculi.

**SEX**

Spayed female

**INTERPRETATION OF THE FINDINGS & FURTHER RECOMMENDATIONS**

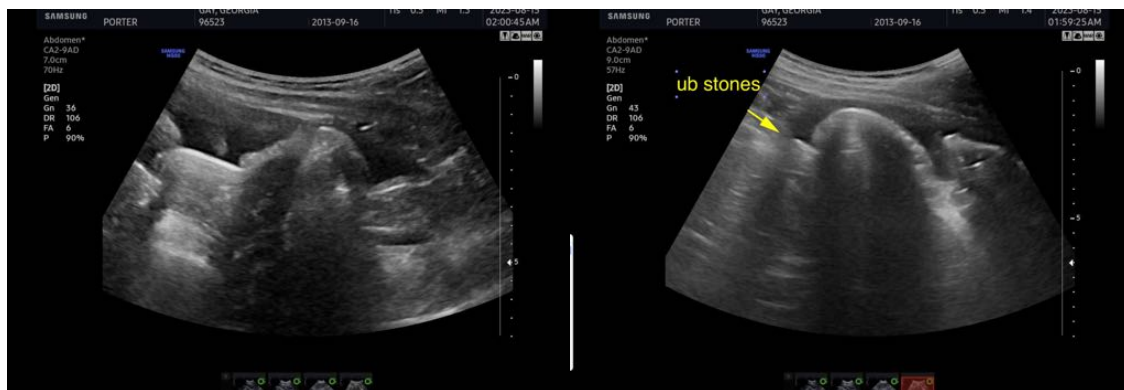**AGE**

9 years

Cystotomy, stone analysis and culture are all indicated. The bladder calculi were non-obstructive at the time of the sonogram. However, it is certainly irritative.

**WEIGHT**

71 lbs

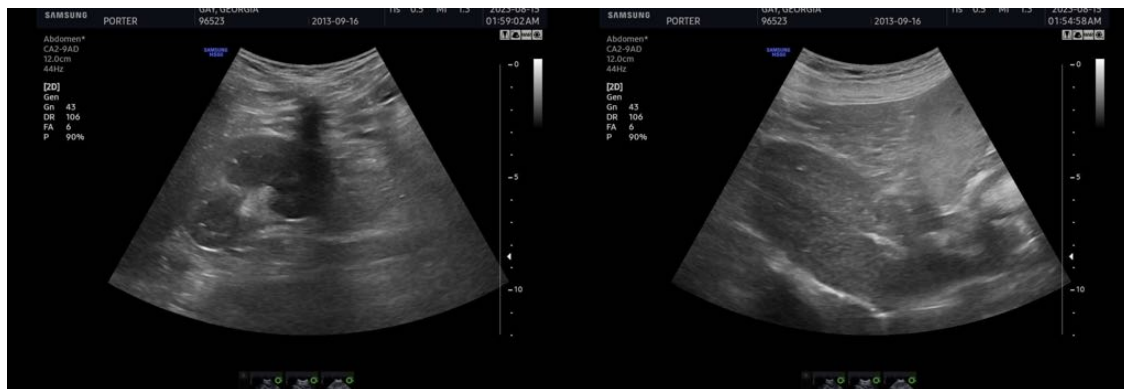

**INTERPRETED BY**

Eric Lindquist, DMV  
DABVP, Cert. IVUSS

**IMAGING PERFORMED BY**

Carter



**HOSPITAL NAME**

Willamette VH

**REFERRING VET**

Dr. Porter

**INVOICE**

46608

**DATE**

8/15/23



**PATIENT**

Georgia Gay

**SPECIES**

Canine

**BREED**

Labrador

**SEX**

Spayed female

**AGE**

9 years

**WEIGHT**

71 lbs

**INTERPRETED BY**

Eric Lindquist, DMV  
DABVP, Cert. IVUSS

**IMAGING PERFORMED BY**

Carter

**HOSPITAL NAME**

Willamette VH

**REFERRING VET**

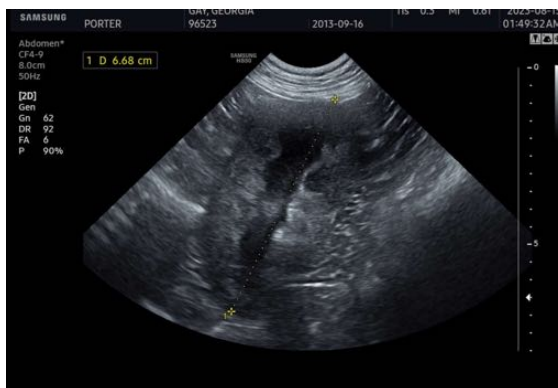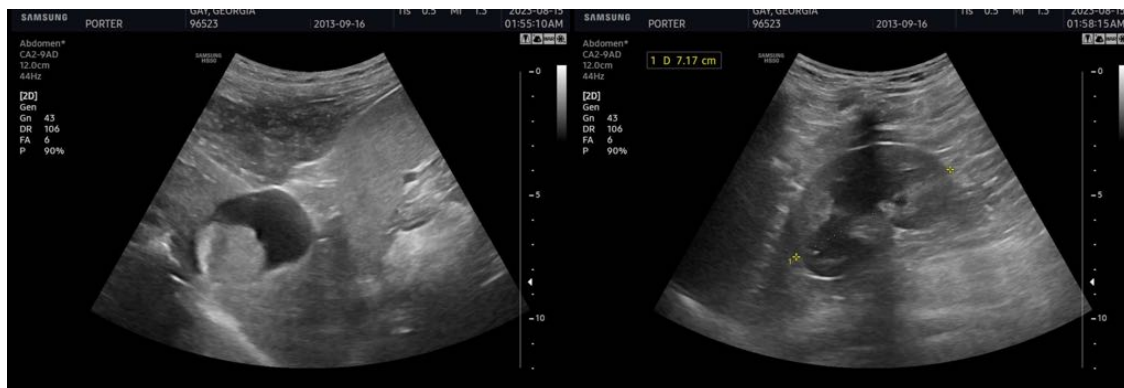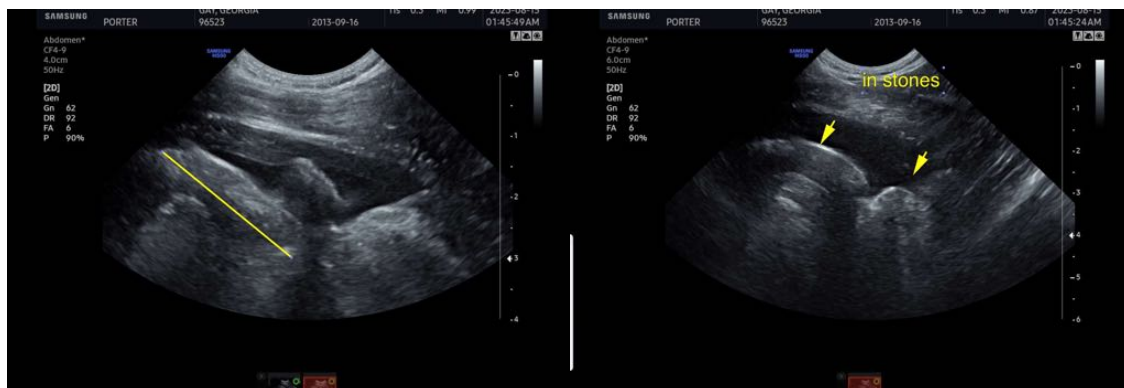
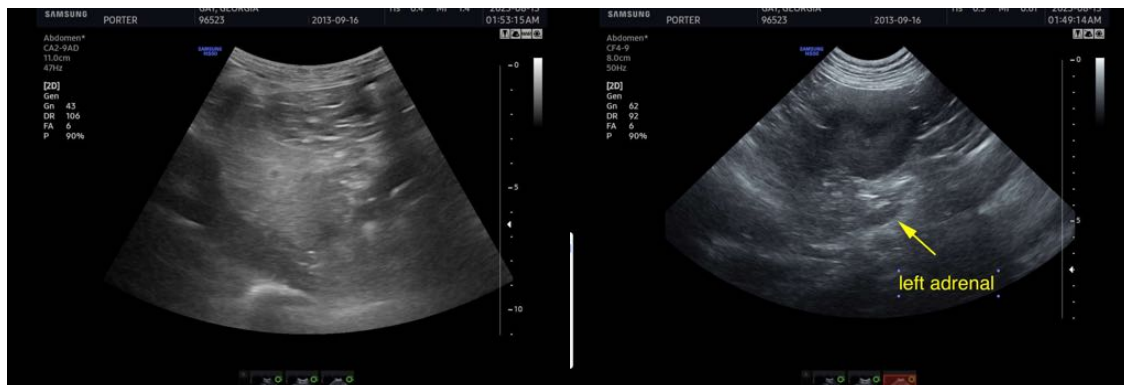Dr. Porter

**INVOICE**

46608

**DATE**

8/15/23





**PATIENT**

Georgia Gay

The information and recommendations provided are based on the images presented by the referring veterinarian/sonographer. No evaluation can be communicated regarding pathology that was not visible in the image/video clips provided.

**SPECIES**

Canine

Thank you for this referral. If the clinical or image interpretation does not parallel your findings or if I can be of any further assistance please contact me.

**BREED**

Labrador

**Eric Lindquist**, DMV, DABVP, Cert. IVUSS, CEO of SonoPath.com  
info@SonoPath.com

**SEX**

Spayed female

**AGE**

9 years

**WEIGHT**

71 lbs

**INTERPRETED BY**

Eric Lindquist, DMV  
DABVP, Cert. IVUSS

**IMAGING  
PERFORMED BY**

Carter

**HOSPITAL NAME**

Willamette VH

**REFERRING VET**

Dr. Porter

**INVOICE**

46608

**DATE**

8/15/23