



PATIENT

Stevie Kearns

PRESENTING CLINICAL SIGNS

Bladder stone seen on xray. Access to see if surgery needed
Abnormal PE/Chem/CBC/UA Results: Frequent urination. UA Protein 3 + , struvite crystals 4-10

SPECIES

Feline

ULTRASONOGRAPHIC EXAMINATION OF THE ABDOMEN

Urinary System

BREED

DSH

The **urinary bladder** revealed a 5.0 mm calculus with excessive bladder thickening and a minor amount of urine present. Bladder thickness measured 0.45 cm. Mild interstitial cystitis pattern. The pelvic urethra was imaged 3.0 cm beyond the cystourethral junction.

SEX

Neutered Male

The **kidneys** revealed normal size and structure, corticomedullary definition and ratio for this age. The cortices presented largely uniform texture with normal echogenic relationship to liver and spleen. Medullary structure differed distinctly from the cortex and no evidence of pelvic dilation was present. The capsules were acceptably uniform without significant irregularities. The right kidney measured 4.22 cm. The left kidney measured 3.92 cm.

AGE

3 Years

Adrenal Glands

The regions of the **adrenal glands** were unremarkable.

WEIGHT

15.5 Pounds

Spleen

The **spleen** presented a smooth homogeneous parenchyma hyperechoic to liver and renal cortical parenchyma. The capsule was smooth without noticeable expansion or deviation from within the spleen or adjacent pathology. The splenic vasculature demonstrated normal volume without signs of congestion or thrombosis. No sonographic evidence of acute or chronic inflammatory, neoplastic, or infarctual changes were noted.

INTERPRETED BY

Eric Lindquist, DMV

Liver

DABVP, Cert. IVUSS

The **liver** images submitted revealed subjectively normal liver size, contour, and structure. Parenchymal echogenicity was naturally coarse and hypoechoic to the spleen. Vascular and biliary tracts were of normal volume with no evidence of congestion. The gallbladder presented acceptably thin walls with primarily anechoic content. The cystic and common bile ducts were normal. No pathological hepatic lymphadenopathy was evident. No overt structural evidence of inflammatory, infiltrative or regenerative pathology was evident.

IMAGING PERFORMED BY

JK

HOSPITAL NAME

Hamburg Vet Clinic

Gastrointestinal

Examination of the **gastrointestinal tract** revealed a stomach and intestine free of stasis, of normal wall thickness, acceptable curvilinear mural detail, and peristaltic activity. Small and large intestine demonstrated normal luminal chyme and stool consistency respectively. No obstructive or overt infiltrative disease was noted. No associated abnormal lymphatic activity was noted.

REFERRING VET

Dr. Martens

Pancreas

INVOICE

40447

The base and limbs of the **pancreas** were observed to be largely isoechoic to surrounding omental fat. Pancreatic duct and capsular contour were acceptably normal and parenchyma respected normal curvilinear patterns. No overt evidence of active inflammatory or neoplastic disease was noted.

ULTRASONOGRAPHIC FINDINGS

DATE

8/15/22

- Bladder calculus and mild bladder thickening – interstitial cystitis suspected.



PATIENT

Stevie Kearns

INTERPRETATION OF THE FINDINGS & FURTHER RECOMMENDATIONS

Cystotomy, stone analysis and bladder wall biopsy warranted to rule out underlying disease that may be predisposing to calculus formation.

SPECIES

Feline

BREED

DSH

SEX

Neutered Male

AGE

3 Years

WEIGHT

15.5 Pounds

INTERPRETED BY

Eric Lindquist, DMV
DABVP, Cert. IVUSS

IMAGING PERFORMED BY

JK

HOSPITAL NAME

Hamburg Vet Clinic

REFERRING VET

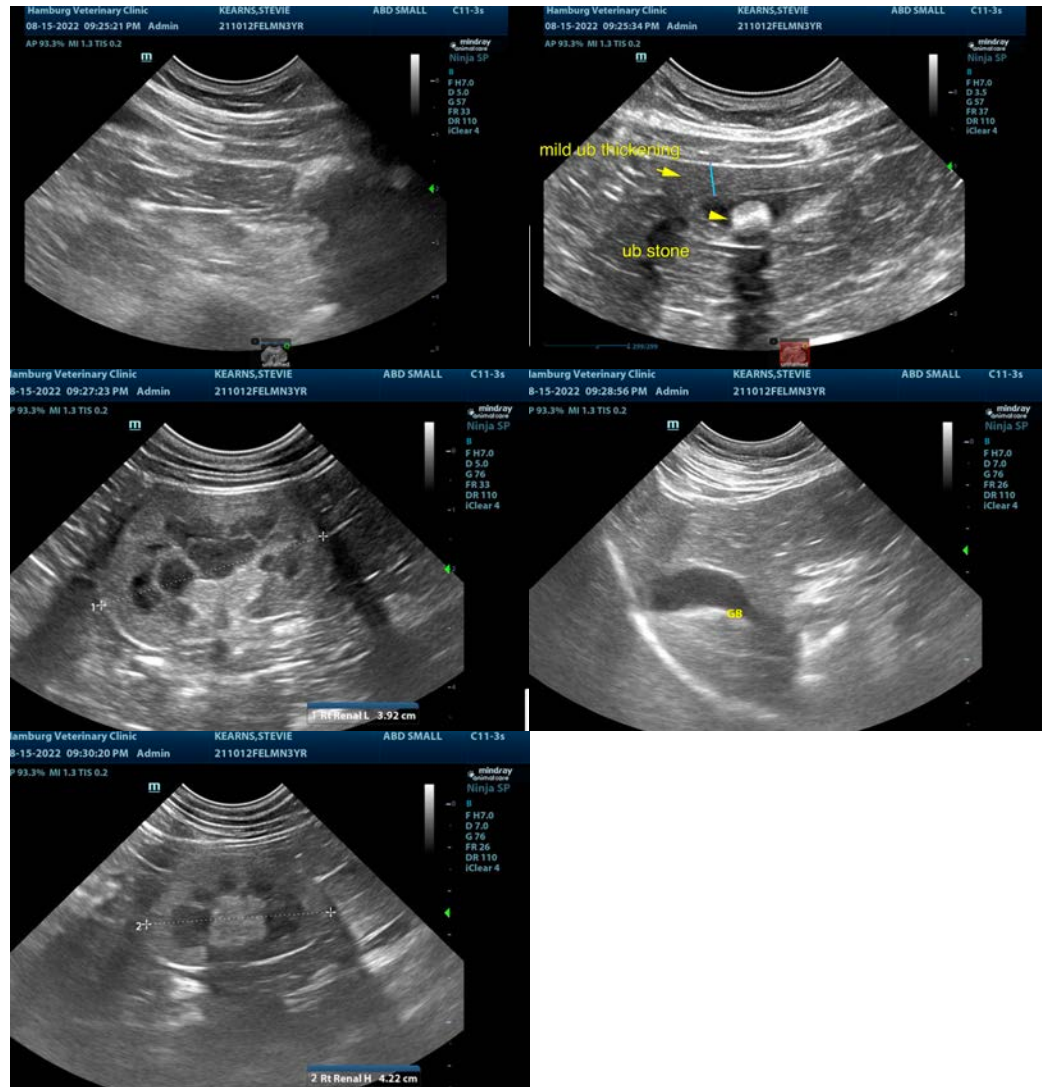
Dr. Martens

INVOICE

40447

DATE

8/15/22



The information and recommendations provided are based on the images presented by the referring veterinarian/sonographer. No evaluation can be communicated regarding pathology that was not visible in the image/video clips provided.

Thank you for this referral. If the clinical or image interpretation does not parallel your findings or if I can be of any further assistance please contact me.

Eric Lindquist, DMV, DABVP, Cert. IVUSS, CEO of SonoPath.com

info@SonoPath.com