



**PATIENT PRESENTING CLINICAL SIGNS**

James Kjergard elevated GGT, V/D

**SPECIES ULTRASONOGRAPHIC EXAMINATION OF THE ABDOMEN**

Feline **Urinary System**

The **urinary bladder** revealed suspended coalesced debris, non-shadowing.

**BREED** The **kidneys** revealed normal size and structure, corticomedullary definition and ratio for this age. The cortices presented largely uniform texture with normal echogenic relationship to liver and spleen. Medullary structure differed distinctly from the cortex and no evidence of pelvic dilation was present. The capsules were acceptably uniform without significant irregularities. The right kidney measured 5.02 cm. The left kidney measured 4.57 cm.

**SEX** Neutered Male **Adrenal Glands**

**AGE** Both **adrenal glands** were visualized and recognized as having normal shape, size, position and echogenicity for this breed. The phrenic vasculature, glandular echogenicity and detail were unremarkable. Capsule, cortex, and medullary definition were normal for this age patient. The left adrenal gland measured 0.53 cm. The right adrenal gland measured 0.52 cm.

**WEIGHT** 14.8 Pounds **Spleen**  
The **spleen** presented a smooth homogeneous parenchyma hyperechoic to liver and renal cortical parenchyma. The capsule was smooth without noticeable expansion or deviation from within the spleen or adjacent pathology. The splenic vasculature demonstrated normal volume without signs of congestion or thrombosis. No sonographic evidence of acute or chronic inflammatory, neoplastic, or infarctual changes were noted.

**INTERPRETED BY** Eric Lindquist, DMV  
DABVP, Cert. IVUSS **Liver**

The **liver** images submitted revealed subjectively normal liver size, contour, and structure. Parenchymal echogenicity was naturally coarse and hypoechoic to the spleen. Vascular and biliary tracts were of normal volume with no evidence of congestion. The gallbladder presented acceptably thin walls with primarily anechoic content. The cystic and common bile ducts were normal. No pathological hepatic lymphadenopathy was evident. No overt structural evidence of inflammatory, infiltrative or regenerative pathology was evident.

**IMAGING PERFORMED BY** Diane McFadden **Gastrointestinal**

The **gastric** fundus was slightly thickened with empty lumen. Minor amount of fluid filled pyloric lumen. The distal small intestine revealed minor thickening with reactive surrounding mesentery, consistent with enteritis.

**HOSPITAL NAME** Rockaway AH **Pancreas**

The base and limbs of the **pancreas** were observed to be largely isoechoic to surrounding omental fat. Pancreatic duct and capsular contour were acceptably normal and parenchyma respected normal curvilinear patterns. No overt evidence of active inflammatory or neoplastic disease was noted.

**REFERRING VET** Dr. Maniar **INVOICE** 40437 **ULTRASONOGRAPHIC FINDINGS**

**DATE** 8/15/22 • Mild gastroenteritis pattern, unremarkable abdomen otherwise



**PATIENT**

James Kjergard

**INTERPRETATION OF THE FINDINGS & FURTHER RECOMMENDATIONS**

Supportive care should prove effective.

**SPECIES**

Feline

**BREED**

DSH

**SEX**

Neutered Male

**AGE**

8 Years

**WEIGHT**

14.8 Pounds

**INTERPRETED BY**

Eric Lindquist, DMV  
DABVP, Cert. IVUSS

**IMAGING PERFORMED BY**

Diane McFadden

**HOSPITAL NAME**

Rockaway AH

**REFERRING VET**

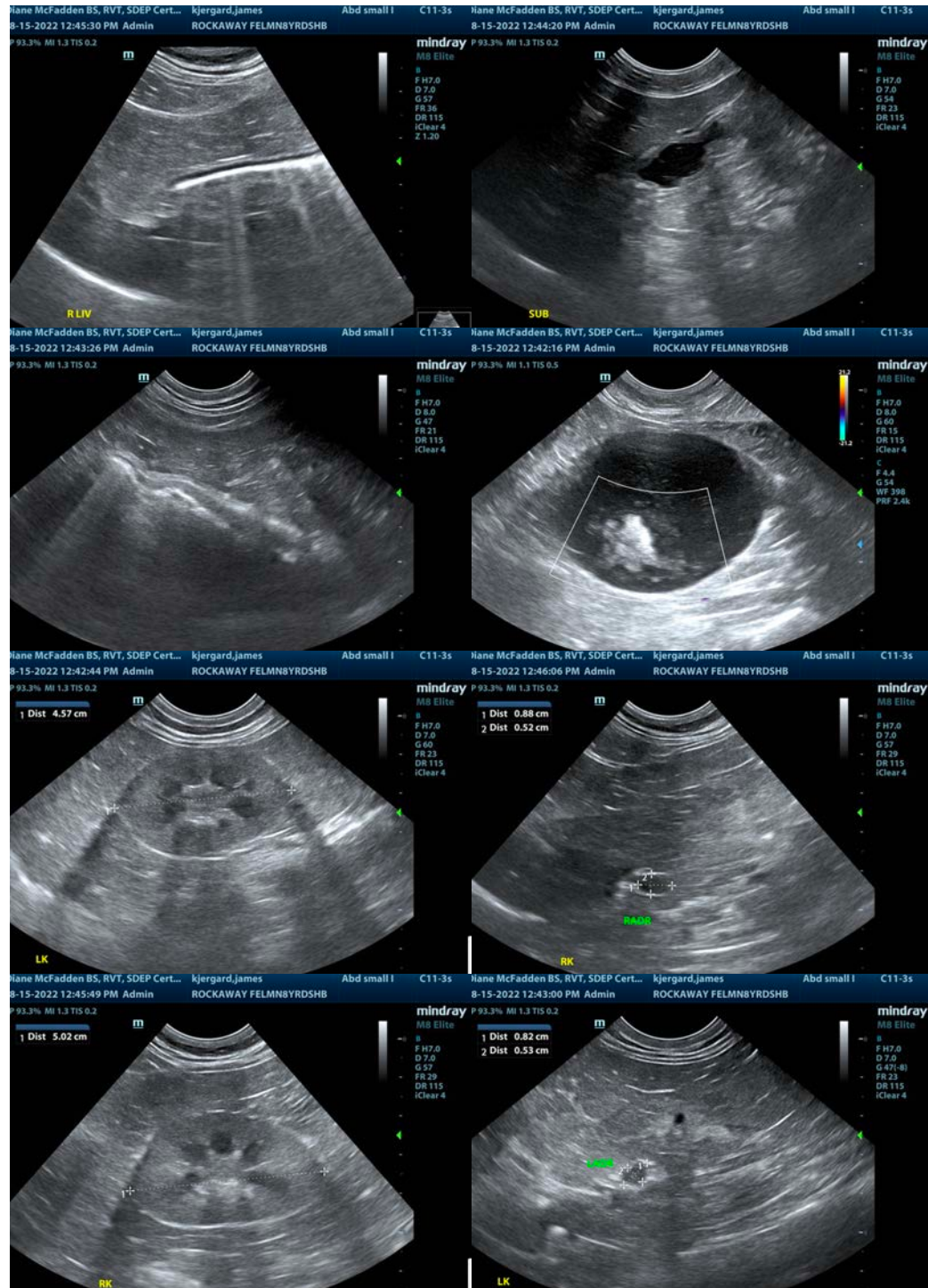
Dr. Maniar

**INVOICE**

40437

**DATE**

8/15/22





**PATIENT**

James Kjergard

The information and recommendations provided are based on the images presented by the referring veterinarian/sonographer. No evaluation can be communicated regarding pathology that was not visible in the image/video clips provided.

**SPECIES**

Feline

Thank you for this referral. If the clinical or image interpretation does not parallel your findings or if I can be of any further assistance please contact me.

**BREED**

DSH

Eric Lindquist, DMV, DABVP, Cert. IVUSS, CEO of SonoPath.com

[info@SonoPath.com](mailto:info@SonoPath.com)

**SEX**

Neutered Male

**AGE**

8 Years

**WEIGHT**

14.8 Pounds

**INTERPRETED BY**

Eric Lindquist, DMV

DABVP, Cert. IVUSS

**IMAGING PERFORMED BY**

Diane McFadden

**HOSPITAL NAME**

Rockaway AH

**REFERRING VET**

Dr. Maniar

**INVOICE**

40437

**DATE**

8/15/22