



PATIENT

Atlas Regan

PRESENTING CLINICAL SIGNS

follow-up u/s of the spleen only for Inv/case # 99197 Currently on Ursodiol and Zentonil
Abnormal PE/Chem/CBC/UA Results: Chemistry - WNL

SPECIES

Canine

LIMITED ULTRASONOGRAPHIC EXAMINATION

The **spleen** presented similar mild heterogeneous parenchymal pattern to that noted on the prior sonogram. Minor uniform enlarged. Capsular and vascular integrity present.

BREED

Husky X

ULTRASONOGRAPHIC FINDINGS

- Micronodular hyperplasia splenic pattern with mild enlargement

SEX

Neutered Male

INTERPRETATION OF THE FINDINGS & FURTHER RECOMMENDATIONS

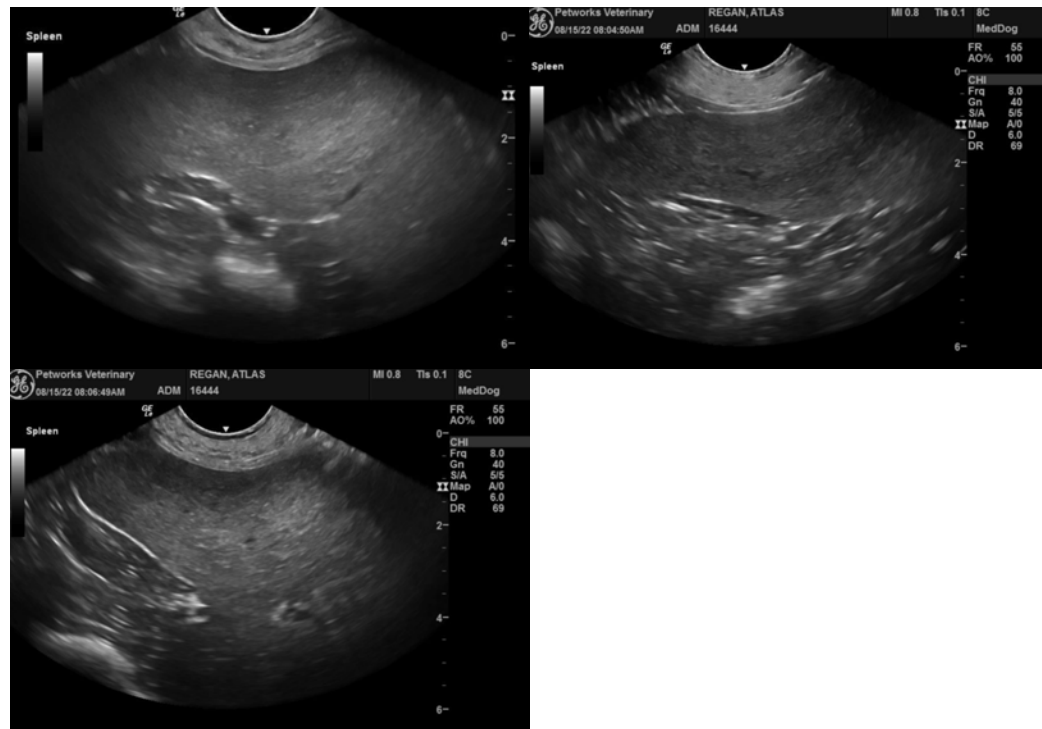
Likely benign. However, if any weight loss is an issue, ultrasound guided FNA would be warranted. No obvious evidence of neoplasia.

AGE

2.5 Years

WEIGHT

32.5 kg



INTERPRETED BY

Eric Lindquist, DMV

DABVP, Cert. IVUSS

IMAGING PERFORMED BY

Dr. Trudeau

HOSPITAL NAME

Petworks VH

REFERRING VET

Dr. Trudeau

The information and recommendations provided are based on the images presented by the referring veterinarian/sonographer. No evaluation can be communicated regarding pathology that was not visible in the image/video clips provided.

INVOICE

40427

Thank you for this referral. If the clinical or image interpretation does not parallel your findings or if I can be of any further assistance please contact me.

Eric Lindquist, DMV, DABVP, Cert. IVUSS, CEO of SonoPath.com

DATE

8/15/22

info@SonoPath.com