


**PATIENT**

Lucy Pantano

**PRESENTING CLINICAL SIGNS**

 Lucy has had a heart murmur for about a year. She has no clinical signs of heart disease.  
 Abnormal PE/Chem/CBC/UA Results: None

**SPECIES**

Canine

**ULTRASONOGRAPHIC EXAMINATION OF THE HEART**
**BREED**

Malte Poo

**SEX**

Spayed Female

**AGE**

3 Years

**WEIGHT**

11.12 Pounds

CANINE CARDIAC PARAMETERS	MR VMAX (m/s)	TR VMAX (m/s)	LA/AO (Boon method)	LA/AO (Heart Base; Swe)	FS (%)	EF (%)	EPSS (cm)
NORMAL PARAMETER	4.5-5.5	<2.7	1.3	<1.6	28-40	40-100	<0.6
PATIENT			1.2	1.06	44	79	0.12
CANINE CARDIAC PARAMETERS	HR (BPM)	AV VMAX (m/s)	PV MAX (m/s)	BODY WEIGHT (kg)	LA 2D short axis Base view (cm)	LVIDd Avg; 2D and m-mode short axis (cm)	LVIDs Avg; 2D and m-mode short axis (cm)
NORMAL PARAMETER	50-100	0.7-1.7	0.7-1.6				
PATIENT	79	--	--		2.0	1.7	

**Cardiac Presentation**

The echocardiogram in this patient demonstrated normal **left atrial** size based on 3 separate methods of LA evaluation. The cranial and caudal **mitral** valve leaflets presented normal linear structure, extension in systole, and union in diastole with normal kinesis. The **left ventricle** presented thicknesses with linear contour and was not dilated nor restricted. The **myocardium** presented normal echogenicity without subjective evidence of significant fibrotic or ischemic disease. **Contractility** of the ventricular walls was adequate and in normal range for this patient evidenced by the fractional shortening measurement and subjective evaluation of the different regions of the myocardium. The **left ventricular outflow** tract demonstrated normal laminar flow and subjective structural integrity. The **right atrium** and auricle revealed normal size, structure and content. No evidence of masses was noted. **Tricuspid** valvular assessment demonstrated adequate linear morphology and kinesis. The **right ventricle** was of normal size (1/3 diameter of LV), chordae structure, myocardial echogenicity and thickness. **Pulmonary outflow** tract assessment revealed normal valve structure, laminar flow, and diameter (approx. 1:1 pa/ao ratio). No visible **pericardial** or free pleura fluid was noted. The cranial **mediastinum and pericardial and extra-cardiac regions** were free of masses in the visible window.

**INTERPRETED BY**

 Eric Lindquist, DMV  
 DABVP, Cert. IVUSS

**IMAGING PERFORMED BY**

Dr. John A. Boley

**HOSPITAL NAME**

AH of Colorado Springs

**REFERRING VET**

Dr. John A. Boley

**ULTRASONOGRAPHIC FINDINGS**

- Normal echocardiogram

**INVOICE**

24705

**DATE**

8/15/21

**INTERPRETATION OF THE FINDINGS & FURTHER RECOMMENDATIONS**

The exact source of the murmur is unclear. Further doppler evaluation necessary to identify the murmur. It may be flow murmur owing to volume shifts. However, there is no evidence of structural or functional disease at this time. No contraindication to anesthetic procedure if necessary.



**PATIENT**

Lucy Pantano

**SPECIES**

Canine

**BREED**

Malte Poo

**SEX**

Spayed Female

**AGE**

3 Years

**WEIGHT**

11.12 Pounds

**INTERPRETED BY**

Eric Lindquist, DMV  
DABVP, Cert. IVUSS

**IMAGING PERFORMED BY**

Dr. John A. Boley

**HOSPITAL NAME**

AH of Colorado Springs

**REFERRING VET**

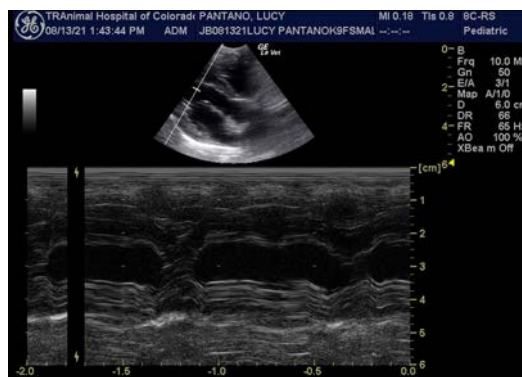
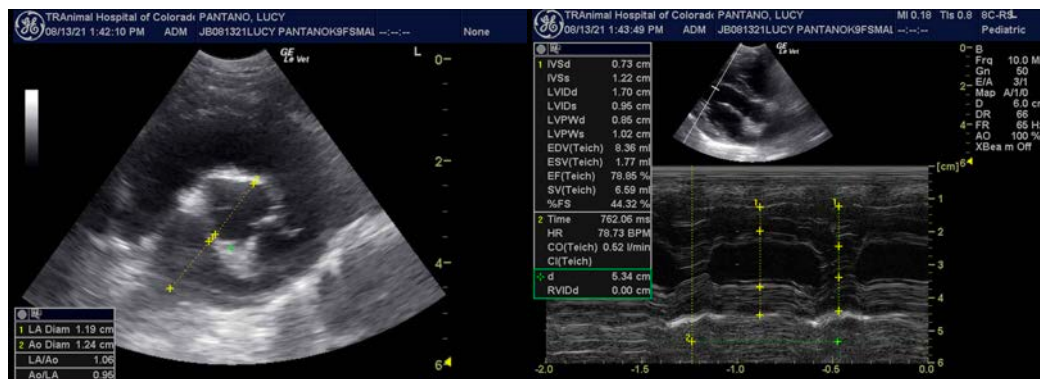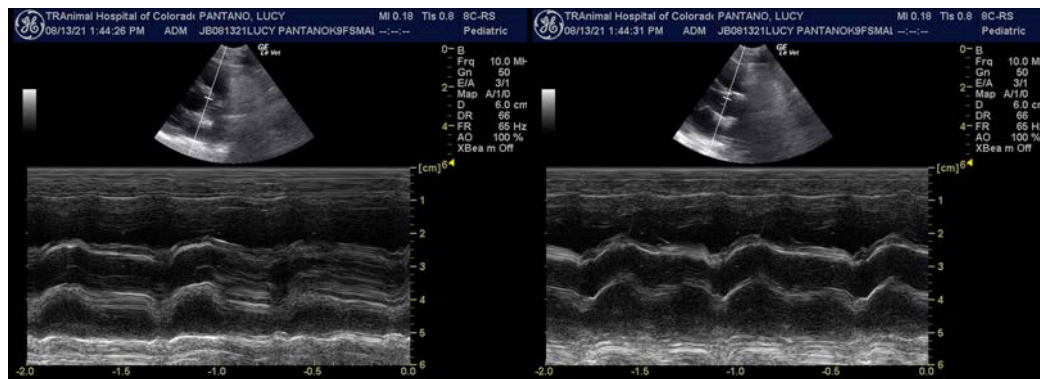
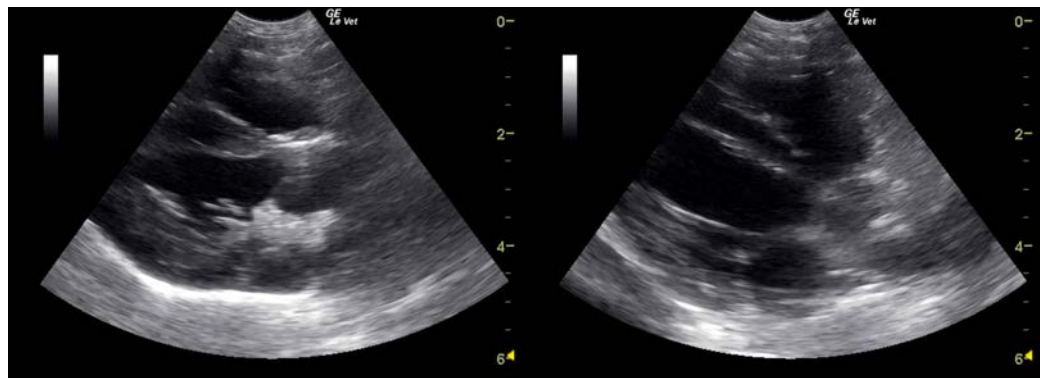
Dr. John A. Boley

**INVOICE**

24705

**DATE**

8/15/21





**PATIENT**

Lucy Pantano

The information and recommendations provided are based on the images presented by the referring veterinarian. No evaluation can be communicated regarding pathology that was not visible in the image/video clips provided.

**SPECIES**

Canine

Thank you for this referral. If the clinical or image interpretation does not parallel your findings or if I can be of any further assistance please contact me.

**BREED**

Malte Poo

**Eric Lindquist**, DMV, DABVP, Cert. IVUSS, CEO of SonoPath.com

[info@SonoPath.com](mailto:info@SonoPath.com)

**SEX**

Spayed Female

**AGE**

3 Years

**WEIGHT**

11.12 Pounds

**INTERPRETED BY**

Eric Lindquist, DMV  
DABVP, Cert. IVUSS

**IMAGING  
PERFORMED BY**

Dr. John A. Boley

**HOSPITAL NAME**

AH of Colorado Springs

**REFERRING VET**

Dr. John A. Boley

**INVOICE**

24705

**DATE**

8/15/21