



PATIENT PRESENTING CLINICAL SIGNS

Emma Grillo

Presented to out ER facility 2 days ago for loss of appetite, lethargy and periods of collapse without losing consciousness. BW was all WNL. She has a heart murmur and recently was diagnosed with a B1 stage heart disease, and no medications were advised. However radiographs showed suspected early CHF. Therapy was started for this, but still no appetite. Repeated BW was WNL except WBC 24.68, Neuts 19.89, and Monocytes 1.92, as well as BUN 40, Creat 2.4. Phosphorus 12.6, and SDMA 23-Azotemic. A nasogastric canula has been placed for feeding.

SPECIES

Canine

BREED

Shih Tzu

Abnormal PE/Chem/CBC/UA Results: BUN 40, Creat 2.4, SDMA 23, Phos 12.6. WBC 24.68, Neuts 19.89, and Monocytes 1.92. CPL <50.

SEX

Spayed Female

ULTRASONOGRAPHIC EXAMINATION OF THE ABDOMEN

Urinary System

AGE

9 Years 11 Months

The **urinary bladder**, trigone, and pelvic urethra presented normal thicknesses and normal tone. The ureters were not visible which is normal. No uroliths or sediment were visualized and anechoic urine was present. No evidence of inflammatory or neoplastic changes were noted. Ureteral papillae were normal. The pelvic urethra was imaged 2.0 cm beyond the cystourethral junction.

WEIGHT

14

The **kidneys** revealed largely normal size and structure, corticomedullary definition and ratio (cortex 1/3 of medulla) were essentially maintained with some age-related loss of curvilinear patterns regarding the capsule and C/M junction. The cortices presented largely uniform texture with some increased echogenicity expected for his age patient. Medullary structure differed distinctly from that of the cortex and no evidence of pelvic dilation was present. The right kidney measured 4.81 cm. The left kidney measured 4.4 cm. Slight pinpoint mineralizations noted in both kidneys yet non-obstructive.

INTERPRETED BY

Eric Lindquist, DMV

DABVP, Cert. IVUSS

Adrenal Glands

IMAGING PERFORMED BY

Dr. Anthony Krawitz

Both **adrenal glands** were visualized and recognized as having normal shape, size, position and echogenicity for this breed. The phrenic vasculature, glandular echogenicity and detail were unremarkable. Capsule, cortex, and medullary definition were normal for this age patient. The left adrenal gland measured 1.77 cm x 0.54 cm at the caudal pole and 0.48 cm at the cranial pole. The right adrenal gland measured 2.17 cm x 0.37 cm at the caudal pole and 0.49 cm at the cranial pole.

HOSPITAL NAME

Calusa Vet Center

Spleen

The **spleen** presented hyperechoic lipid plaques measuring up to 1.5 cm, not pathological.

REFERRING VET

Dr. Sid Ranade

Liver

The **liver** revealed a mixed hypoechoic nodule in the right cranial liver measuring 3.0 cm x 2.9 cm. Ultrasound guided FNA indicated from SDEP #12 position (right intercostal). The remainder of the liver presented slight increased portal markings, largely age related changes, uniform. The gallbladder and common bile duct were unremarkable. Uniform parenchyma.

INVOICE

44646

DATE

8/14/23

Gastrointestinal

Examination of the **gastrointestinal tract** revealed a stomach and intestine free of stasis, of normal wall thickness, acceptable curvilinear mural detail, and peristaltic activity. Small and large intestine



PATIENT

demonstrated normal luminal chyme and stool consistency respectively. No obstructive or overt infiltrative disease was noted. No associated abnormal lymphatic activity was noted.

Emma Grillo

Pancreas

SPECIES

The base and limbs of the **pancreas** were observed to be largely isoechoic to surrounding omental fat. Pancreatic duct and capsular contour were acceptably normal and parenchyma respected normal curvilinear patterns. No overt evidence of active inflammatory or neoplastic disease was noted.

Canine

BREED

ULTRASONOGRAPHIC FINDINGS

Shih Tzu

- Minor renal mineralization
- Hyperechoic lipid plaques in the spleen, not pathological
- Mixed hypoechoic liver nodule

SEX

Spayed Female

INTERPRETATION OF THE FINDINGS & FURTHER RECOMMENDATIONS

AGE

Acute renal insult such as Leptospirosis, toxin exposure, passage of calculi all possible. 48-72 hour IV fluid protocol warranted. Ultrasound guided FNA of the liver nodule indicated. The nodule does not appear to be significantly disruptive, however should be sampled or at least monitored with follow up ultrasound in one month for any growth. This is a difficult region to eventually resect. This is likely hyperplasia. Mild potential for underlying neoplasia such as carcinoma. Screening for Addison's warranted with baseline cortisol, even though the adrenals appear structurally normal.

9 Years 11 Months

WEIGHT

14

INTERPRETED BY

Eric Lindquist, DMV

DABVP, Cert. IVUSS

IMAGING PERFORMED BY

Dr. Anthony Krawitz

HOSPITAL NAME

Calusa Vet Center

REFERRING VET

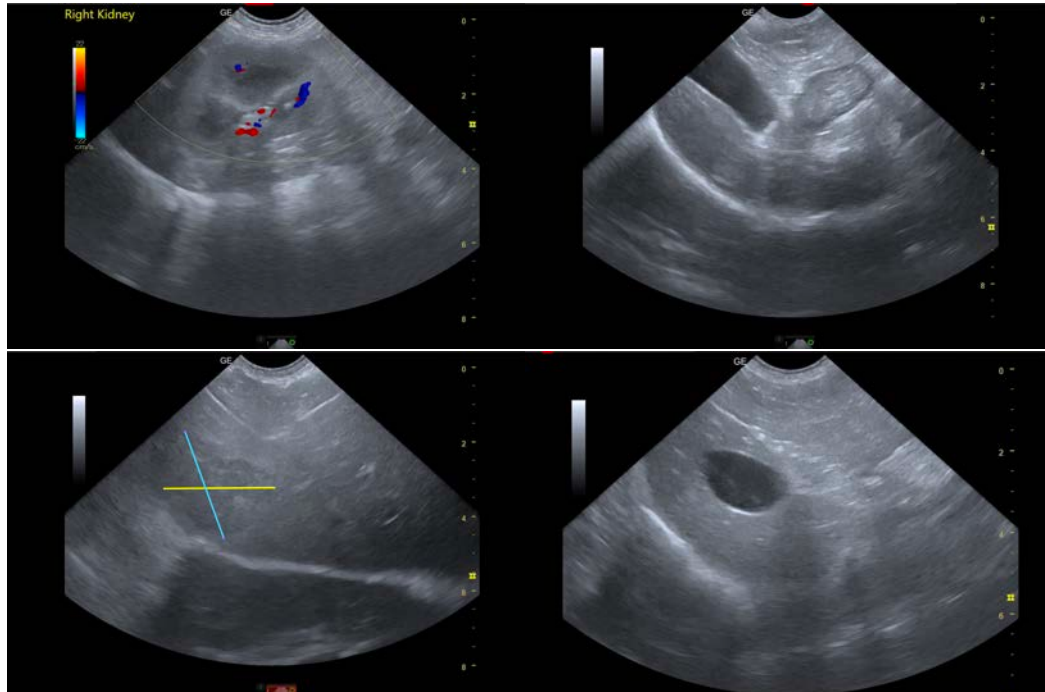
Dr. Sid Ranade

INVOICE

44646

DATE

8/14/23





PATIENT

Emma Grillo

SPECIES

Canine

BREED

Shih Tzu

SEX

Spayed Female

AGE

9 Years 11 Months

WEIGHT

14

INTERPRETED BY

Eric Lindquist, DMV
DABVP, Cert. IVUSS

IMAGING PERFORMED BY

Dr. Anthony Krawitz

HOSPITAL NAME

Calusa Vet Center

REFERRING VET

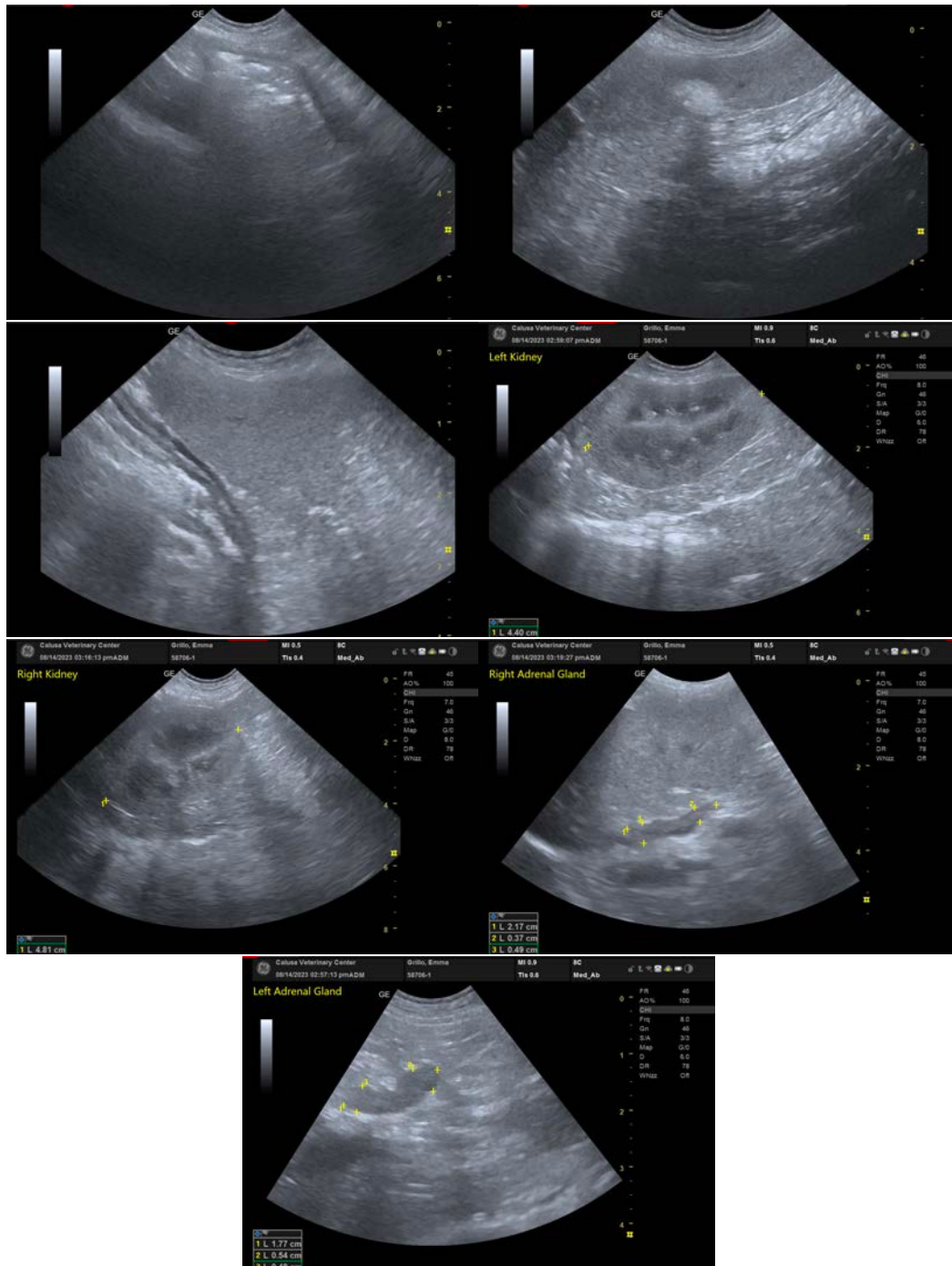
Dr. Sid Ranade

INVOICE

44646

DATE

8/14/23





PATIENT

Emma Grillo

The information and recommendations provided are based on the images presented by the referring veterinarian/sonographer. No evaluation can be communicated regarding pathology that was not visible in the image/video clips provided.

SPECIES

Canine

Thank you for this referral. If the clinical or image interpretation does not parallel your findings or if I can be of any further assistance please contact me.

BREED

Shih Tzu

Eric Lindquist, DMV, DABVP, Cert. IVUSS, CEO of SonoPath.com

info@SonoPath.com

SEX

Spayed Female

AGE

9 Years 11 Months

WEIGHT

14

INTERPRETED BY

Eric Lindquist, DMV

DABVP, Cert. IVUSS

IMAGING PERFORMED BY

Dr. Anthony Krawitz

HOSPITAL NAME

Calusa Vet Center

REFERRING VET

Dr. Sid Ranade

INVOICE

44646

DATE

8/14/23