



PATIENT

Bernard Conklin

SPECIES

Canine

BREED

Mix

SEX

Neutered male

AGE

18 years

WEIGHT

13.7 lbs

INTERPRETED BY

Eric Lindquist, DMV
DABVP, Cert. IVUSS

IMAGING PERFORMED BY

Chelsea Pastor

HOSPITAL NAME

Fredon AH

REFERRING VET

Dr. Grau

INVOICE

46582

DATE

8/14/23

PRESENTING CLINICAL SIGNS

History: O feels pt stomach gets bloated, great appetite. No vomiting/diarrhea when bloating occurs. Not on keppra since initiation/discontinuation, last seizure was ~3 weeks ago, seizure events seem to come when he is distended and breathing very heavily

Abnormal PE/Chem/CBC/UA Results: PE: BCS 5/9, incomplete cataracts, grade 2/6 systolic murmur, cranial organomegaly but nothing painful/tympanic Rads: lat abd - severe hepatomegaly, no overt change in shape just large, empty stomach is lifted dorsally, rest of abd NSF

ULTRASONOGRAPHIC EXAMINATION OF THE ABDOMEN

Urinary System

The **bladder** in this patient was mildly thickened with slight echogenic mural changes. No calculi or masses were noted. Slight micropolypoid changes were noted. This is a frequent finding in older animals and may be linked to a history of chronic urinary tract infection or active urinary tract infection. Urinalysis would be recommended with culture if any evidence of inflammatory sediment is present. The region of the trigone and visible pelvic urethra were normal.

The **kidneys** presented a relatively uniform cortical hyperechogenicity when compared to the renal medulla, spleen and liver. No overt masses were noted. Corticomedullary definition was nebulous and the ratio favored the cortex slightly. The ureters were not visible and assumed to be normal. These changes are most consistent with chronic interstitial nephritis yet infiltrative disease could not be entirely ruled out without biopsy though neoplasia is not suspected. The left kidney measured 4.25 cm. The right kidney measured 4.57 cm.

Adrenal Glands

Both **adrenal glands** were visualized and recognized as having normal shape, size, position and echogenicity for this breed. The phrenic vasculature, glandular echogenicity and detail were unremarkable. Capsule, cortex, and medullary definition were normal for this age patient.

Spleen

The **spleen** presented a smooth homogeneous parenchyma hyperechoic to liver and renal cortical parenchyma. The capsule was smooth without noticeable expansion or deviation from within the spleen or adjacent pathology. The splenic vasculature demonstrated normal volume without signs of congestion or thrombosis. No sonographic evidence of acute or chronic inflammatory, neoplastic, or infarctual changes was noted.

Liver

The **liver** was uniformly swollen with minor, excessive gallbladder debris and over distension with dependent and suspended bile without evidence of overt mucocele formation. However, excessive sludge was present. The liver presented coarse architecture with mildly increased portal markings and subtle, mixed echogenic changes. This is consistent with vacuolar hepatopathy and some level of remodeling and history of inflammatory component. There was no overt suspicion of neoplasia. Shower curtain lung pattern was noted. This is consistent with alveolar disease/B lines.



PATIENT

Bernard Conklin

SPECIES

Canine

BREED

Mix

SEX

Neutered male

AGE

18 years

WEIGHT

13.7 lbs

INTERPRETED BY

Eric Lindquist, DMV
DABVP, Cert. IVUSS

IMAGING PERFORMED BY

Chelsea Pastor

HOSPITAL NAME

Fredon AH

REFERRING VET

Dr. Grau

INVOICE

46582

DATE

8/14/23

Gastrointestinal

Examination of the **gastrointestinal tract** revealed a stomach and intestine free of stasis, of normal wall thickness, acceptable curvilinear mural detail, and peristaltic activity. Small and large intestine demonstrated normal luminal chyme and stool consistency respectively. No obstructive or overt infiltrative disease was noted. No associated abnormal lymphatic activity was noted.

Pancreas

The base and limbs of the **pancreas** were observed to be largely isoechoic to surrounding omental fat. Some parenchymal remodeling, however, with mild deviation from curvilinear normalcy was observed. Pancreatic duct and capsular irregularities were present consistent with age related changes. If pain upon imaging (+ Murphy sign) was present or if the patient is focally painful in subxiphoid palpation then low-grade smoldering chronic pancreatitis should be suspected.

ULTRASONOGRAPHIC FINDINGS

Geriatric abdomen with chronic interstitial nephrosis pattern.

Mild hepatomegaly, benign.

There was no evidence of significant pathology; however, lung disease/alveolar disease is suspected given the shower curtain lung pattern noted through the diaphragm.

INTERPRETATION OF THE FINDINGS & FURTHER RECOMMENDATIONS

Chest radiographs are warranted if not already performed to assess for alveolar disease. Structurally the GI tract is unremarkable. Supportive care for gastric insult and bloating such as b.i.d. canned feedings +/- promotility medications. I would be concerned for aspiration pneumonia as a potential given the alveolar consolidations noted through the diaphragm. Chest and skull CT would be appropriate in this patient. Skull CT is recommended given the age of the patient and seizure activity.

ABOUT SONOPATH CT SERVICES:

SonoPath CT Services are offered at the SonoPath Imaging and Veterinary Education Center, 141 Main St (rt 206), Andover, New Jersey, a 20-minute drive west on route 80/206 North from the route 80/287 interchange/Parsippany, New Jersey. More information can be found at <https://sonopath.com/services/vetimaging/>



PATIENT

Bernard Conklin

SPECIES

Canine

BREED

Mix

SEX

Neutered male

AGE

18 years

WEIGHT

13.7 lbs

INTERPRETED BY

Eric Lindquist, DMV
DABVP, Cert. IVUSS

IMAGING PERFORMED BY

Chelsea Pastor

HOSPITAL NAME

Fredon AH

REFERRING VET

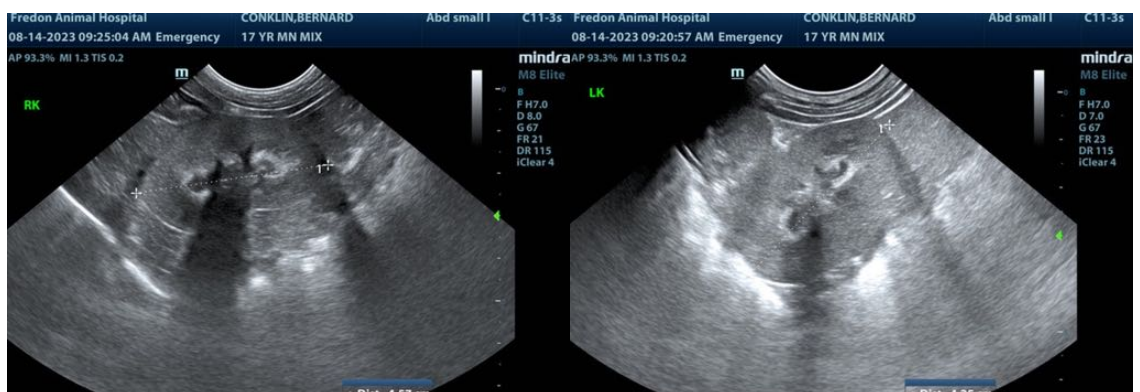
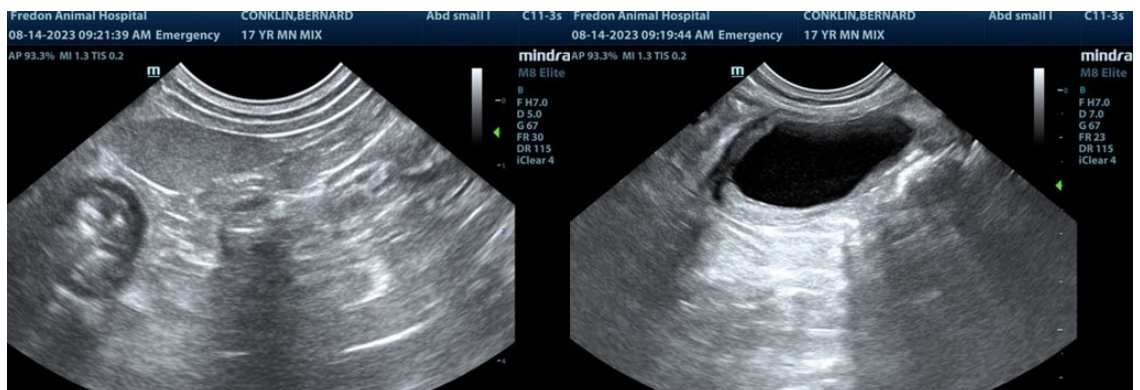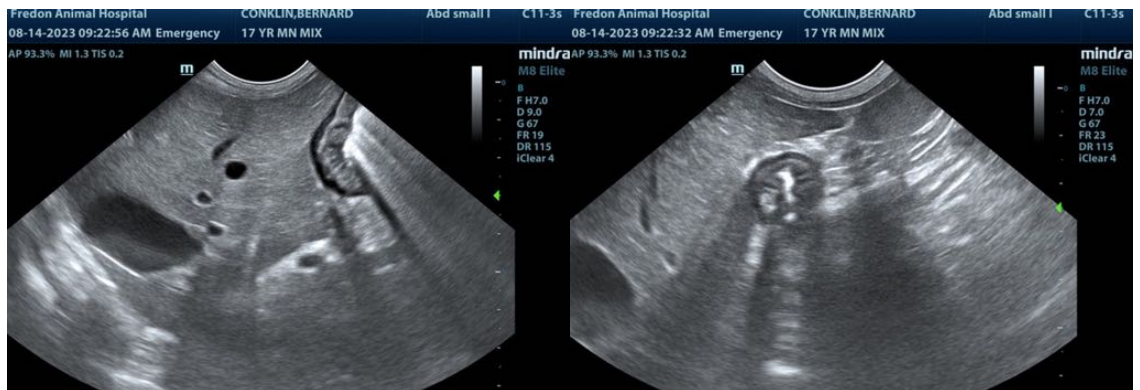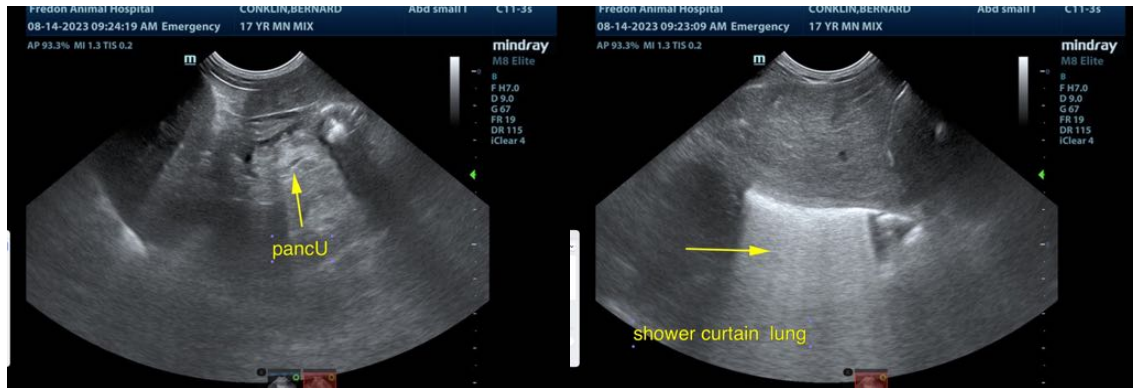
Dr. Grau

INVOICE

46582

DATE

8/14/23





PATIENT

Bernard Conklin

The information and recommendations provided are based on the images presented by the referring veterinarian/sonographer. No evaluation can be communicated regarding pathology that was not visible in the image/video clips provided.

SPECIES

Canine

Thank you for this referral. If the clinical or image interpretation does not parallel your findings or if I can be of any further assistance please contact me.

BREED

Mix

Eric Lindquist, DMV, DABVP, Cert. IVUSS, CEO of SonoPath.com
info@SonoPath.com

SEX

Neutered male

AGE

18 years

WEIGHT

13.7 lbs

INTERPRETED BY

Eric Lindquist, DMV
DABVP, Cert. IVUSS

IMAGING PERFORMED BY

Chelsea Pastor

HOSPITAL NAME

Fredon AH

REFERRING VET

Dr. Grau

INVOICE

46582

DATE

8/14/23