



**PATIENT**

Cloud Brewer

**SPECIES**

Feline

**BREED**

Siamese

**SEX**

Female

**AGE**

13 Years

**WEIGHT**

4.6 Pounds

**INTERPRETED BY**

Eric Lindquist, DMV

DABVP, Cert. IVUSS

**IMAGING PERFORMED BY**

Dallas Reynolds

**HOSPITAL NAME**

Lone Mountain AH

**REFERRING VET**

Dr. Jarred

**INVOICE**

40425

**DATE**

8/13/22

**PRESENTING CLINICAL SIGNS**

P presents for moderate elevated liver enzymes and anorexia. Long history of chronic IRD and asthma - currently having a flare.

Abnormal PE/Chem/CBC/UA Results: Rads show signs consistent with asthma, BW showed Alt of ~500 and WBC of 46k

**ULTRASONOGRAPHIC EXAMINATION OF THE ABDOMEN**

**Urinary System**

The **urinary bladder**, trigone, and pelvic urethra presented normal thicknesses and normal tone. The ureters were not visible which is normal. No uroliths or sediment were visualized and anechoic urine was present. No evidence of inflammatory or neoplastic changes were noted. Ureteral papillae were normal.

The **right kidney** revealed a dysplastic cyst or other deformation. No evidence of inflammation or echogenic debris noted. Assessment for trauma history warranted in this patient. It appears to be stable.

The **left kidney** revealed normal size and structure, corticomedullary definition and ratio for this age. The cortex presented largely uniform texture with normal echogenic relationship to liver and spleen. Medullary structure differed distinctly from the cortex and no evidence of pelvic dilation was present. The capsule was acceptably uniform without significant irregularities.

**Adrenal Glands**

The regions of the **adrenal glands** were unremarkable.

**Spleen**

The **spleen** presented a smooth homogeneous parenchyma hyperechoic to liver and renal cortical parenchyma. The capsule was smooth without noticeable expansion or deviation from within the spleen or adjacent pathology. The splenic vasculature demonstrated normal volume without signs of congestion or thrombosis. No sonographic evidence of acute or chronic inflammatory, neoplastic, or infarctual changes were noted.

**Liver**

The **liver** images submitted revealed subjectively normal liver size, contour, and structure. Parenchymal echogenicity was naturally coarse and hypoechoic to the spleen. Vascular and biliary tracts were of normal volume with no evidence of congestion. The gallbladder wall was slightly echogenic and slightly thickened. Minor gallbladder debris noted. The common bile duct was normal at 4.0 mm. The cystic duct was mildly tortuous.

**Gastrointestinal**

Examination of the **gastrointestinal tract** revealed a stomach and intestine free of stasis, of normal wall thickness, acceptable curvilinear mural detail, and peristaltic activity. Small and large intestine demonstrated normal luminal chyme and stool consistency respectively. No obstructive or overt infiltrative disease was noted. No associated abnormal lymphatic activity was noted.

**Pancreas**

The **pancreas** was hypoechoic and irregular.

**ULTRASONOGRAPHIC FINDINGS**



**PATIENT**

Cloud Brewer

- Irregular cystic right renal formation - possible result of prior trauma or congenital lesion
- Chronic cholangitis liver pattern
- Heterogeneous pancreas – suggestive for inflammation.

**SPECIES**

Feline

**INTERPRETATION OF THE FINDINGS & FURTHER RECOMMENDATIONS**

Palpation of the right kidney warranted to assess for any discomfort. Treatment for pancreatitis and cholangitis indicated, such as Zithromax/Metronidazole combination. Diet change may be in this patient's best interest. No overt evidence of neoplasia. An early neoplastic event in the right kidney cannot be completely ruled out. However, this is an odd presentation, more likely stable cystic or other deformation.

**BREED**

Siamese

**SEX**

Female

**AGE**

13 Years

**WEIGHT**

4.6 Pounds

**INTERPRETED BY**

Eric Lindquist, DMV  
DABVP, Cert. IVUSS

**IMAGING PERFORMED BY**

Dallas Reynolds

**HOSPITAL NAME**

Lone Mountain AH

**REFERRING VET**

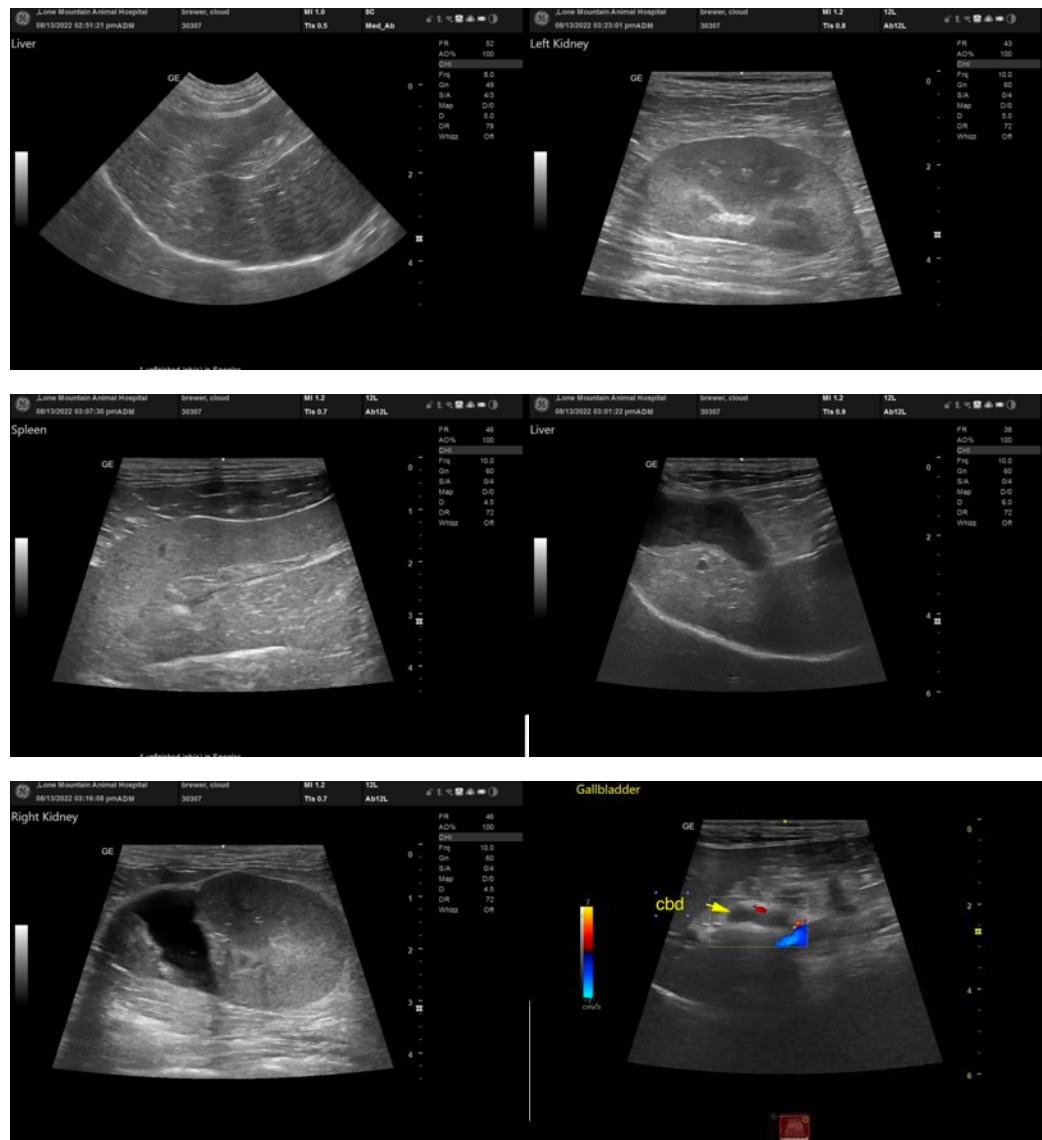
Dr. Jarred

**INVOICE**

40425

**DATE**

8/13/22





**PATIENT**

Cloud Brewer

**SPECIES**

Feline

**BREED**

Siamese

**SEX**

Female

**AGE**

13 Years

**WEIGHT**

4.6 Pounds

**INTERPRETED BY**

Eric Lindquist, DMV

DABVP, Cert. IVUSS

**IMAGING PERFORMED BY**

Dallas Reynolds

**HOSPITAL NAME**

Lone Mountain AH

**REFERRING VET**

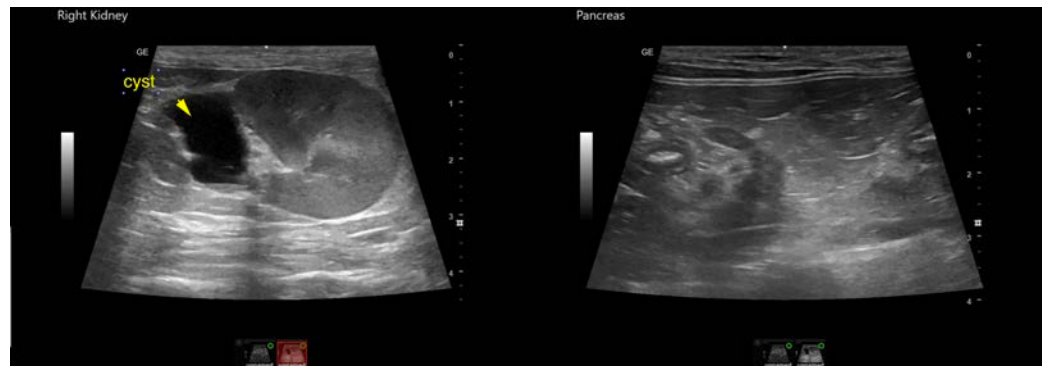
Dr. Jarred

**INVOICE**

40425

**DATE**

8/13/22



The information and recommendations provided are based on the images presented by the referring veterinarian/sonographer. No evaluation can be communicated regarding pathology that was not visible in the image/video clips provided.

Thank you for this referral. If the clinical or image interpretation does not parallel your findings or if I can be of any further assistance please contact me.

Eric Lindquist, DMV, DABVP, Cert. IVUSS, CEO of SonoPath.com

[info@SonoPath.com](mailto:info@SonoPath.com)