



PATIENT

Wrangler Simmons

SPECIES

Canine

BREED

Poodle Cross

SEX

Neutered male

AGE

12 years

WEIGHT

18 lbs

INTERPRETED BY

Eric Lindquist, DMV
DABVP, Cert. IVUSS

IMAGING PERFORMED BY

Dr. Favis

HOSPITAL NAME

Ruidoso AC

REFERRING VET

Dr. Favis

INVOICE

91216

DATE

8/13/21

PRESENTING CLINICAL SIGNS

History: Not clinical - incidental finding with bloodwork
Abnormal PE/Chem/CBC/UA Results: Elevating hepatic values - ALT 399, ALP >2000, GGT 89, Cholesterol 421

ULTRASONOGRAPHIC EXAMINATION OF THE ABDOMEN

Liver

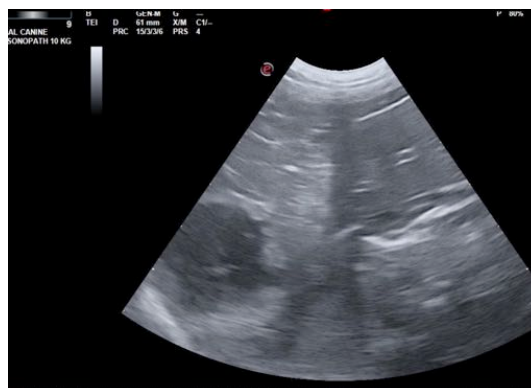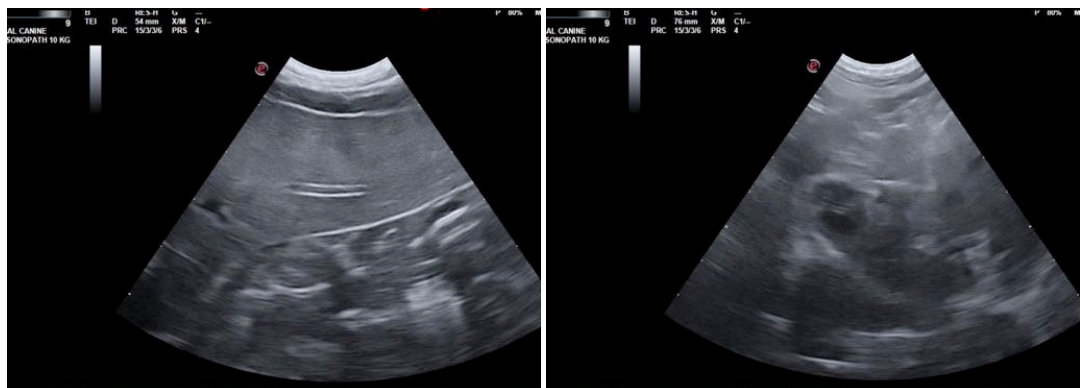
The liver revealed uniform enlargement and minor, heterogenous parenchymal changes. Minor gallbladder debris was noted with an echogenic wall. Mixed, echogenic, nodular hepatic changes. The presentation is most consistent with vacuolar hepatopathy and nodular hyperplasia. There is a history of chronic cholangitis. The gallbladder revealed polypoid changes. .

ULTRASONOGRAPHIC FINDINGS

Enlarged liver with heterogenous changes.

INTERPRETATION OF THE FINDINGS & FURTHER RECOMMENDATIONS

FNA of the liver is recommended for further definition. Bile acid profile would be ideal. There was no overt evidence of masses or neoplasia. Underlying endocrinopathy should be considered.





PATIENT

Wrangler Simmons

The information and recommendations provided are based on the images presented by the referring veterinarian. No evaluation can be communicated regarding pathology that was not visible in the image/video clips provided.

SPECIES

Canine

Thank you for this referral. If the clinical or image interpretation does not parallel your findings or if I can be of any further assistance please contact me.

BREED

Poodle Cross

Eric Lindquist, DMV, DABVP, Cert. IVUSS, CEO of SonoPath.com
info@SonoPath.com

SEX

Neutered male

AGE

12 years

WEIGHT

18 lbs

INTERPRETED BY

Eric Lindquist, DMV
DABVP, Cert. IVUSS

**IMAGING
PERFORMED BY**

Dr. Favis

HOSPITAL NAME

Ruidoso AC

REFERRING VET

Dr. Favis

INVOICE

91216

DATE

8/13/21