



PATIENT PRESENTING CLINICAL SIGNS

Leroy Oliver

History: Presented for annual on 8-5. Pt had around 4th July vestibular symptoms and was slow to improve over a few weeks. Pt has not been the same since and has a slight head tilt to the left. Pt appetite has not been as good since episode. d/ur/bm normal. Pt having accidents during the night if O doesn't notice soon enough. c/s/v/d none. Wt loss. Numerous SQ skin masses of various sizes. Arthritis
Abnormal PE/Chem/CBC/UA Results: ALT 122 IU/L ALP 627 IU/L GGT 43 IU/L PSL 143 U/L

SPECIES

Canine

BREED

German Shorthair
Pointer

ULTRASONOGRAPHIC EXAMINATION OF THE ABDOMEN

SEX

Neutered male

Urinary System

The **urinary bladder**, trigone, and pelvic urethra presented normal thicknesses and normal tone. The ureters were not visible which is normal. No uroliths or sediment were visualized and anechoic urine was present. No evidence of inflammatory or neoplastic changes was noted. Ureteral papillae were normal.

AGE

13 years

The **kidneys** revealed largely normal size and structure, corticomedullary definition and ratio (cortex 1/3 of medulla) were essentially maintained with some age-related loss of curvilinear patterns regarding the capsule and C/M junction. The cortices presented largely uniform texture with some increased echogenicity expected for this age patient. Medullary structure differed distinctly from that of the cortex and no evidence of pelvic dilation was present. The left kidney measured 7.04 cm. The right kidney measured 6.31 cm.

WEIGHT

65 lbs

INTERPRETED BY

Eric Lindquist, DMV
DABVP, Cert. IVUSS

Adrenal Glands

Both **adrenal glands** were visualized and recognized as having normal shape, size, position and echogenicity for this breed. The phrenic vasculature, glandular echogenicity and detail were unremarkable. Capsule, cortex, and medullary definition were normal for this age patient. The left adrenal gland measured 1.16 x 0.42 cm at the caudal pole and 0.43 cm at the cranial pole.

IMAGING PERFORMED BY

Dr. Carter

Spleen

HOSPITAL NAME

Willamette VH

The **spleen** presented a smooth homogeneous parenchyma hyperechoic to liver and renal cortical parenchyma. The capsule was smooth without noticeable expansion or deviation from within the spleen or adjacent pathology. The splenic vasculature demonstrated normal volume without signs of congestion or thrombosis. No sonographic evidence of acute or chronic inflammatory, neoplastic, or infarctual changes was noted.

REFERRING VET

Dr. Porter

Liver

INVOICE

91225

An expansive 9.0 x 8.7 cm left cranial liver mass was noted. The liver revealed mildly uniform parenchyma with mild deviation from normal architecture. This is most consistent with hepatoma or low-grade carcinoma and may prove to be resectable. CT evaluation is recommended for surgical planning. The right liver was unremarkable. The mass deviated the gallbladder caudally. Adherence to the diaphragm may be an issue.

DATE

8/13/21



PATIENT

Gastrointestinal

Leroy Oliver

Examination of the **gastrointestinal tract** revealed a stomach and intestine free of stasis, of normal wall thickness, acceptable curvilinear mural detail, and peristaltic activity. Small and large intestine demonstrated normal luminal chyme and stool consistency respectively. No obstructive or overt infiltrative disease was noted. No associated abnormal lymphatic activity was noted.

SPECIES

Canine

BREED

German Shorthair Pointer

SEX

Neutered male

AGE

13 years

WEIGHT

65 lbs

INTERPRETED BY

Eric Lindquist, DMV DABVP, Cert. IVUSS

IMAGING PERFORMED BY

Dr. Carter

HOSPITAL NAME

Willamette VH

REFERRING VET

Dr. Porter

INVOICE

91225

DATE

8/13/21

Pancreas

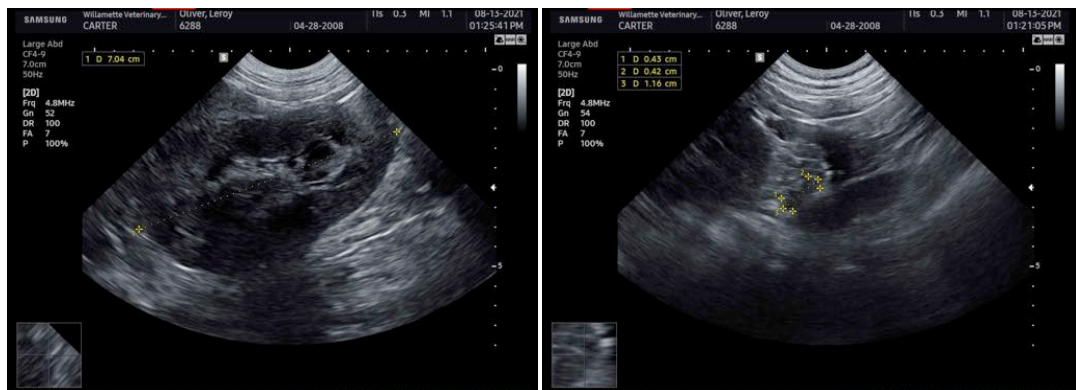
The base and limbs of the **pancreas** were observed to be largely isoechoic to surrounding omental fat. Some parenchymal remodeling, however, with mild deviation from curvilinear normalcy was observed. Pancreatic duct and capsular irregularities were present consistent with age related changes. If pain upon imaging (+ Murphy sign) was present or if the patient is focally painful in subxiphoid palpation then low-grade smoldering chronic pancreatitis should be suspected.

ULTRASONOGRAPHIC FINDINGS

Left cranial medial liver mass with hepatoma versus carcinoma.

INTERPRETATION OF THE FINDINGS & FURTHER RECOMMENDATIONS

Ultrasound-guided FNA is warranted. CT evaluation for potential surgical planning. The position may be difficult to mass and may be adhered to the diaphragm. The vestibular signs may be complete non related to the liver mass. Brain/skull CT is recommended with contrast. Chest CT is recommended for metastatic disease and abdominal CT for potential surgical planning. Guarded prognosis.





PATIENT

Leroy Oliver

SPECIES

Canine

BREED

German Shorthair
Pointer

SEX

Neutered male

AGE

13 years

WEIGHT

65 lbs

INTERPRETED BY

Eric Lindquist, DMV
DABVP, Cert. IVUSS

IMAGING PERFORMED BY

Dr. Carter

HOSPITAL NAME

Willamette VH

REFERRING VET

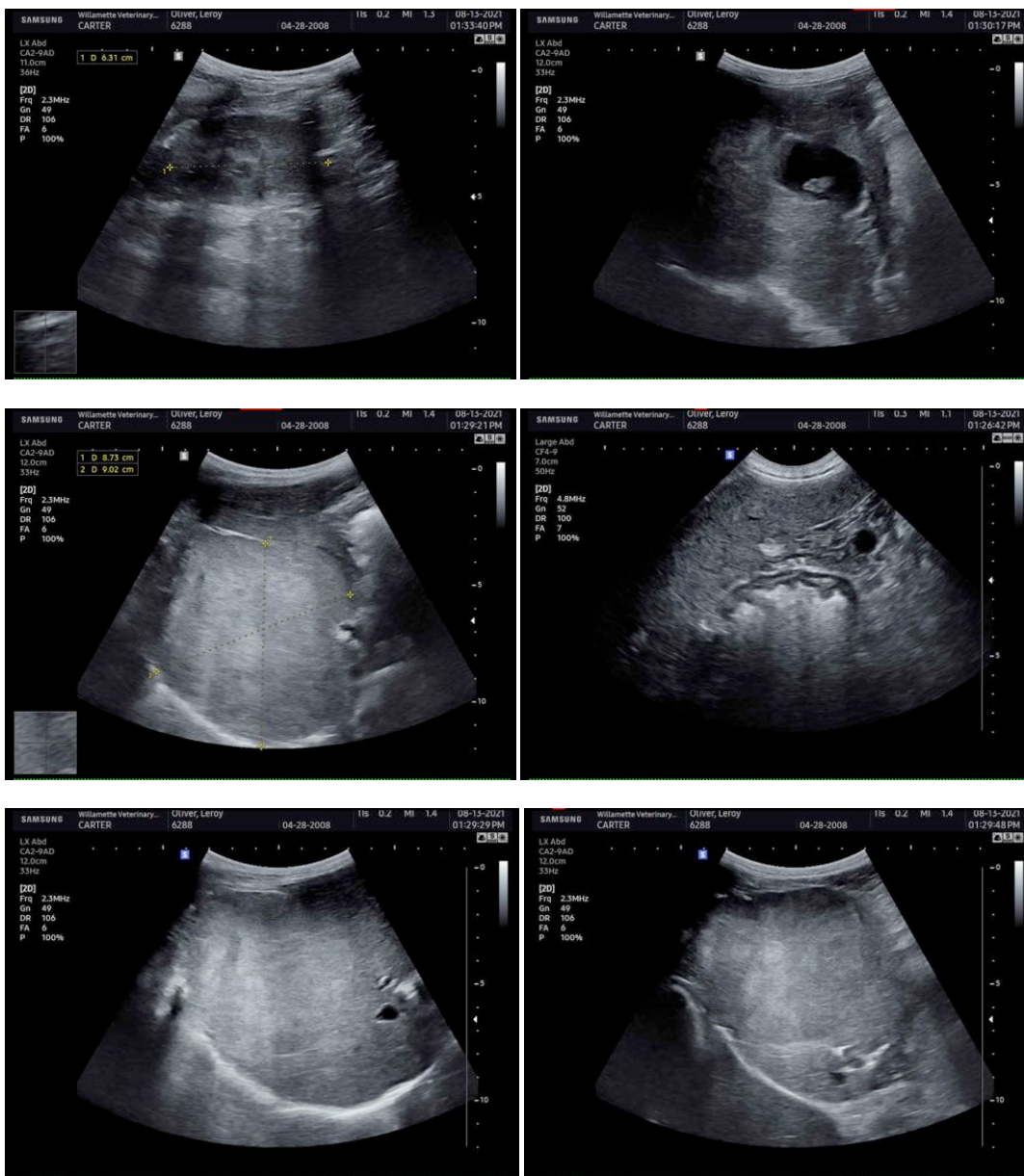
Dr. Porter

INVOICE

91225

DATE

8/13/21



The information and recommendations provided are based on the images presented by the referring veterinarian. No evaluation can be communicated regarding pathology that was not visible in the image/video clips provided.


Thank you for this referral. If the clinical or image interpretation does not parallel your findings or if I can be of any further assistance please contact me.

Eric Lindquist, DMV, DABVP, Cert. IVUSS, CEO of SonoPath.com
info@SonoPath.com



PATIENT

Leroy Oliver



The following is an applicable excerpt from the *Curbside Guide to Diagnosis & Treatment of Sonographic Disease* offered by [SonoPath.com](http://sonopath.com) Lindquist, Frank, Lobetti, and Modler.

SPECIES

Canine

An essential quick guide for every general practitioner and sonographer.

<https://sonopath.com/products/curbside-guide-editing-due-release-12012015>

BREED

German Shorthair
Pointer

Hepatic Masses, Biliary Adenoma, and Biliary Adenocarcinoma

<http://www.sonopath.com/HepaticMasses>

SEX

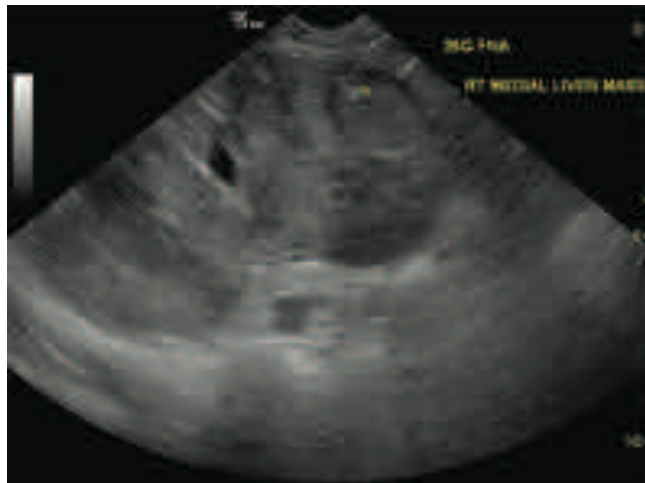
Neutered male

AGE

13 years

WEIGHT

65 lbs



Fine needle aspiration of a right medial lobe mass of a canine liver in subxiphoidal short axis. A large heterogenous mass lesion is seen expanding upon the liver capsule. Note the hyperechoic needle tip (arrowhead) within the mass. US- guided FNA captures cells and may not be sensitive to structural pathology or carcinoma present in the midst of vacuolar hepatopathy or nodular hyperplastic changes. Hence, the sonographer should sample a variety of echogenicities within the lesion or perform a core biopsy.

INTERPRETED BY

Eric Lindquist, DMV
DABVP, Cert. IVUSS

IMAGING PERFORMED BY

Dr. Carter

HOSPITAL NAME

Willamette VH

REFERRING VET

Dr. Porter

Description: Hepatocellular carcinoma typically manifests in the liver's left lateral lobes, yet may cross over to the right lobes should it derive from the hilus. These masses often present cavitating, necrotic cores that are difficult to distinguish from hepatic abscesses. Vascular channels may also be involved, and bile duct obstruction is often present. Older felines often present solitary or multiple fluid-filled cysts within the hepatic parenchyma. The latter are typically benign cystadenomas and should be differentiated from: cystic adenocarcinoma; hepatic lymphoma (usually diffusely hyperechoic +/- FIV/FelV association); metastatic neoplasia (diffuse hyper- to hypoechoic nodules secondary to mammary adenocarcinoma, splenic hemangiosarcoma, or pancreatic or intestinal adenocarcinoma); benign nodular hyperplasia (accompanied by minimal to no symptoms); hepatic cirrhosis (regenerative nodules); or rare carcinoids, fibrosarcomas, leiomyosarcomas, and osteosarcomas.

INVOICE

91225

Clinical Signs: Possible clinical signs and physical exam findings include cranial abdominal organomegaly, sudden collapse associated with mass rupture, vomiting, ascites, jaundice (severe cases), and hypoglycemia secondary to a paraneoplastic syndrome. Sepsis and fever associated with secondary abscessation of the mass may also occur. Cats usually present with anorexia and lethargy.

DATE

8/13/21

Diagnostics: Routine biochemical analysis primarily shows liver enzyme elevation (i.e., ALT for cellular necrosis; SAP for hepatic congestion; elevated bilirubin for stasis/obstruction; bile acids > 75-100uM/L for significant function impairment). Staging of the disease with 3-view thoracic radiographs is essential,



PATIENT

Leroy Oliver

SPECIES

Canine

BREED

German Shorthair
Pointer

SEX

Neutered male

AGE

13 years

WEIGHT

65 lbs

INTERPRETED BY

Eric Lindquist, DMV
DABVP, Cert. IVUSS

**IMAGING
PERFORMED BY**

Dr. Carter

HOSPITAL NAME

Willamette VH

REFERRING VET

Dr. Porter

INVOICE

91225

DATE

8/13/21

as is conducting a CBC, serum biochemistry, urinalysis, as well as abdominal and possibly also thoracic ultrasounds in order to provide the owner with adequate and well-informed options. Surgical and oncological referral is recommended after a coagulation panel has been assessed and ultrasound-guided biopsies of both normal and pathological tissue have been performed such that the disease is adequately characterized. In cases where surgical resection is impossible, direct chemoembolization of the tumor blood supply could be considered; however, this procedure is only performed at specific tertiary referral locations. Placement of palliative stents into the caudal vena cava (CVC) can be considered as well if compression by an unresectable tumor causes excessive ascitic fluid accumulation. Serum alpha-fetoprotein (AFP) has been shown to reemerge in dogs with malignant hepatobiliary adenocarcinoma. Ultrasound is important to localize the mass in relation to the portal hilus and gallbladder. The portal vein, CVC, aorta, gallbladder, and bile duct should all be identified with respect to the location of the mass to determine resectability. Ultrasound also allows for an examination of possible metastatic sites in the abdomen and, to some degree, in the thorax.

Treatment: Hepatic adenoma, hepatoma, and adenocarcinoma are usually amenable to surgical resection via hepatic lobectomy should the pathology be isolated to single-lobe progression. Multi-lobar presentation may be amenable to lobectomy and debulking; this will be determined further during surgical consultation. These tumors tend to displace unaffected parenchyma, allowing for relatively straightforward surgical resection. Up to 80% of the liver can be removed without long-term functional deficits. Blood transfusions may be necessary during surgery. The development and implementation of the LDS™ stapler has helped to streamline the procedure. Most carcinomas have metastasized by the time of diagnosis yet tend to be slow-growing; thus, it may be possible for a certain quality of life to be attained via surgical resection. Hepatic hemangiosarcoma has usually metastasized at the time of diagnosis and carries a much poorer prognosis. Surgical resection and chemotherapy are recommended, but considered by many to be an “aggressive” approach.

Preliminary trials have shown that gemcitabine is well tolerated and yields good responses in cases of hepatic as well as pancreatic, colonic, and gastric carcinomas. Myelosuppression, however, remains the key issue. Doxorubicin, cyclophosphamide, and fluorouracil combinations have also proven fruitful.

Nonsteroidal anti-inflammatory drugs (NSAIDs) have been demonstrated to have an anti-neoplastic effect due to their inhibition of COX-2 in certain tumor cells. The end product of the cyclooxygenase cascade is prostaglandin E2, which, when expressed in tumor cell lines—and not expressed in normal cells of that particular cell line—results in inhibited apoptosis, immunosuppression, and increased angiogenesis, proliferation, and invasiveness. Inappropriate increases in COX-2 expression have been documented in certain neoplasias, including squamous cell carcinoma, mammary carcinomas, prostatic carcinoma, malignant melanoma, and transitional cell carcinoma.

Metronomic chemotherapy is currently being investigated and compared to traditional chemotherapy protocols; it is thought to be at least as effective as the latter with substantially less toxic side effects. Metronomic chemotherapy is the practice of uninterrupted administration of low-dose cytotoxic drugs at regular and frequent intervals, as opposed to high-dose, shorter-term protocols characteristic of traditional chemotherapeutic practices. The lower dose allows for long-term administration without toxic side effects, and has been postulated as providing longer remission intervals. Moreover, it has the benefit of minimizing the intervals between drug regimens—the period during which tumor cells may repopulate the area—as well as the chance of developing multi-drug resistant genes. Metronomic chemotherapy has been used successfully in human patients who have undergone previous chemotherapy administration. It is thought to destroy endothelial cells, thereby retarding angiogenesis and targeting regulatory T cells. To date, there have only been a few small clinical trials in veterinary patients, and these have focused on animals that have hemangiosarcoma and soft tissue sarcomas.



PATIENT

Leroy Oliver

Conclusion: With respect to hepatic neoplasia, many surgical and chemotherapeutic options exist; however, it is best to consult with a local board certified oncologist who can help determine the best course of action.

SPECIES

Canine

BREED

German Shorthair Pointer

SEX

Neutered male

AGE

13 years

WEIGHT

65 lbs

INTERPRETED BY

Eric Lindquist, DMV
DABVP, Cert. IVUSS

IMAGING PERFORMED BY

Dr. Carter

HOSPITAL NAME

Willamette VH

REFERRING VET

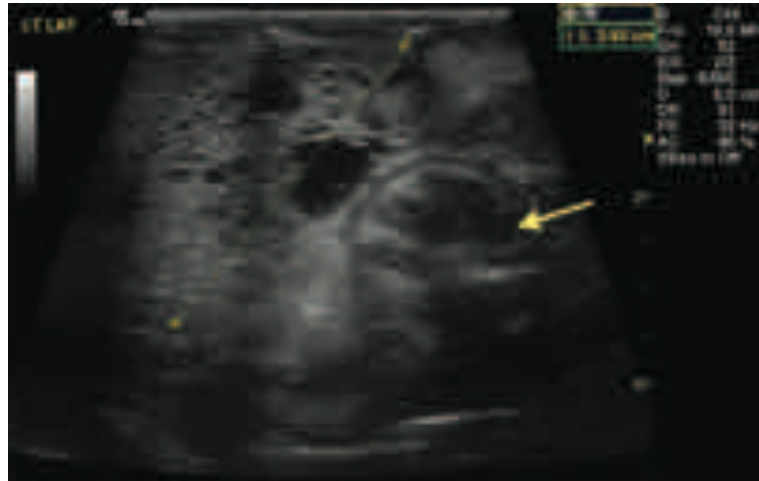
Dr. Porter

INVOICE

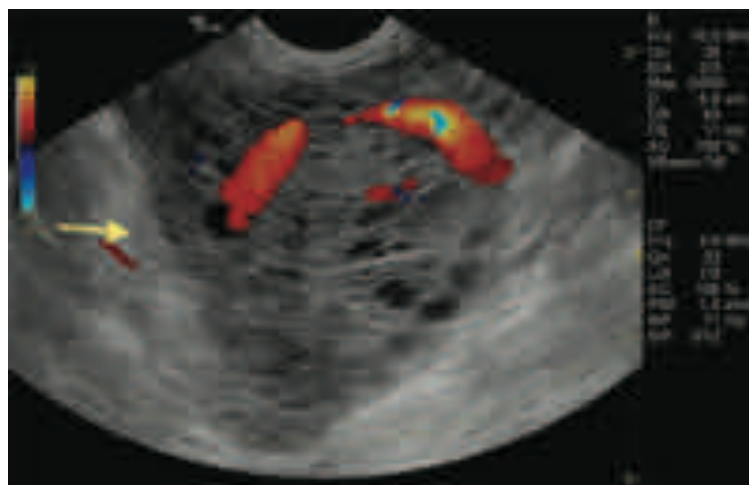91225

DATE

8/13/21



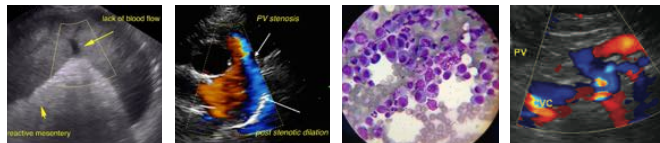
Subxiphoidal long axis of the left liver in a cat with a biliary cystadenoma. Note the typical heterogenous multicystic appearance of the mass lesion displacing the regular echotexture. Acoustic enhancement is seen deep to the cystic components of the lesion. These typically benign tumors can also cause local displacement of organs such as the stomach (arrow), undergo lobar torsion, or malignant transformation that necessitate removal when this criteria is met or suspected.



Subxiphoidal long axis of the liver in a dog with a hepatocellular carcinoma. A large irregular shaped mass lesion expanding the liver capsule is seen with echogenic fat indicative of inflammation (arrow). The lesion is highly vascularized and heterogenous. A mix of multifocal hyperechoic patches and hypoechoic nodules is seen. Anechoic areas indicate multifocal tumoral necrosis.

References:

Billir BJ. Teaching T cells to target tumors: towards the design of more effective cancer vaccines. Proceedings from the American College of Veterinary Internal Medicine Forum, Denver, CO, June 15-18, 2011.



PATIENT

Leroy Oliver

Biller BJ, Guth A, Burton JH, Dow SW. Decreased ratio of CD8+ T cells to regulatory T cells associated with decreased survival in dogs with osteosarcoma. *J Vet Intern Med* 2010;24(5):1118-23.

SPECIES

Canine

Elmslie RE, Glawe P, Dow SW. Metronomic therapy with cyclophosphamide and piroxicam effectively delays tumor recurrence in dogs with incompletely resected soft tissue sarcomas. *J Vet Intern Med* 2008;22(6):1373-79.

BREED

German Shorthair
Pointer

Lana S, U'Ren L, Plaza S, et al. Continuous low-dose oral chemotherapy for adjuvant therapy of splenic hemangiosarcoma in dogs. *J Vet Intern Med* 2007;21(4):764-69.

SEX

Neutered male

Milner RJ. Do NSAIDs make a difference in cancer? Proceedings from the American College of Veterinary Internal Medicine Forum, Denver, CO, June 15-18, 2011.

AGE

13 years

WEIGHT

65 lbs

INTERPRETED BY

Eric Lindquist, DMV
DABVP, Cert. IVUSS

IMAGING PERFORMED BY

Dr. Carter

HOSPITAL NAME

Willamette VH

REFERRING VET

Dr. Porter

INVOICE

91225

DATE

8/13/21