



**PATIENT PRESENTING CLINICAL SIGNS**

Gus Doyle Elevated liver enzymes. Hx FIV+, hx of mast cell skin mass, removed.

**ULTRASONOGRAPHIC EXAMINATION OF THE ABDOMEN**

**SPECIES**  
*Urinary System*

Feline

The **urinary bladder**, trigone, and pelvic urethra presented normal thicknesses and normal tone. The ureters were not visible which is normal. No uroliths or sediment were visualized and anechoic urine was present. No evidence of inflammatory or neoplastic changes were noted. Ureteral papillae were normal.

**BREED**

DSH

The **kidneys** revealed largely normal size and structure, corticomedullary definition and ratio (cortex 1/3 of medulla) were essentially maintained with some age-related loss of curvilinear patterns regarding the capsule and C/M junction. The cortices presented largely uniform texture with some increased echogenicity expected for his age patient. Medullary structure differed distinctly from that of the cortex and no evidence of pelvic dilation was present. The left kidney measured 3.5 cm. The right kidney measured 4.4 cm.

**SEX**

Neutered Male

**AGE**

12 Years

*Adrenal Glands*

Both **adrenal glands** were visualized and recognized as having normal shape, size, position and echogenicity for this breed. The phrenic vasculature, glandular echogenicity and detail were unremarkable. Capsule, cortex, and medullary definition were normal for this age patient. The right adrenal gland measured 0.4 cm. The left adrenal gland measured 0.3 cm.

**INTERPRETED BY**

Eric Lindquist, DMV  
DABVP, Cert. IVUSS

*Spleen*

The **spleen** presented a smooth homogeneous parenchyma hyperechoic to liver and renal cortical parenchyma. The capsule was smooth without noticeable expansion or deviation from within the spleen or adjacent pathology. The splenic vasculature demonstrated normal volume without signs of congestion or thrombosis. No sonographic evidence of acute or chronic inflammatory, neoplastic, or infarctual changes were noted.

**IMAGING PERFORMED BY**

Eric Lindquist, DMV  
DABVP, Cert. IVUSS

*Liver*

The **liver** was diffusely hyperechoic to falciform fat with coarse architecture. The gallbladder and common bile duct were normal. Occasional hypoechoic nodule noted, non-disruptive.

**HOSPITAL NAME**

Franklin Lakes AH

*Gastrointestinal*

**REFERRING VET**

Dr. Onesios

Examination of the **gastrointestinal tract** revealed a stomach and intestine free of stasis, of normal wall thickness, acceptable curvilinear mural detail, and peristaltic activity. Small and large intestine demonstrated normal luminal chyme and stool consistency respectively. No obstructive or overt infiltrative disease was noted. No associated abnormal lymphatic activity was noted.

**INVOICE**

24607

*Pancreas*

The base and limbs of the **pancreas** were observed to be largely isoechoic to surrounding omental fat. Some parenchymal remodeling, however, with mild deviation from curvilinear normalcy was observed. Pancreatic duct and capsular irregularities were present consistent with age related changes. If pain upon imaging (+ Murphy sign) was present or if the patient is focally painful in subxyphoid palpation then low-grade smoldering chronic pancreatitis should be suspected.

**DATE**

8/13/21



**PATIENT**      **ULTRASONOGRAPHIC FINDINGS**

Gus Doyle

- Mild chronic pancreatic changes
- Inflammatory hepatopathy liver pattern with minor nodules

**SPECIES**      **INTERPRETATION OF THE FINDINGS & FURTHER RECOMMENDATIONS**

Feline

Ultrasound guided FNA of the liver performed without complication. Management should be based on inflammatory cell type. Very minor potential for underlying neoplasia.

**BREED**

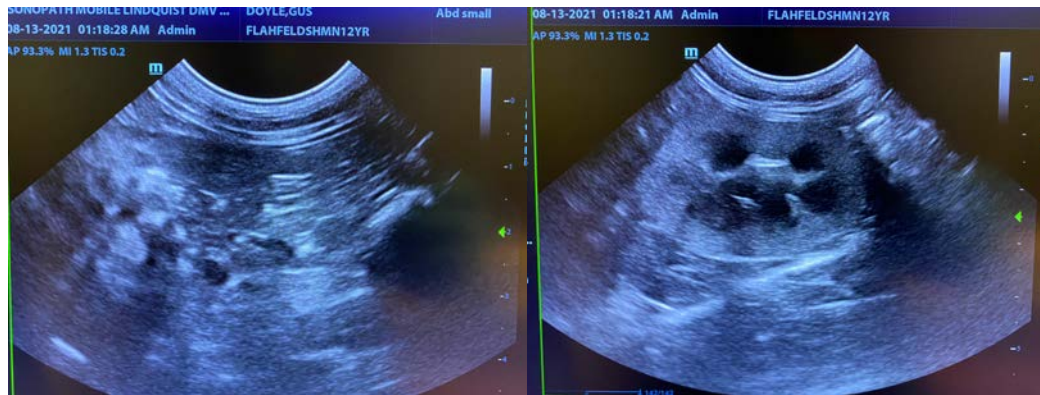
DSH

**SEX**

Neutered Male

**AGE**

12 Years



**INTERPRETED BY**

Eric Lindquist, DMV  
DABVP, Cert. IVUSS

**IMAGING PERFORMED BY**

Eric Lindquist, DMV  
DABVP, Cert. IVUSS

**HOSPITAL NAME**

Franklin Lakes AH

**REFERRING VET**

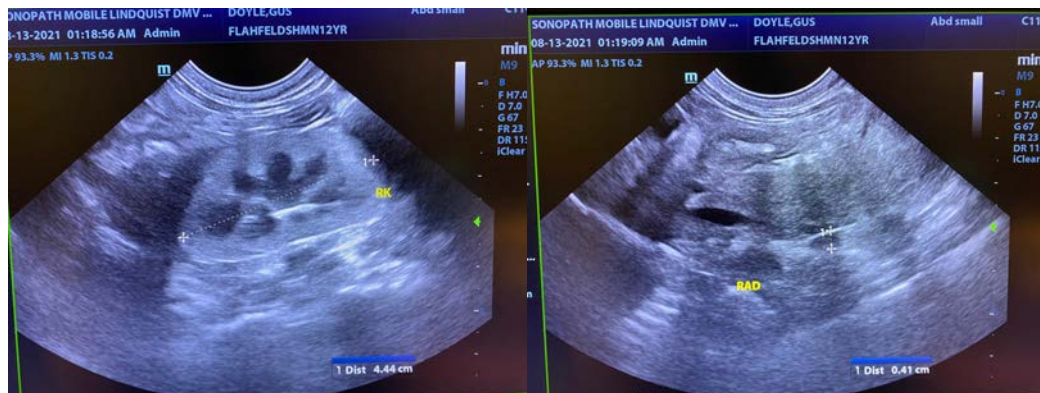
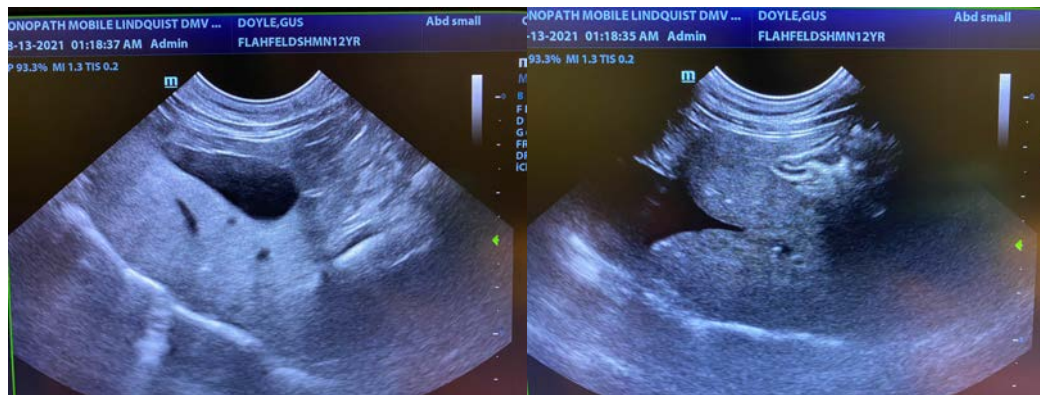
Dr. Onesios

**INVOICE**

24607

**DATE**

8/13/21





**PATIENT**

Gus Doyle

**SPECIES**

Feline

**BREED**

DSH

**SEX**

Neutered Male

**AGE**

12 Years

**INTERPRETED BY**

Eric Lindquist, DMV  
DABVP, Cert. IVUSS

**IMAGING PERFORMED BY**

Eric Lindquist, DMV  
DABVP, Cert. IVUSS

**HOSPITAL NAME**

Franklin Lakes AH

**REFERRING VET**

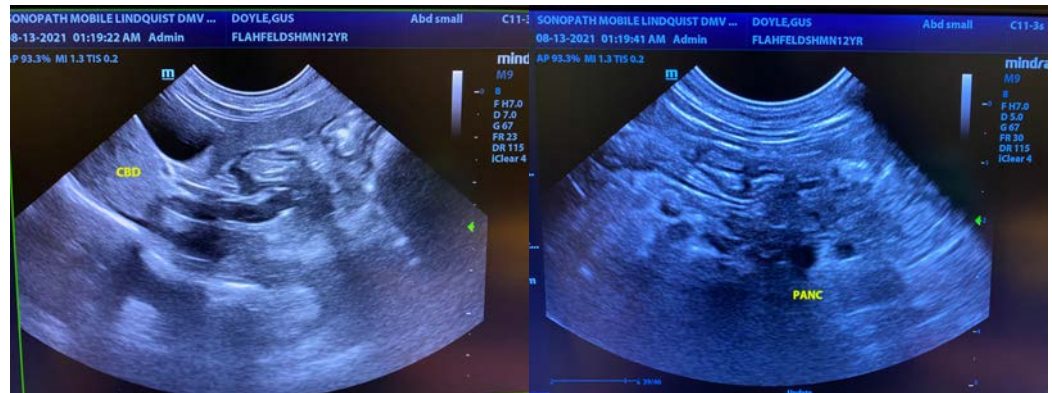
Dr. Onesios

**INVOICE**

24607

**DATE**

8/13/21



The information and recommendations provided are based on the images presented by the referring veterinarian. No evaluation can be communicated regarding pathology that was not visible in the image/video clips provided.

Thank you for this referral. If the clinical or image interpretation does not parallel your findings or if I can be of any further assistance please contact me.

**Eric Lindquist**, DMV, DABVP, Cert. IVUSS, CEO of SonoPath.com  
Info@SonoPath.com