



**PATIENT PRESENTING CLINICAL SIGNS**

Cheyenne Anderson Low glucose, ADR, weight loss. Possible abdominal pain. Hx of chemodectoma.

**ULTRASONOGRAPHIC EXAMINATION OF THE ABDOMEN**

**SPECIES**  
*Urinary System*

Canine

The **urinary bladder**, trigone, and pelvic urethra presented normal thicknesses and normal tone. The ureters were not visible which is normal. No uroliths or sediment were visualized and anechoic urine was present. No evidence of inflammatory or neoplastic changes were noted. Ureteral papillae were normal. The pelvic urethra was imaged 3.0 cm beyond the cystourethral junction.

**BREED**

Pit Bull X

The **kidneys** revealed normal size and structure, corticomedullary definition and ratio for this age. The cortices presented largely uniform texture with normal echogenic relationship to liver and spleen. Medullary structure differed distinctly from the cortex and no evidence of pelvic dilation was present. The capsules were acceptably uniform without significant irregularities. The left kidney measured 7.05 cm. The right kidney measured 7.61 cm.

**SEX**

Spayed Female

**Adrenal Glands**

**AGE**

9 Years

Both **adrenal glands** were visualized and recognized as having normal shape, size, position and echogenicity for this breed. The phrenic vasculature, glandular echogenicity and detail were unremarkable. Capsule, cortex, and medullary definition were normal for this age patient. The left adrenal gland measured 2.62 cm x 0.54 cm. The right adrenal gland measured 2.38 cm x 1.4 cm at the cranial pole and 0.88 cm at the caudal pole.

**INTERPRETED BY**

Eric Lindquist, DMV  
DABVP, Cert. IVUSS

**Spleen**

**IMAGING PERFORMED BY**

Eric Lindquist, DMV  
DABVP, Cert. IVUSS

The **spleen** presented a smooth homogeneous parenchyma hyperechoic to liver and renal cortical parenchyma. The capsule was smooth without noticeable expansion or deviation from within the spleen or adjacent pathology. The splenic vasculature demonstrated normal volume without signs of congestion or thrombosis. No sonographic evidence of acute or chronic inflammatory, neoplastic, or infarctual changes were noted.

**HOSPITAL NAME**

Bergen County VC

**Liver**

**REFERRING VET**

Dr. Shiffman

The **liver** images from right and left intercostal as well as subcostal views revealed subjectively normal liver size, contour, and structure. Some age-related parenchymal remodeling was noted but likely not clinically significant at this time. Occasional hypoechoic, non-disruptive nodular change noted. Vascular and biliary tracts were of normal volume and no evidence of congestion was noted. The gallbladder presented some dependent debris with essentially normal contour. The cystic and common bile ducts were normal. No overt evidence of active inflammatory, infiltrative or regenerative pathology was noted but should be paired with current or past LE elevations regarding any clinical significance to this presentation. The hepatic lymph nodes were unremarkable.

**INVOICE**

24604

**Gastrointestinal**

**DATE**

8/13/21

Examination of the **gastrointestinal tract** revealed a stomach and intestine free of stasis, of normal wall thickness, acceptable curvilinear mural detail, and peristaltic activity. Small and large intestine demonstrated normal luminal chyme and stool consistency respectively. No obstructive or overt infiltrative disease was noted. Mesenteric lymph nodes were enlarged, rounded and hypoechoic, measuring 2.5 cm and 2.2 cm. Ultrasound guided FNA warranted to assess for metastatic disease.



**PATIENT** *Pancreas*

Cheyenne Anderson

The base and limbs of the **pancreas** were observed to be largely isoechoic to surrounding omental fat. Pancreatic duct and capsular contour were acceptably normal and parenchyma respected normal curvilinear patterns. No overt evidence of active inflammatory or neoplastic disease was noted.

**SPECIES**

Canine

**ULTRASONOGRAPHIC FINDINGS**

- Mesenteric lymphadenopathy – concern for metastatic insulinoma, primary insulinoma not noted.
- Occasional nodular hepatic changes

**BREED**

Pit Bull X

**INTERPRETATION OF THE FINDINGS & FURTHER RECOMMENDATIONS**

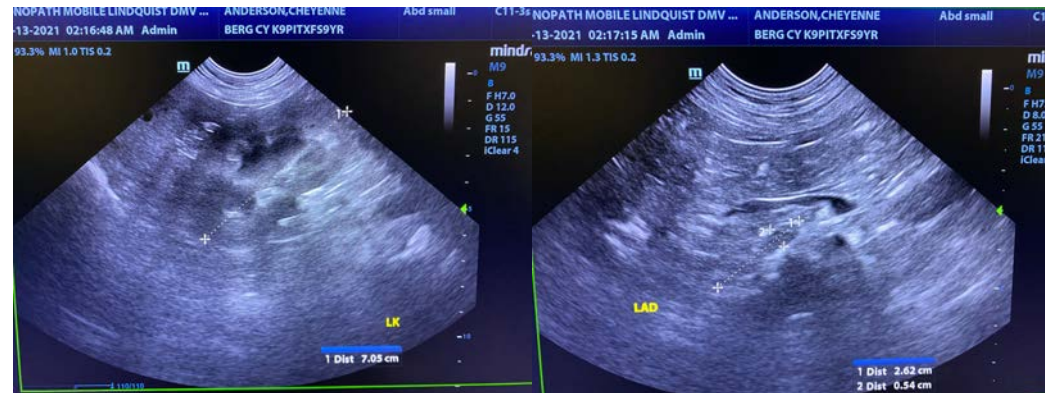**SEX**

The nodular changes in the liver could represent metastatic disease, yet most likely related to nodular hyperplasia. Insulin/glucose ratio warranted. FNA of a mesenteric lymph node recommended.

Spayed Female

**AGE**

9 Years



**INTERPRETED BY**

Eric Lindquist, DMV  
DABVP, Cert. IVUSS

**IMAGING PERFORMED BY**

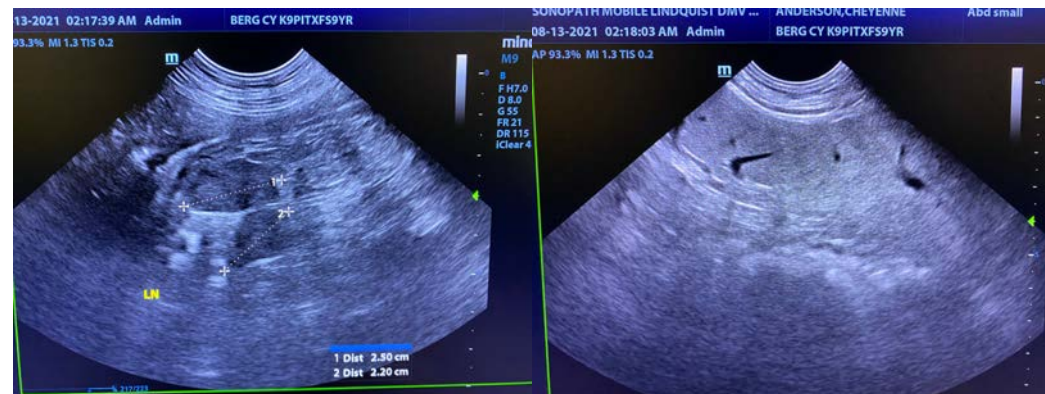
Eric Lindquist, DMV  
DABVP, Cert. IVUSS

**HOSPITAL NAME**

Bergen County VC

**REFERRING VET**

Dr. Shiffman

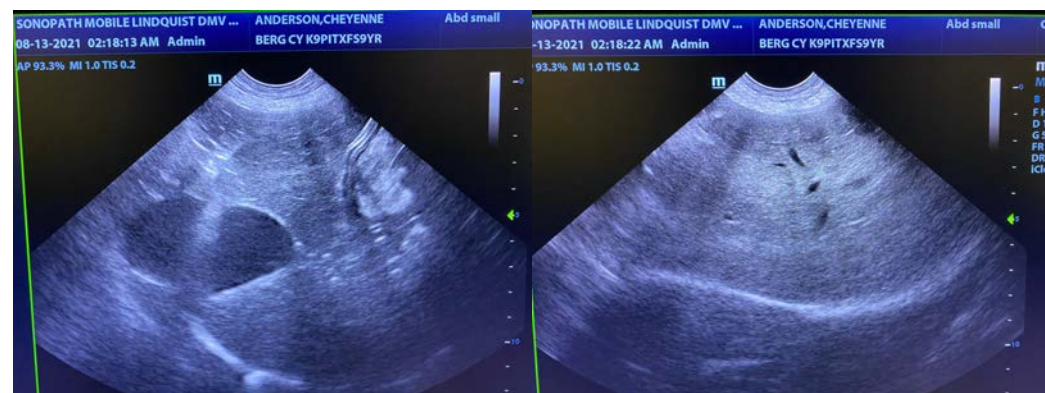


**INVOICE**

24604

**DATE**

8/13/21





**PATIENT**

Cheyenne Anderson

**SPECIES**

Canine

**BREED**

Pit Bull X

**SEX**

Spayed Female

**AGE**

9 Years

**INTERPRETED BY**

Eric Lindquist, DMV  
DABVP, Cert. IVUSS

**IMAGING PERFORMED BY**

Eric Lindquist, DMV  
DABVP, Cert. IVUSS

**HOSPITAL NAME**

Bergen County VC

**REFERRING VET**

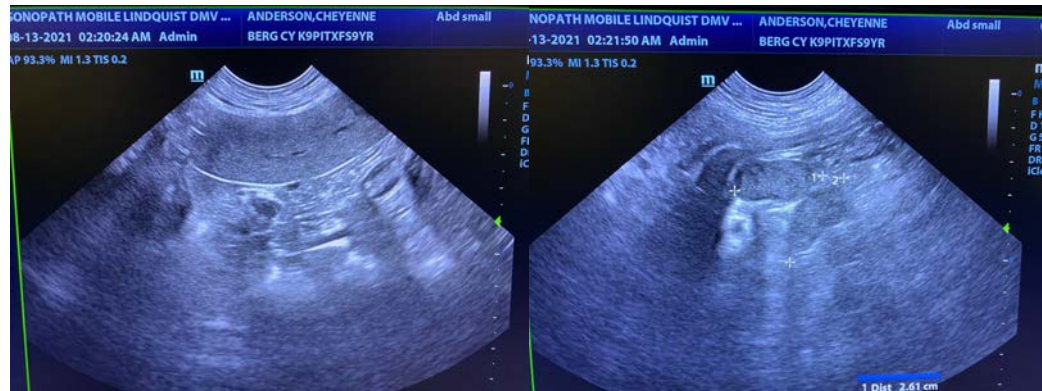
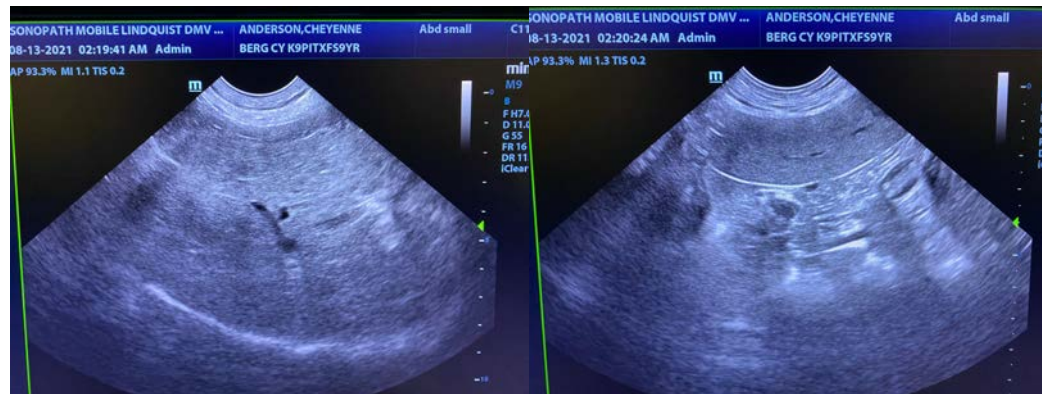
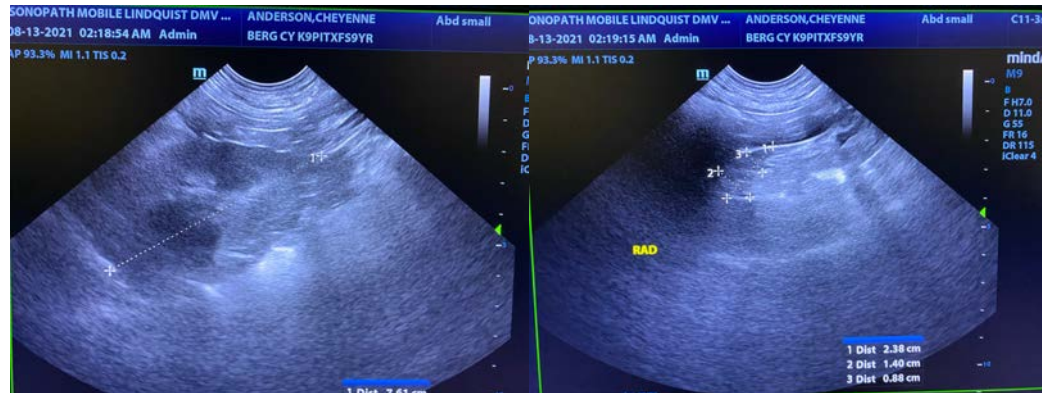
Dr. Shiffman

**INVOICE**

24604

**DATE**

8/13/21



The information and recommendations provided are based on the images presented by the referring veterinarian. No evaluation can be communicated regarding pathology that was not visible in the image/video clips provided.

Thank you for this referral. If the clinical or image interpretation does not parallel your findings or if I can be of any further assistance please contact me.

**Eric Lindquist**, DMV, DABVP, Cert. IVUSS, CEO of SonoPath.com  
Info@SonoPath.com