



PATIENT

Rosie Wyles

SPECIES

Canine

BREED

Miniature Dachshund

SEX

Spayed Female

AGE

13 Years 6 Months

WEIGHT

20 Pounds

INTERPRETED BY

Eric Lindquist, DMV
DABVP, Cert. IVUSS

IMAGING PERFORMED BY

Leon Anderson, DVM

HOSPITAL NAME

Elizabeth AH

REFERRING VET

Leon Anderson, DVM

INVOICE

16841

DATE

8/12/22

PRESENTING CLINICAL SIGNS

History: Murmur discovered on physical exam in May. Grade 4 Dental Disease needs addressed.

Abnormal PE/Chem/CBC/UA Results: PE: Grade III/VI systolic cardiac murmur. BCS 4/5. Grade 4 Dental disease. Subcu mass on tail and skin tag on elbow. No recent labs.

ULTRASONOGRAPHIC EXAMINATION OF THE HEART

CANINE CARDIAC PARAMETERS	MR VMAX (m/s)	TR VMAX (m/s)	LA/AO (Boon method)	LA/AO (Heart Base; Swe)	FS (%)	EF (%)	EPSS (cm)
NORMAL PARAMETER	4.5-5.5	<2.7	1.3	<1.3	28-40	40-100	<0.6
PATIENT	5.77	--	1.3	1.3	59	91	NM
CANINE CARDIAC PARAMETERS	HR (BPM)	AV VMAX (m/s)	PV MAX (m/s)	BODY WEIGHT (kg)	LA 2D short axis Base view (cm)	LVIDd Avg; 2D and m-mode short axis (cm)	LVIDs Avg; 2D and m-mode short axis (cm)
NORMAL PARAMETER	50-100	0.7-1.7	0.7-1.6				
PATIENT	--	1.36	.87	--	3.1	1.87	--

Cardiac Presentation

The echocardiogram in this patient demonstrated normal **left atrial** size based on 3 different LA measurement methods. Chamber volumes and echogenicity were normal. Mitral insufficiency jet appeared to be moderate. Doppler indicated measurable insufficiency. The **left ventricle** presented thicknesses with linear contour and was not dilated nor restricted. The **myocardium** presented normal echogenicity without subjective evidence of significant fibrotic or ischemic disease.

Contractility of the ventricular walls was adequate and in normal range for this patient evidenced by the fractional shortening measurement and subjective evaluation of the different regions of the myocardium. The **left ventricular outflow** tract demonstrated normal laminar flow and subjective structural integrity. The **right atrium** and auricle revealed normal size, structure and content. No evidence of masses was noted or chamber overload. **Tricuspid** valvular assessment demonstrated adequate linear morphology. The **right ventricle** was of normal size (1/3 diameter of LV), chordae structure, myocardial echogenicity and thickness. **Pulmonic** tract assessment revealed normal valve structure, laminar flow, and diameter (approx.1:1 pa/ao ratio). No visible **pericardial** or free pleura fluid was noted. No echographically detectable evidence of infiltrative disease was visible. The cranial **mediastinum and pericardial regions** were free of masses in the visible window.

ULTRASONOGRAPHIC FINDINGS

- Stable stage B-1 valvular disease

INTERPRETATION OF THE FINDINGS & FURTHER RECOMMENDATIONS



PATIENT

Rosie Wyles

SPECIES

Canine

No overt contraindication to anesthetic procedure. The heart is stable without clinical disease. No overt contraindication for anesthesia of brief to moderate duration. I suggest Torbutrol premed, Propofol induction, Isoflo maintenance or similar protocol if anesthesia is desired. Blood pressure recommended if not already performed and target white coat negative systolic pressure of < 160 mmHg. If higher than this ACE-inhibitor is suggested to reach this level. Recheck echocardiogram is recommended in 6 months, earlier if murmur grade increases or clinical signs initiate.

BREED

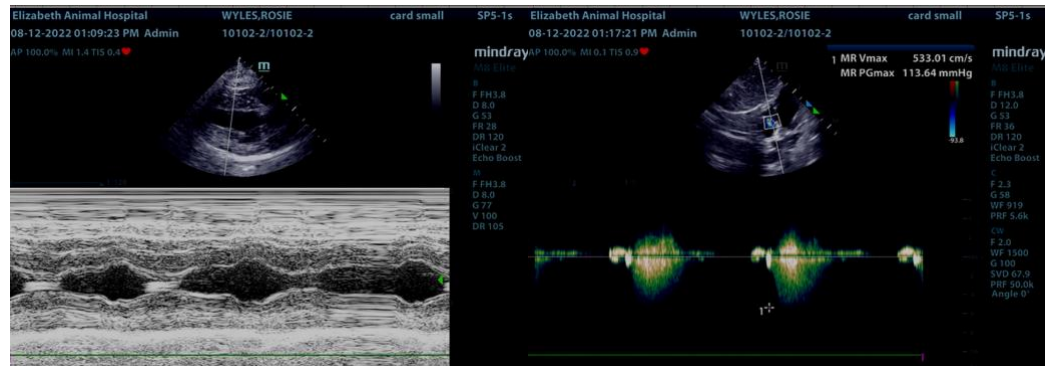
Miniature Dachshund

SEX

Spayed Female

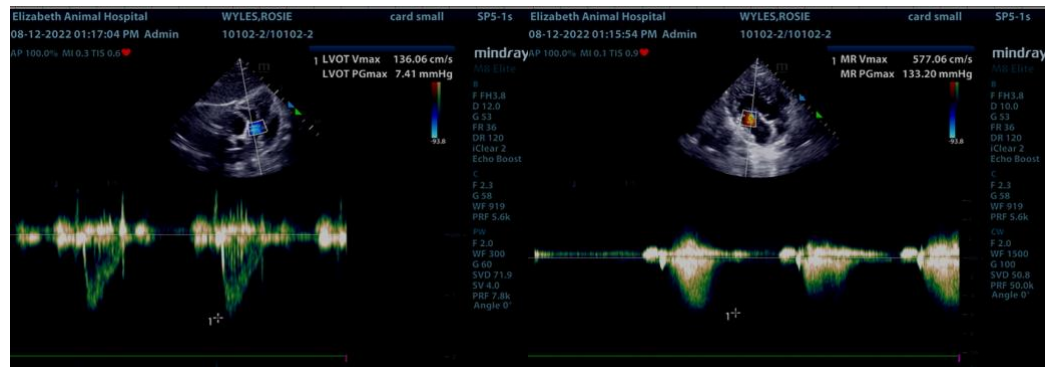
AGE

13 Years 6 Months



WEIGHT

20 Pounds



INTERPRETED BY

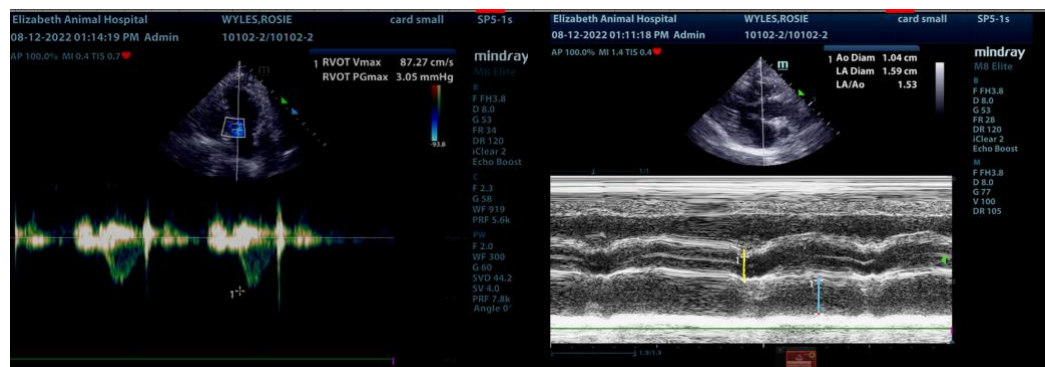
Eric Lindquist, DMV
DABVP, Cert. IVUSS

IMAGING PERFORMED BY

Leon Anderson, DVM

HOSPITAL NAME

Elizabeth AH



REFERRING VET

Leon Anderson, DVM

INVOICE

16841

DATE

8/12/22



PATIENT

Rosie Wyles

SPECIES

Canine

BREED

Miniature Dachshund

SEX

Spayed Female

AGE

13 Years 6 Months

WEIGHT

20 Pounds

INTERPRETED BY

Eric Lindquist, DMV
DABVP, Cert. IVUSS

IMAGING PERFORMED BY

Leon Anderson, DVM

HOSPITAL NAME

Elizabeth AH

REFERRING VET

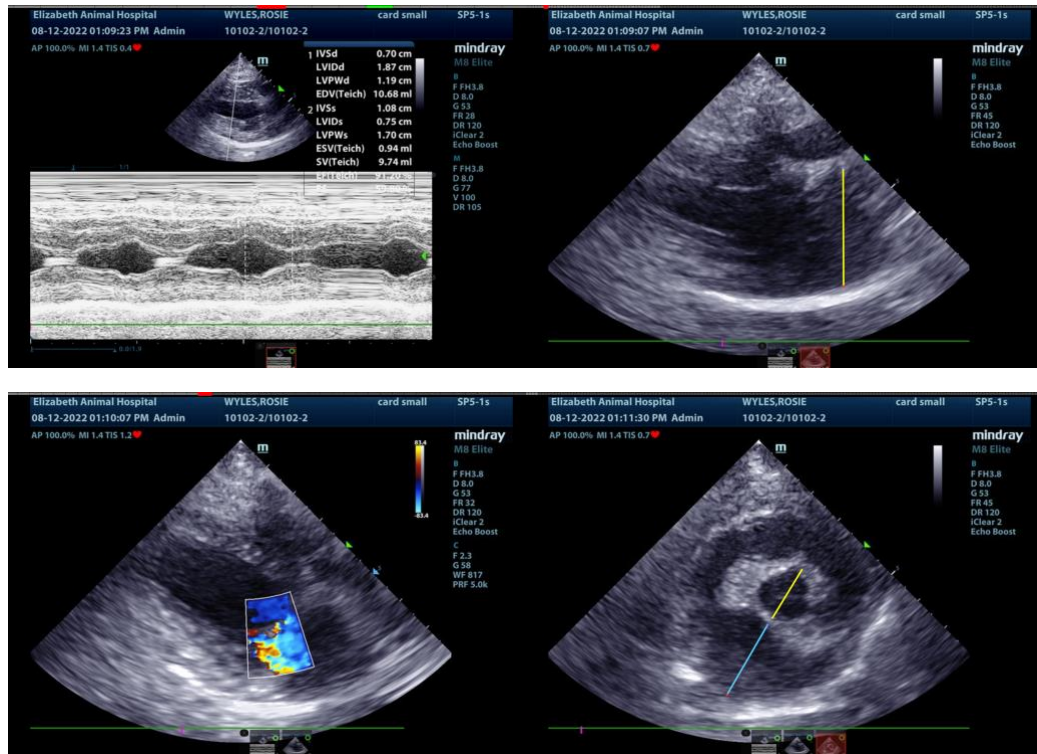
Leon Anderson, DVM

INVOICE

16841

DATE

8/12/22



The information and recommendations provided are based on the images presented by the referring veterinarian. No evaluation can be communicated regarding pathology that was not visible in the image/video clips provided.

Thank you for this referral. If the clinical or image interpretation does not parallel your findings or if I can be of any further assistance please contact me.

Eric Lindquist, DMV, DABVP, Cert. IVUSS, CEO of SonoPath.com
info@SonoPath.com