



## PATIENT PRESENTING CLINICAL SIGNS

Kanuk Nemke Grade 2/6 systolic mummur. PMI Mitral region.  
Abnormal PE/Chem/CBC/UA Results: Cardiopet proBNP 1638 Heart Rate and Respiratory Rates  
HR 108 RR24 Blood Pressure Measurements 139/99 (112) with a 7-13cm Cuff on LRL

## SPECIES

Canine

## ULTRASONOGRAPHIC EXAMINATION OF THE HEART

## BREED

Dalmatian

## SEX

Neutered Male

## AGE

10 Years

## WEIGHT

64.3 Pounds

## INTERPRETED BY

Eric Lindquist, DMV

DABVP, Cert. IVUSS

## IMAGING PERFORMED BY

Sara Hansen

## HOSPITAL NAME

Community Vet Center

## REFERRING VET

Dr. Titterington

## INVOICE

40404

## DATE

8/12/22

CANINE CARDIAC PARAMETERS	MR VMAX (m/s)	TR VMAX (m/s)	LA/AO (Boon method)	LA/AO (Heart Base; Swe)	FS (%)	EF (%)	EPSS (cm)
NORMAL PARAMETER	4.5-5.5	<2.7	1.3	<1.6	28-40	40-100	<0.6
PATIENT	6.0		1.2	1.47	30	--	0.4
CANINE CARDIAC PARAMETERS	HR (BPM)	AV VMAX (m/s)	PV MAX (m/s)	BODY WEIGHT (kg)	LA 2D short axis Base view (cm)	LVIDd Avg; 2D and m-mode short axis (cm)	LVIDs Avg; 2D and m-mode short axis (cm)
NORMAL PARAMETER	50-100	0.7-1.7	0.7-1.6	BELOW	BELOW	BELOW	BELOW
PATIENT	--	1.8	0.88		3.5	4.9	

## Cardiac Presentation

The echocardiogram in this patient demonstrated normal **left atrial** size based on 3 different LA measurement methods. Chamber volumes and echogenicity were normal. The cranial and caudal **mitral** valve leaflets presented vegetative thickening consistent with endocardiosis. Doppler indicated measurable insufficiency. The **left ventricle** presented thicknesses with linear contour and was not dilated nor restricted. The **myocardium** presented normal echogenicity without subjective evidence of significant fibrotic or ischemic disease. **Contractility** of the ventricular walls was adequate and in normal range for this patient evidenced by the fractional shortening measurement and subjective evaluation of the different regions of the myocardium. The **left ventricular outflow** tract demonstrated normal laminar flow and subjective structural integrity. The **right atrium** and auricle revealed normal size, structure and content. No evidence of masses was noted or chamber overload. **Tricuspid** valvular assessment demonstrated adequate linear morphology. The **right ventricle** was of normal size (1/3 diameter of LV), chordae structure, myocardial echogenicity and thickness. **Pulmonic** tract assessment revealed normal valve structure, laminar flow, and diameter (approx.1:1 pa/ao ratio). No visible **pericardial** or free pleura fluid was noted. No echographically detectable evidence of infiltrative disease was visible. The cranial **mediastinum** and **pericardial regions** were free of masses in the visible window.

## ULTRASONOGRAPHIC FINDINGS

- Stage B1 valvular disease



**PATIENT**

Kanuk Nemke

**SPECIES**

Canine

**BREED**

Dalmatian

**SEX**

Neutered Male

**AGE**

10 Years

**WEIGHT**

64.3 Pounds

**INTERPRETATION OF THE FINDINGS & FURTHER RECOMMENDATIONS**

No significant volume overload.

The heart is stable without clinical disease. No overt contraindication for anesthesia of brief to moderate duration. I suggest Torbutrol premed, Propofol induction, Isoflo maintenance or similar protocol if anesthesia is desired. Blood pressure recommended if not already performed and target white coat negative systolic pressure of < 160 mmHg. If higher than this ACE-inhibitor is suggested to reach this level. Recheck echocardiogram is recommended in 6 months, earlier if murmur grade increases or clinical signs initiate.

**INTERPRETED BY**

Eric Lindquist, DMV  
DABVP, Cert. IVUSS

**IMAGING PERFORMED BY**

Sara Hansen

**HOSPITAL NAME**

Community Vet Center

**REFERRING VET**

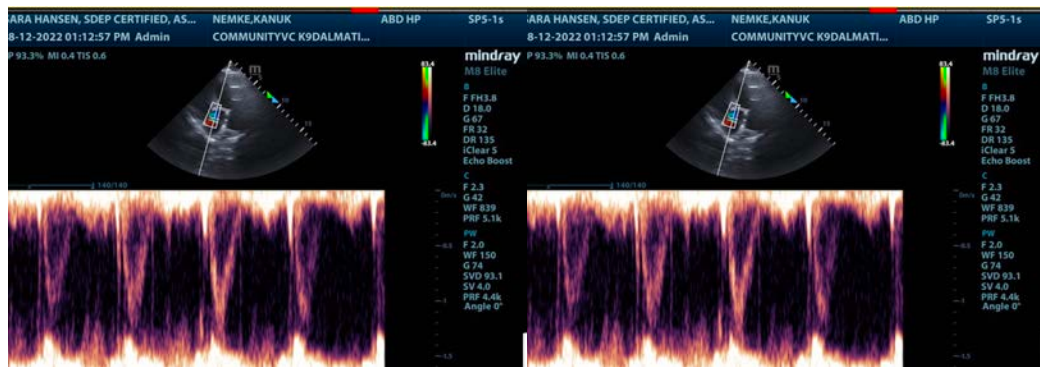
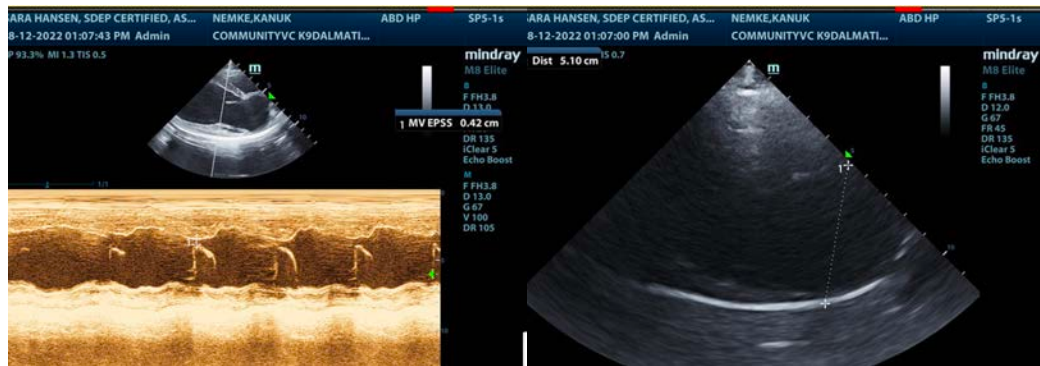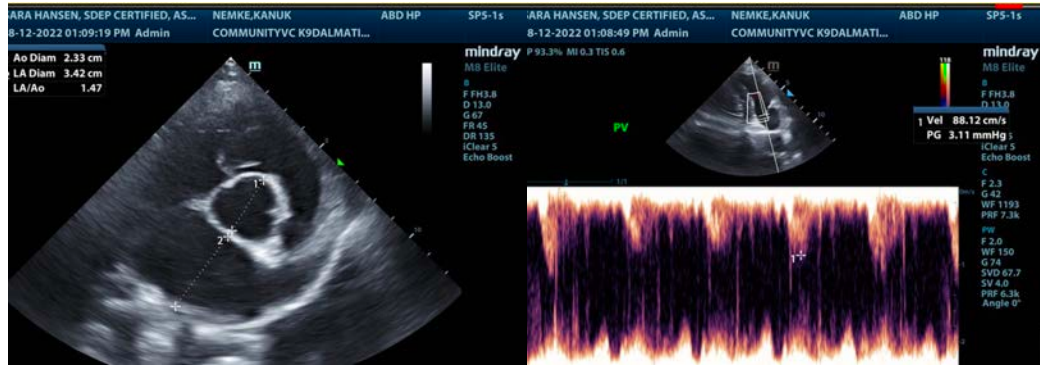
Dr. Titterington

**INVOICE**

40404

**DATE**

8/12/22





**PATIENT**

Kanuk Nemke

**SPECIES**

Canine

**BREED**

Dalmatian

**SEX**

Neutered Male

**AGE**

10 Years

**WEIGHT**

64.3 Pounds

**INTERPRETED BY**

Eric Lindquist, DMV  
DABVP, Cert. IVUSS

**IMAGING PERFORMED BY**

Sara Hansen

**HOSPITAL NAME**

Community Vet Center

**REFERRING VET**

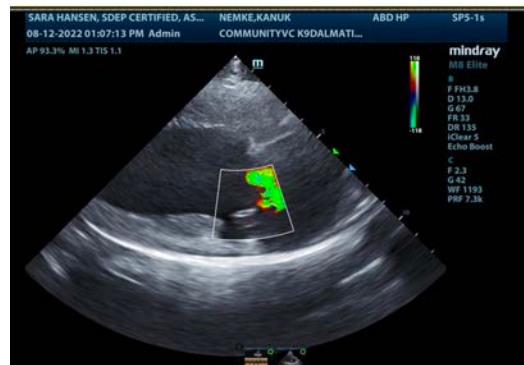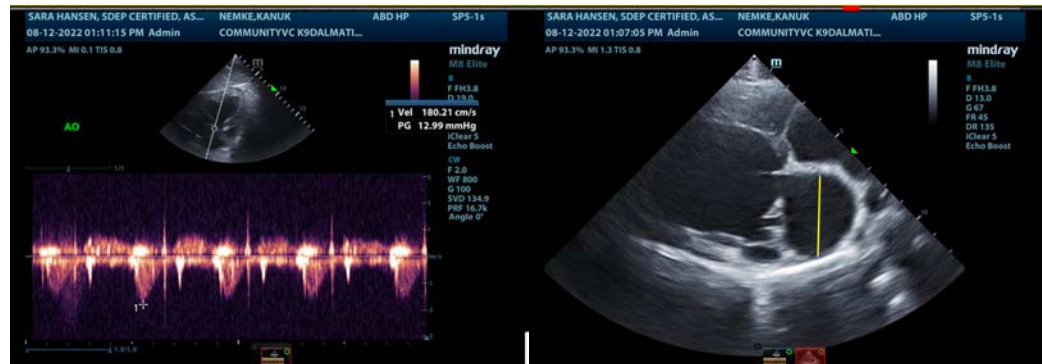
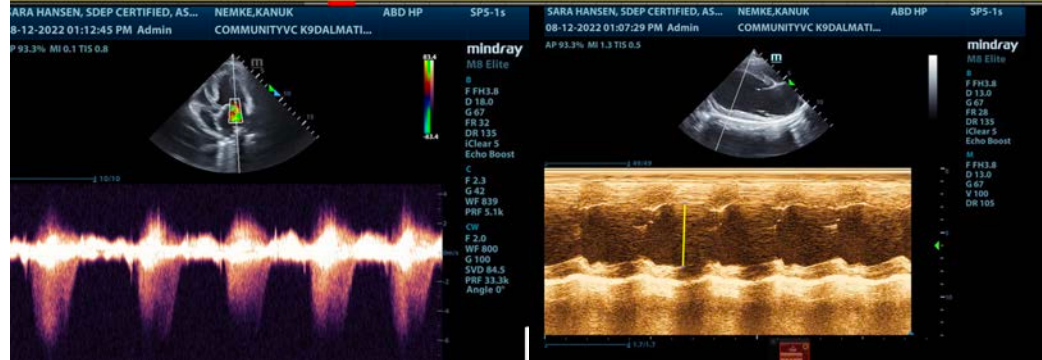
Dr. Titterington

**INVOICE**

40404

**DATE**

8/12/22



The information and recommendations provided are based on the images presented by the referring veterinarian/sonographer. No evaluation can be communicated regarding pathology that was not visible in the image/video clips provided.

Thank you for this referral. If the clinical or image interpretation does not parallel your findings or if I can be of any further assistance please contact me.

Eric Lindquist, DMV, DABVP, Cert. IVUSS, CEO of SonoPath.com

[info@SonoPath.com](mailto:info@SonoPath.com)