



**PATIENT**

Cy Scher

**PRESENTING CLINICAL SIGNS**

Bloody stool, weight loss, bloodwork unremarkable.

**SPECIES**

Canine

**ULTRASONOGRAPHIC EXAMINATION OF THE ABDOMEN**

**Urinary System**

The **urinary bladder**, trigone, and pelvic urethra presented normal thicknesses and normal tone. The ureters were not visible which is normal. No uroliths or sediment were visualized and anechoic urine was present. No evidence of inflammatory or neoplastic changes were noted. Ureteral papillae were normal.

**BREED**

Havanese

The **kidneys** revealed largely normal size and structure, corticomedullary definition and ratio (cortex 1/3 of medulla) were essentially maintained with some age-related loss of curvilinear patterns regarding the capsule and C/M junction. The cortices presented largely uniform texture with some increased echogenicity expected for his age patient. Medullary structure differed distinctly from that of the cortex and no evidence of pelvic dilation was present. The left kidney measured 4.38 cm.

**SEX**

Neutered Male

**AGE**

2010

**Adrenal Glands**

Both **adrenal glands** were visualized and recognized as having normal shape, size, position and echogenicity for this breed. The phrenic vasculature, glandular echogenicity and detail were unremarkable. Capsule, cortex, and medullary definition were normal for this age patient. The left adrenal gland measured 0.50 cm. The right adrenal gland measured 0.80 cm at the cranial pole and 0.50 cm at the caudal pole.

**WEIGHT**

11.8 Pounds

**Spleen**

The **spleen** presented a smooth homogeneous parenchyma hyperechoic to liver and renal cortical parenchyma. The capsule was smooth without noticeable expansion or deviation from within the spleen or adjacent pathology. The splenic vasculature demonstrated normal volume without signs of congestion or thrombosis. No sonographic evidence of acute or chronic inflammatory, neoplastic, or infarctual changes were noted.

**INTERPRETED BY**

Eric Lindquist, DMV

DABVP, Cert. IVUSS

**IMAGING PERFORMED BY**

Eric Lindquist, DMV

DABVP, Cert. IVUSS

**HOSPITAL NAME**

Franklin Lakes AH

**Liver**

The **liver** images from right and left intercostal as well as subcostal views revealed subjectively normal liver size, contour, and structure. Some age-related parenchymal remodeling was noted but likely not clinically significant at this time. Vascular and biliary tracts were of normal volume and no evidence of congestion was noted. The gallbladder presented some dependent debris with essentially normal contour. The cystic and common bile ducts were normal. No overt evidence of active inflammatory, infiltrative or regenerative pathology was noted but should be paired with current or past LE elevations regarding any clinical significance to this presentation. The hepatic lymph nodes were unremarkable.

**Gastrointestinal**

The **stomach** was thickened at 1.12 cm with hypertrophied muscularis and echogenic mucosal remodeling. No overt neoplastic criteria present, yet could not completely rule it out. The small intestine was unremarkable. The colon was mildly thickened up to 5.0 mm. Increased submucosal echogenicity noted, consistent with chronic inflammation.

**REFERRING VET**

Dr. Hudson

**INVOICE**

40389

**DATE**

8/12/22



**PATIENT**

Cy Scher

**Pancreas**

The base and limbs of the **pancreas** were observed to be largely isoechoic to surrounding omental fat. Some parenchymal remodeling, however, with mild deviation from curvilinear normalcy was observed. Pancreatic duct and capsular irregularities were present consistent with age related changes. If pain upon imaging (+ Murphy sign) was present or if the patient is focally painful in subxyphoid palpation then low-grade smoldering chronic pancreatitis should be suspected.

**SPECIES**

Canine

**ULTRASONOGRAPHIC FINDINGS**

**BREED**

Havanese

- Gastric hypertrophy and colitis pattern
- Geriatric abdomen otherwise

**INTERPRETATION OF THE FINDINGS & FURTHER RECOMMENDATIONS**

**SEX**

Neutered Male

I recommend a fresh fecal smear and fecal floatation analysis. Hydrolyzed diet trial recommended. A clinical trial of the following may prove effective. Recheck sonogram in 10-14 days, earlier if clinical signs worsen. Gastroscopy/colonoscopy would be ideal in this patient.

**AGE**

2010

**Helicobacter/Gastritis protocol**

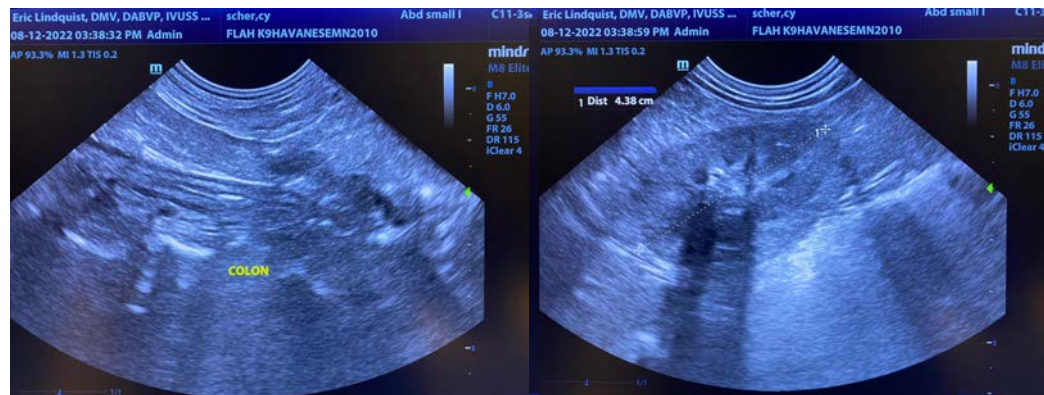
A clinical trial of **Zithromax** (Dogs: 5-10 mg/kg p.o. q24h. May increase dosing interval to q48h after 3-5 days of treatment), **Metronidazole** (10-20 mg/kg p.o. b.i.d.), **Pepcid** (0.5-1 mg/kg s.i.d.) and **Sucralfate** (0.5-2 g/dog PO) or **Omeprazole** (1 mg/kg p.o. s.i.d.) over the next 3 weeks along with a **novel-protein or hydrolyzed diet** with slurry feeding b.i.d./t.i.d. over the next 2-4 days and then increase to canned diet bid. Dry food should be avoided over the next 4 weeks. A recheck sonogram to assess GI improvement or progression would be ideal in 4 weeks.

**WEIGHT**

11.8 Pounds

**INTERPRETED BY**

Eric Lindquist, DMV  
DABVP, Cert. IVUSS

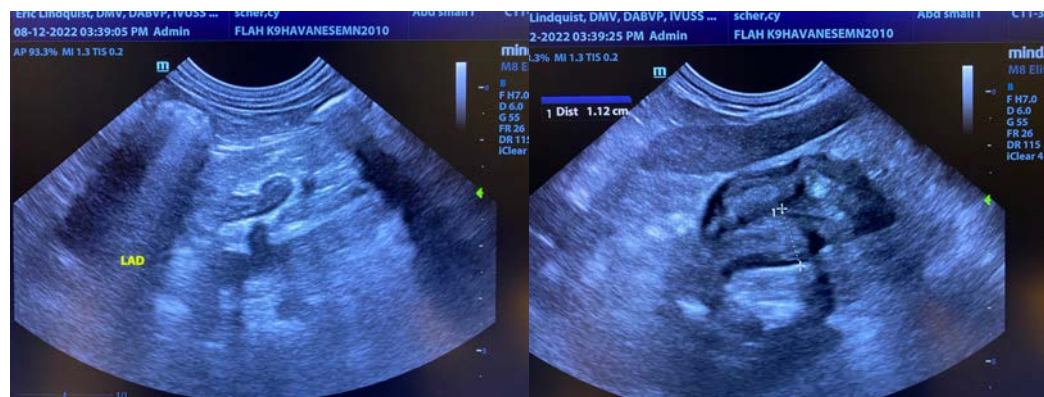


**IMAGING PERFORMED BY**

Eric Lindquist, DMV  
DABVP, Cert. IVUSS

**HOSPITAL NAME**

Franklin Lakes AH



**REFERRING VET**

Dr. Hudson

**INVOICE**

40389

**DATE**

8/12/22



**PATIENT**

Cy Scher

**SPECIES**

Canine

**BREED**

Havanese

**SEX**

Neutered Male

**AGE**

2010

**WEIGHT**

11.8 Pounds

**INTERPRETED BY**

Eric Lindquist, DMV  
DABVP, Cert. IVUSS

**IMAGING PERFORMED BY**

Eric Lindquist, DMV  
DABVP, Cert. IVUSS

**HOSPITAL NAME**

Franklin Lakes AH

**REFERRING VET**

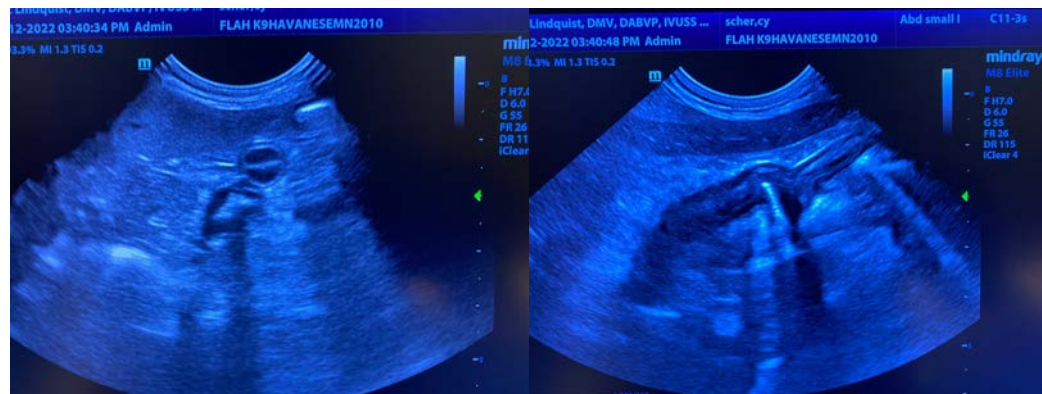
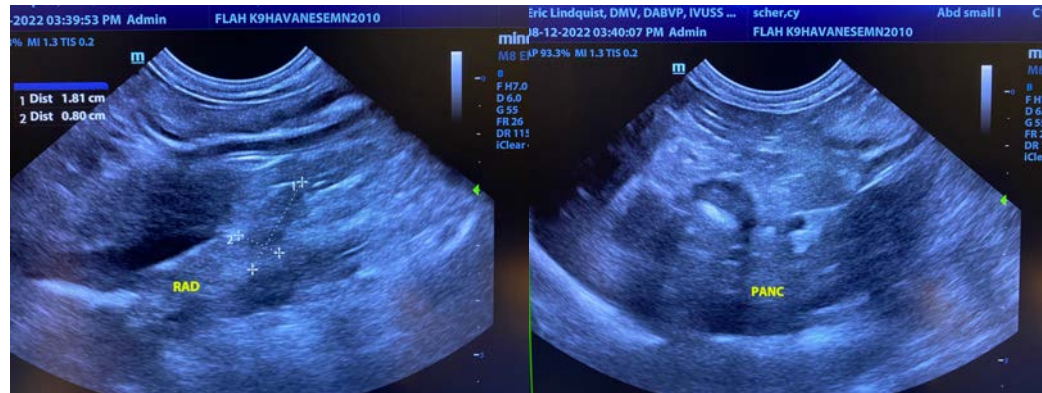
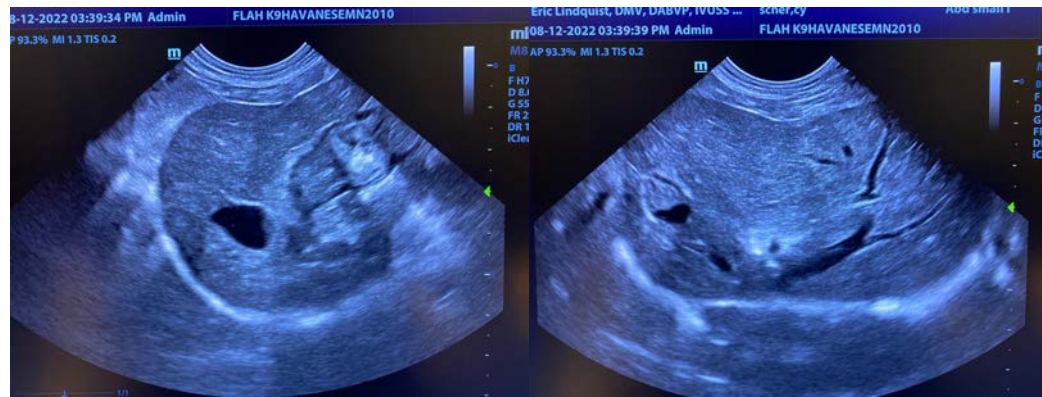
Dr. Hudson

**INVOICE**

40389

**DATE**

8/12/22



The information and recommendations provided are based on the images presented by the referring veterinarian/sonographer. No evaluation can be communicated regarding pathology that was not visible in the image/video clips provided.

Thank you for this referral. If the clinical or image interpretation does not parallel your findings or if I can be of any further assistance please contact me.

**Eric Lindquist, DMV, DABVP, Cert. IVUSS, CEO of SonoPath.com**

[info@SonoPath.com](mailto:info@SonoPath.com)