

PATIENT PRESENTING CLINICAL SIGNS

Charlie Drummond

Long standing hx of glaucoma and retinal disease.....congenital. OS...treating for glaucoma, OD not under treatment at this time. New,.... the past 2 wks OS appears red. Owners still feels he maybe slightly visual. Awaiting optho referral Exam: OS..non visual. Unable to visualize iris/pupil. Pressure 28-29mmhg. Exam is difficult with his movement. Sclera mildly to moderately injected. OD..pressure 10mg (not receiving meds). Dilated pupil present...? visual. Metacam, Latanoprost, Dorzolamide

SPECIES

Canine

BREED

Black Labrador

SEX

Neutered Male

AGE

2 Years

WEIGHT

38.3 kg

LIMITED ULTRASONOGRAPHIC EXAMINATION

Both eyes were imaged in this patient. However, patient movement was an issue, obscuring some peripheral views. However, video capture revealed normal left eye anterior chamber with slightly thickened lens. The posterior chamber presented a mild amount of suspended debris and thickened linear irregular tissue, consistent with retinal detachment. The optic nerve and peripheral tissue appeared unremarkable.

The right eye revealed normal anterior chamber, mildly thickened lens, and thin seagull sign, consistent with detached retina. The optic nerve was unremarkable. Posterior chamber fluid was slightly echogenic.

ULTRASONOGRAPHIC FINDINGS

- Bilateral detached retinas and lens thickening

INTERPRETATION OF THE FINDINGS & FURTHER RECOMMENDATIONS

Ophthalmology evaluation recommended. No evidence of neoplasia. However, a significant inflammatory component appears to be present in the posterior chamber of the left eye.

INTERPRETED BY

Eric Lindquist, DMV
DABVP, Cert. IVUSS

IMAGING PERFORMED BY

Crystal Hill

HOSPITAL NAME

Grand River VH

REFERRING VET

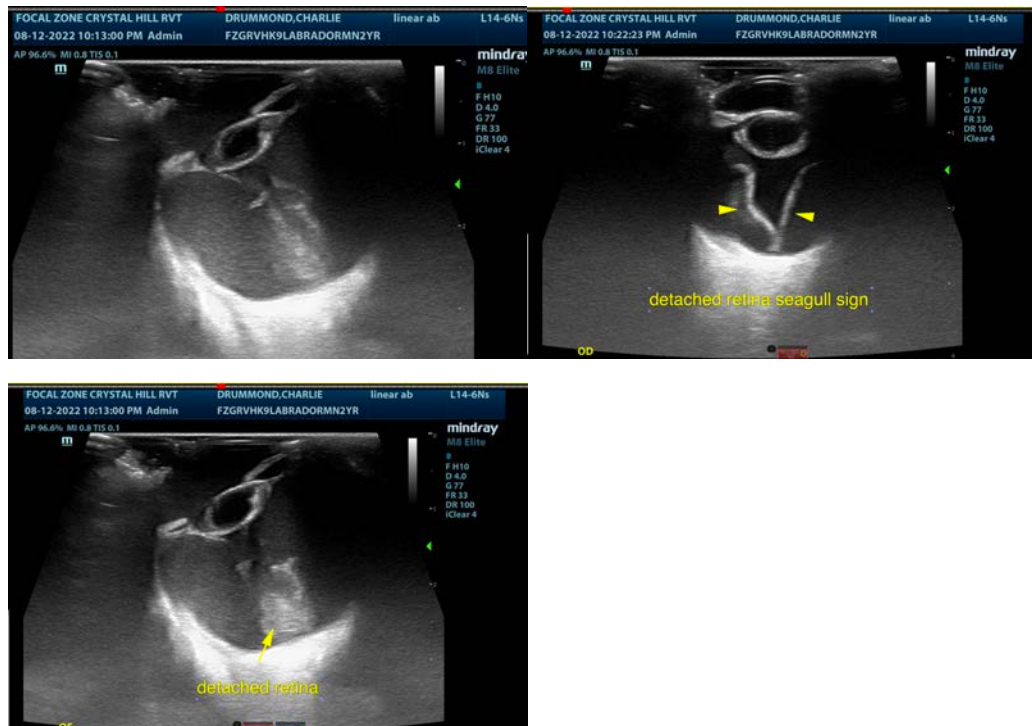Dr. Hornak

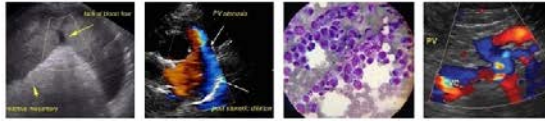
INVOICE

40401

DATE

8/12/22





PATIENT

Charlie Drummond

The information and recommendations provided are based on the images presented by the referring veterinarian/sonographer. No evaluation can be communicated regarding pathology that was not visible in the image/video clips provided.

SPECIES

Canine

Thank you for this referral. If the clinical or image interpretation does not parallel your findings or if I can be of any further assistance please contact me.

Eric Lindquist, DMV, DABVP, Cert. IVUSS, CEO of SonoPath.com

info@SonoPath.com

BREED

Black Labrador

SEX

Neutered Male

AGE

2 Years

WEIGHT

38.3 kg

INTERPRETED BY

Eric Lindquist, DMV

DABVP, Cert. IVUSS

IMAGING PERFORMED BY

Crystal Hill

HOSPITAL NAME

Grand River VH

REFERRING VET

Dr. Hornak

INVOICE

40401

DATE

8/12/22