



PATIENT PRESENTING CLINICAL SIGNS

Tori Petruska lyme dz hematuria intermittent diarrhea febrile

SPECIES ULTRASONOGRAPHIC EXAMINATION OF THE ABDOMEN

Canine Urinary System

The **urinary bladder**, trigone, and pelvic urethra presented normal thicknesses and normal tone. The ureters were not visible which is normal. No uroliths or sediment were visualized and anechoic urine was present. No evidence of inflammatory or neoplastic changes were noted. Ureteral papillae were normal. The pelvic urethra was imaged 3.0 cm beyond the cystourethral junction.

BREED

German Shepherd

SEX

Spayed Female

The **kidneys** revealed normal size and structure, corticomedullary definition and ratio for this age. The cortices presented largely uniform texture with normal echogenic relationship to liver and spleen. Medullary structure differed distinctly from the cortex and no evidence of pelvic dilation was present. The capsules were acceptably uniform without significant irregularities. The right kidney measured 5.89 cm. The left kidney measured 4.43 cm.

AGE

3 Years

Adrenal Glands

The regions of the **adrenal glands** were unremarkable.

WEIGHT

87.5

Spleen

The **spleen** presented a smooth homogeneous parenchyma hyperechoic to liver and renal cortical parenchyma. The capsule was smooth without noticeable expansion or deviation from within the spleen or adjacent pathology. The splenic vasculature demonstrated normal volume without signs of congestion or thrombosis. No sonographic evidence of acute or chronic inflammatory, neoplastic, or infarctual changes were noted. The spleen was folded upon itself cranially.

INTERPRETED BY

Eric Lindquist, DMV
DABVP, Cert. IVUSS

Liver

The **liver** images submitted revealed subjectively normal liver size, contour, and structure. Parenchymal echogenicity was naturally coarse and hypoechoic to the spleen. Vascular and biliary tracts were of normal volume with no evidence of congestion. The gallbladder presented acceptably thin walls with primarily anechoic content. The cystic and common bile ducts were normal. No pathological hepatic lymphadenopathy was evident. No overt structural evidence of inflammatory, infiltrative or regenerative pathology was evident.

IMAGING PERFORMED BY

Jenn

HOSPITAL NAME

Rockaway AH

Gastrointestinal

Examination of the **gastrointestinal tract** revealed minor fluid filled upper intestinal lumen with hyperperistalsis and colonic dilation with echogenic fluid and soft stool, consistent with resolving gastroenteritis.

REFERRING VET

Dr. Maniar

Pancreas

The base and limbs of the **pancreas** were observed to be largely isoechoic to surrounding omental fat. Pancreatic duct and capsular contour were acceptably normal and parenchyma respected normal curvilinear patterns. No overt evidence of active inflammatory or neoplastic disease was noted.

INVOICE

24578

ULTRASONOGRAPHIC FINDINGS

DATE

8/12/21

- Gastroenteritis/enterotoxin type presentation



PATIENT

Tori Petruska

SPECIES

Canine

BREED

German Shepherd

SEX

Spayed Female

AGE

3 Years

WEIGHT

87.5

INTERPRETED BY

Eric Lindquist, DMV
DABVP, Cert. IVUSS

IMAGING PERFORMED BY

Jenn

HOSPITAL NAME

Rockaway AH

REFERRING VET

Dr. Maniar

INVOICE

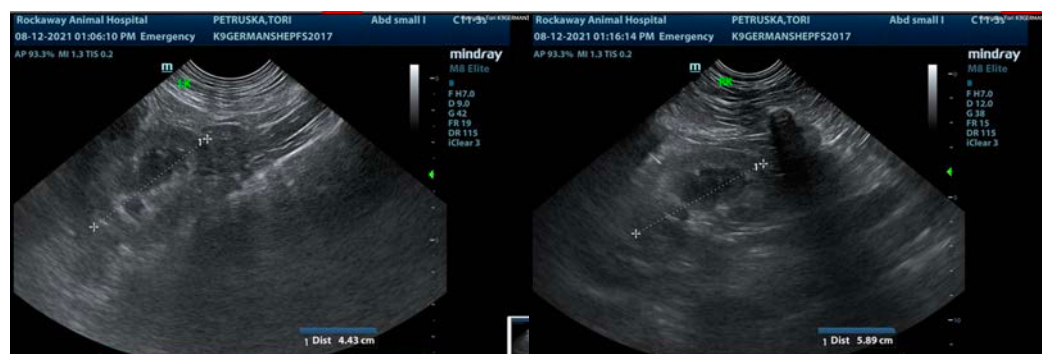
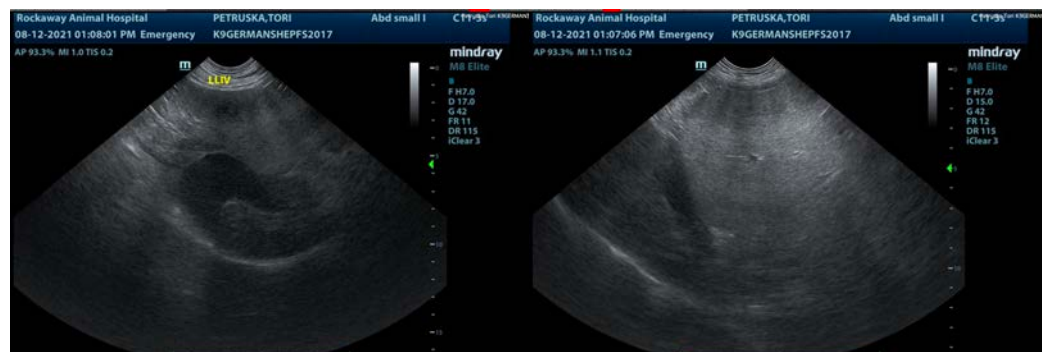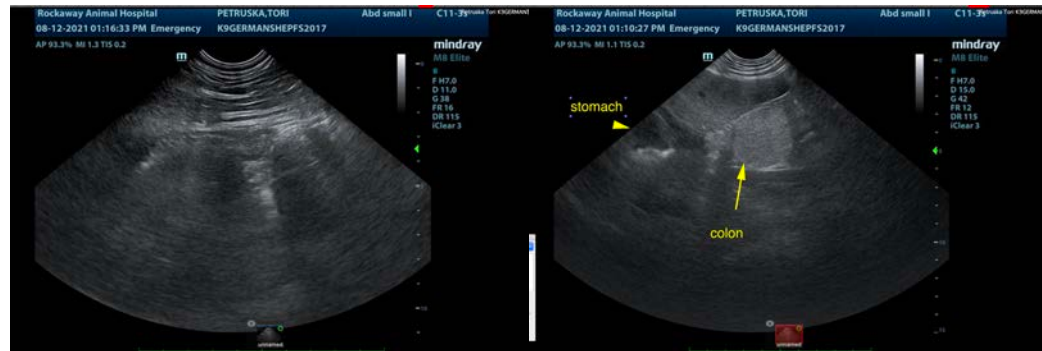24578

DATE

8/12/21

INTERPRETATION OF THE FINDINGS & FURTHER RECOMMENDATIONS

I recommend a fresh fecal smear and fecal floatation analysis. Plasma expanders, broad-spectrum antibiotics, GI protectants all indicated and reassessment of the clinical signs. 24-hour NPO.



The information and recommendations provided are based on the images presented by the referring veterinarian. No evaluation can be communicated regarding pathology that was not visible in the image/video clips provided.

Thank you for this referral. If the clinical or image interpretation does not parallel your findings or if I can be of any further assistance please contact me.

Eric Lindquist, DMV, DABVP, Cert. IVUSS, CEO of SonoPath.com
info@SonoPath.com