



**PATIENT**

Newton Mireault

**SPECIES**

Feline

**BREED**

Domestic Shorthair

**SEX**

Neutered male

**AGE**

12 years

**WEIGHT**

4.7 kg

**INTERPRETED BY**

Eric Lindquist, DMV  
DABVP, Cert. IVUSS

**IMAGING PERFORMED BY**

Dr. Belan

**HOSPITAL NAME**

Rockaway AH

**REFERRING VET**

Alpine 24/7 V/C

**INVOICE**

91163

**DATE**

8/12/21

**PRESENTING CLINICAL SIGNS**

History: Presented last night despondent with hypoglycemia .  
Severe leukopenia and low blood sugar

**ULTRASONOGRAPHIC EXAMINATION OF THE ABDOMEN**

**Urinary System**

The **urinary bladder**, trigone, and pelvic urethra presented normal thicknesses and normal tone. The ureters were not visible which is normal. No uroliths or sediment were visualized and anechoic urine was present. No evidence of inflammatory or neoplastic changes was noted. Ureteral papillae were normal.

The **kidneys** revealed largely normal size and structure, corticomedullary definition and ratio (cortex 1/3 of medulla) were essentially maintained with some age-related loss of curvilinear patterns regarding the capsule and C/M junction. The cortices presented largely uniform texture with some increased echogenicity expected for this age patient. Medullary structure differed distinctly from that of the cortex and no evidence of pelvic dilation was present. The right kidney measured 4.5 cm. The left kidney measured 4.33 cm.

**Adrenal Glands**

Both **adrenal glands** were visualized and recognized as having normal shape, size, position and echogenicity for this breed. The phrenic vasculature, glandular echogenicity and detail were unremarkable. Capsule, cortex, and medullary definition were normal for this age patient. The right adrenal gland measured 0.47 cm. The left adrenal gland measured 0.43 cm.

**Spleen**

The **spleen** was largely smooth with subtle heterogeneous parenchymal changes while maintaining normal echogenic relationship to the liver and kidney. Hyperechoic, lipogranulomatous nodules were noted, yet not pathological. These changes are consistent with normal age-related alteration. The capsule was smooth without noticeable impingement from within the spleen or from pathology in the adjacent abdomen. The splenic vasculature demonstrated normal volume without signs of congestion or significant contraction. The spleen measured 00.68 cm in width.

**Liver**

The **liver** revealed slight, coarse architecture with minor, heterogenous parenchymal changes. The common bile duct was normal and measured 0.2 cm.

**Gastrointestinal**

The **gastrointestinal tract** revealed minor variable thickening and echogenic submucosal changes most consistent with low grade end result of chronic GI disease such as IBD and may be related to



**PATIENT**

Newton Mireault

malassimilation of nutrients if any weight loss is present. The stomach revealed anechoic fluid distension. The mesenteric lymph nodes were reactive and measured 0.34 cm.

**SPECIES**

Feline

**Pancreas**

The base and limbs of the **pancreas** were observed to be largely isoechoic to surrounding omental fat. Pancreatic duct and capsular contour were acceptably normal and parenchyma respected normal curvilinear patterns. No overt evidence of active inflammatory or neoplastic disease was noted.

**BREED**

Domestic Shorthair

**ULTRASONOGRAPHIC FINDINGS**

**SEX**

Neutered male

Structurally unremarkable geriatric abdomen.

Minor, mesenteric lymphadenopathy.

**AGE**

12 years

**INTERPRETATION OF THE FINDINGS & FURTHER RECOMMENDATIONS**

There was no overt evidence of lesions that would be responsible for insulinoma. Other causes of hypoglycemia such as sepsis and toxin exposure such as xylitol or similar should be considered. There was no evidence of structural disease noted. CBC path review +/- bone marrow aspirate is warranted. Insulin glucose profile would be indicated.

**WEIGHT**

4.7 kg

**INTERPRETED BY**

Eric Lindquist, DMV  
DABVP, Cert. IVUSS

**IMAGING PERFORMED BY**

Dr. Belan

**HOSPITAL NAME**

Rockaway AH

**REFERRING VET**

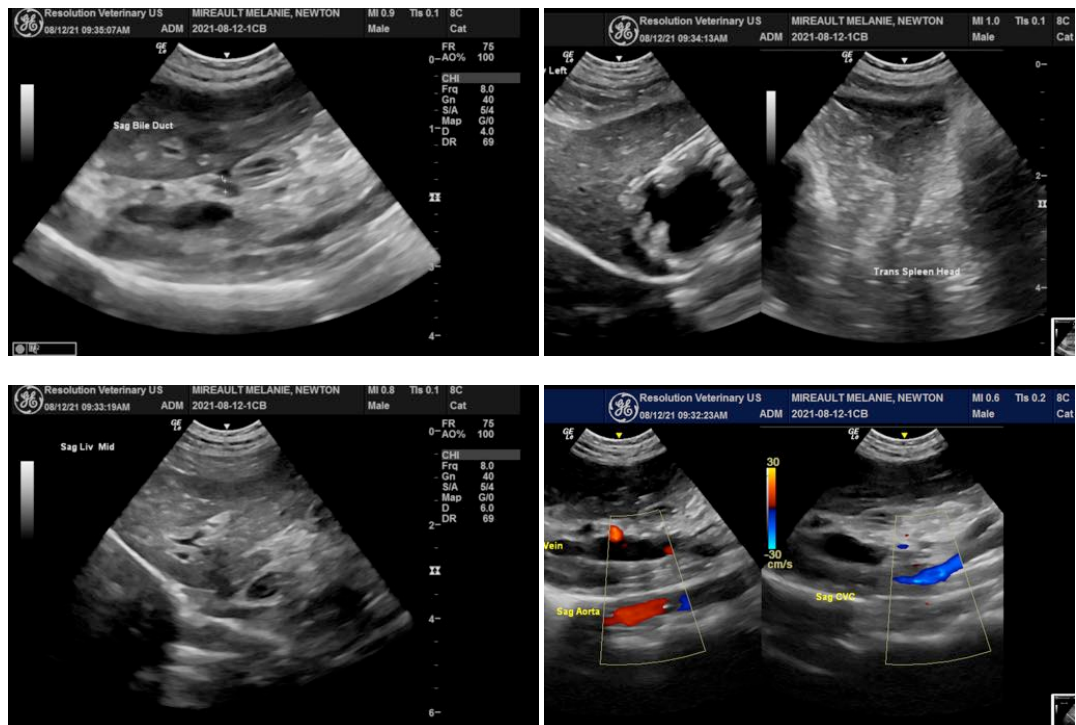
Alpine 24/7 V/C

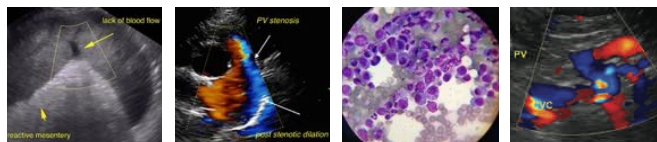
**INVOICE**

91163

**DATE**

8/12/21





**PATIENT**

Newton Mireault

**SPECIES**

Feline

**BREED**

Domestic Shorthair

**SEX**

Neutered male

**AGE**

12 years

**WEIGHT**

4.7 kg

**INTERPRETED BY**

Eric Lindquist, DMV  
DABVP, Cert. IVUSS

**IMAGING PERFORMED BY**

Dr. Belan

**HOSPITAL NAME**

Rockaway AH

**REFERRING VET**

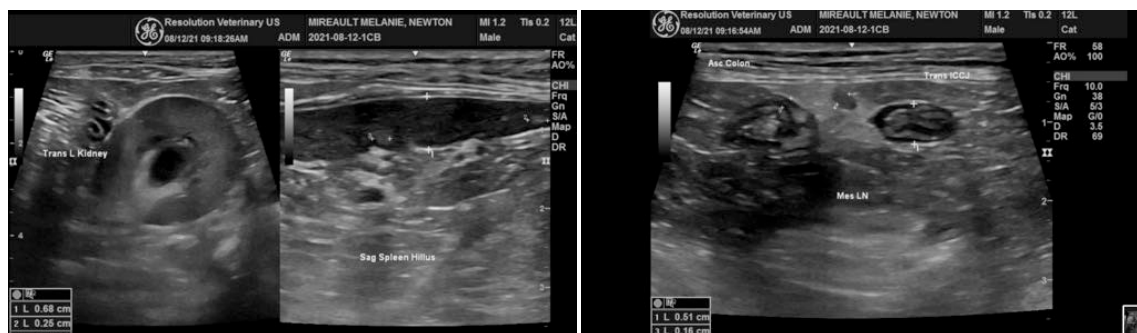
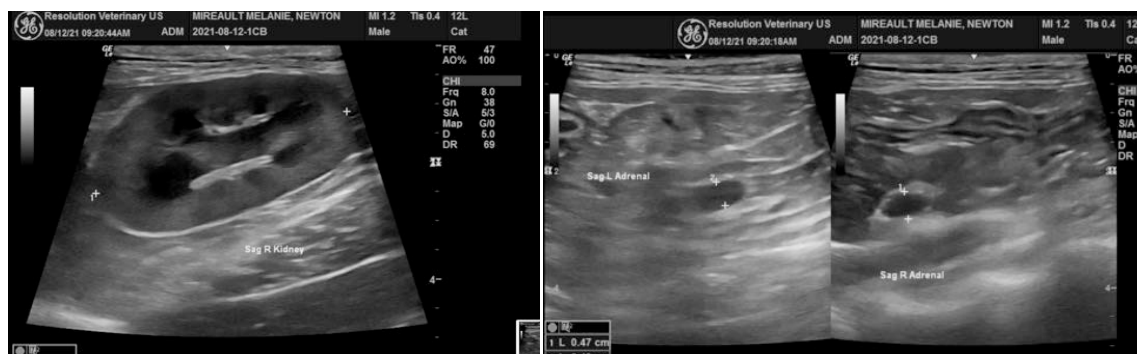
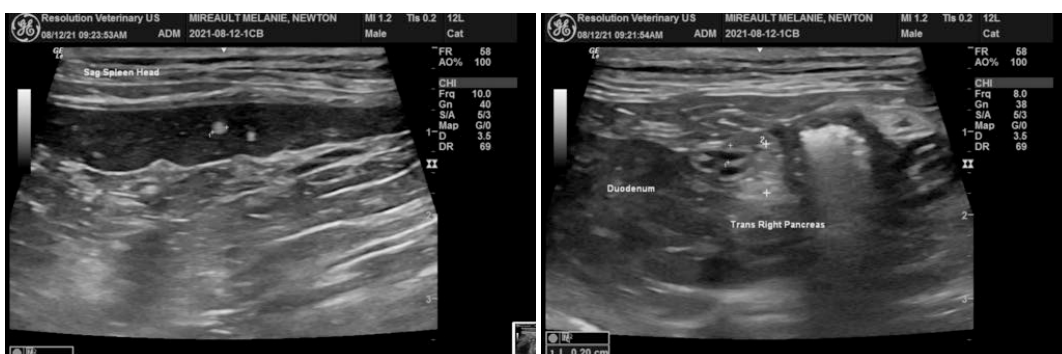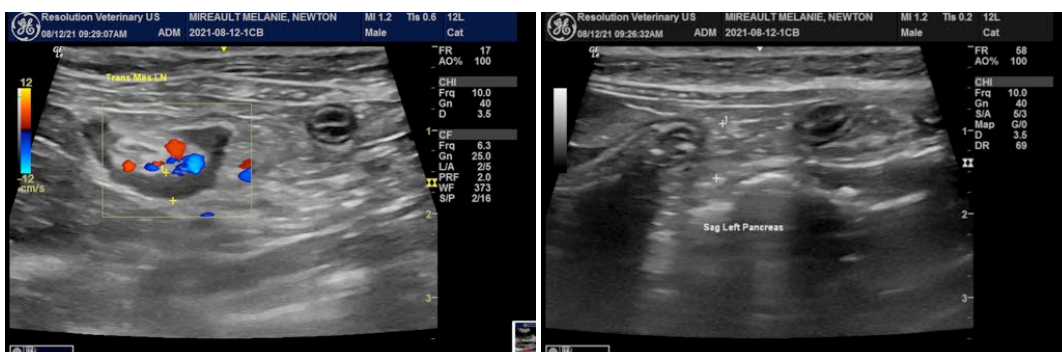
Alpine 24/7 V/C

**INVOICE**

91163

**DATE**

8/12/21



The information and recommendations provided are based on the images presented by the referring veterinarian. No evaluation can be communicated regarding pathology that was not visible in the image/video clips provided.

Thank you for this referral. If the clinical or image interpretation does not parallel your findings or if I can be of any further assistance please contact me.



**PATIENT**

Newton Mireault

Eric Lindquist, DMV, DABVP, Cert. IVUSS, CEO of SonoPath.com  
[info@SonoPath.com](mailto:info@SonoPath.com)

**SPECIES**

Feline



The following is an applicable excerpt from the *Curbside Guide to Diagnosis & Treatment of Sonographic Disease* offered by [SonoPath.com](http://www.sonopath.com) Lindquist, Frank, Lobetti, and Modler.

**BREED**

Domestic Shorthair

An essential quick guide for every general practitioner and sonographer.

**SEX**

Neutered male

**AGE**

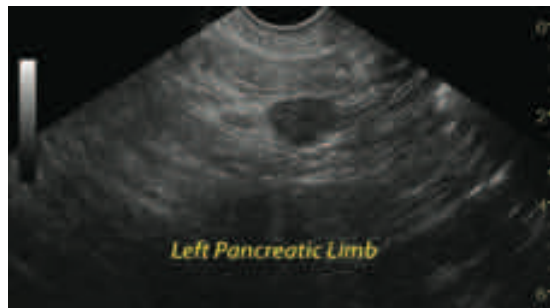12 years

**Hypoglycemic Syndrome: Insulinoma and Other**

<http://www.sonopath.com/Hypoglycemia>

**WEIGHT**

4.7 kg



Short axis of the left pancreatic limb in a dog with an insulinoma seen as an ovoid hypoechoic mass lesion expanding the pancreatic capsule.

**INTERPRETED BY**

Eric Lindquist, DMV  
DABVP, Cert. IVUSS

**IMAGING PERFORMED BY**

Dr. Belan

**HOSPITAL NAME**

Rockaway AH

**REFERRING VET**

Alpine 24/7 V/C

**Description:** Hypoglycemia can be found incidentally or associated with non-specific clinical signs, such as listlessness and weakness. It is essential to consider the multiple differentials for hypoglycemia in order to avoid a potential hypoglycemic crisis. One must perform a rapid and efficient workup to arrive at a diagnosis and prescribe the proper therapy.

**INVOICE**

91163

Differentials for hypoglycemia include: laboratory or handling error; sepsis; toxins (e.g. xylitol, ethylene glycol); hunting dog hypoglycemia; Addison's disease; polycythemia; liver failure; poorly regulated diabetes mellitus; and neoplasia (e.g. leiomyosarcoma, hepatic, lymphoma, and insulinoma).

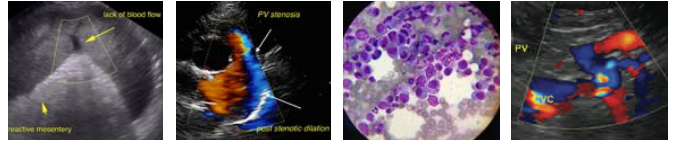
**DATE**

8/12/21

Once other causes of hypoglycemia have been ruled out, one may initiate an investigation into the possibility of insulinoma. Insulinoma is a tumor of the pancreas that originates in the beta cells and leads to



<b>PATIENT</b>	the unregulated secretion of insulin and hypoglycemic syndrome. The tumor can be a malignant carcinoma or a more benign form of adenoma. There is, however, controversy regarding the exact histopathology associated with insulinoma types.
Newton Mireault	
<b>SPECIES</b>	
Feline	Insulinoma patients are usually middle-aged dogs. Half of all cases present with metastasis to the lymph nodes, liver, and mesentery at the time of diagnosis. There are 3 stages of insulinoma:
<b>BREED</b>	
Domestic Shorthair	Stage 1: Pancreatic localization
	Stage 2: Pancreas and lymph nodes with a median survival time (MST) of 1.5 years
<b>SEX</b>	Stage 3: Organ metastasis with an MST of 6 months.
Neutered male	
<b>AGE</b>	<b>Clinical Signs:</b> Neuroglycopenia syndrome results in lethargy, ataxia, collapse, and seizures. Catecholamine release from hypoglycemia leads to hunger, behavior changes, and muscle tremors. Postprandial exacerbation of clinical signs can occur.
12 years	
<b>WEIGHT</b>	<b>Diagnostics:</b> When investigating for insulinoma, one should use a fluoride-containing tube (i.e., a grey top tube) to obtain an accurate glucose level. A fasting glucose level below 60 mg/dl is diagnostic for hypoglycemia. Insulinoma is indicated when one observes the Whipple's triad of hypoglycemia, clinical signs consistent are with hypoglycemia, and the latter resolve with the administration of dextrose.
4.7 kg	
<b>INTERPRETED BY</b>	
Eric Lindquist, DMV DABVP, Cert. IVUSS	Fasting insulin and glucose ratio: A high normal to elevated insulin level with glucose < 60 mg/dl is diagnostic for insulinoma.
<b>IMAGING PERFORMED BY</b>	
Dr. Belan	Imaging: Localizing the lesion with staging is best approached by ultrasound. The ability to localize the lesion may be highly operator- and/or machine-dependent given the often small or even microscopic nature of insulinoma, especially early on in the disease. Primary or secondary lesions associated with insulinoma can often be identified with higher resolution sonography. Appropriate ultrasound-guided sampling (FNA or core biopsy) can be performed of any enlarged lymph node or hepatic nodule if a primary pancreatic lesion is not seen.
<b>HOSPITAL NAME</b>	
Rockaway AH	
<b>REFERRING VET</b>	
Alpine 24/7 V/C	
<b>INVOICE</b>	Computed tomography (CT) with contrast is likely more sensitive than the average sonographer when it comes to assessing insulinoma.
91163	
<b>DATE</b>	Tumor staging and histopathological characterization in conjunction with the Ki67 biomarker index will yield solid criteria for the prognostic evaluation of insulinoma.
8/12/21	



**PATIENT**

Newton Mireault

**Treatment:**

**SPECIES**

Feline

In cases of emergency hypoglycemic crisis, apply corn syrup to the gums. Administer a dextrose bolus (0.5g/kg IV) and maintain 2.5-10% dextrose solution. If cerebral edema occurs, one should administer dexamethasone (2 mg/kg IV) and give mannitol (0.5 mg/kg IV) over a 20-minute period.

**BREED**

Domestic Shorthair

One should perform a surgical pancreatectomy if the tumor is localized (i.e., stage 1 insulinoma). Given that the lesion may be difficult to locate with the naked surgical eye or via palpation, the surgical procedure can be enhanced by intraoperative ultrasound.

**SEX**

Neutered male

In cases of stage 2 and 3 insulinoma, administer prednisolone (0.25 mg/kg PO BID). A glucagon IV infusion has also been suggested; it should be infused with saline at 5 mg/kg/min for refractory cases. If prednisone is not adequate, one can supplement with benzothiadiazide diazoxide (5 mg/kg PO BID).

**AGE**

12 years

Patients should be fed small, frequent portions of a diet high in fat, complex carbohydrates, and protein.

**WEIGHT**

4.7 kg

Chemotherapy: In some cases, the use of alloxan (65 mg/ kg IV) has been shown to be helpful.

**INTERPRETED BY**

Eric Lindquist, DMV  
DABVP, Cert. IVUSS

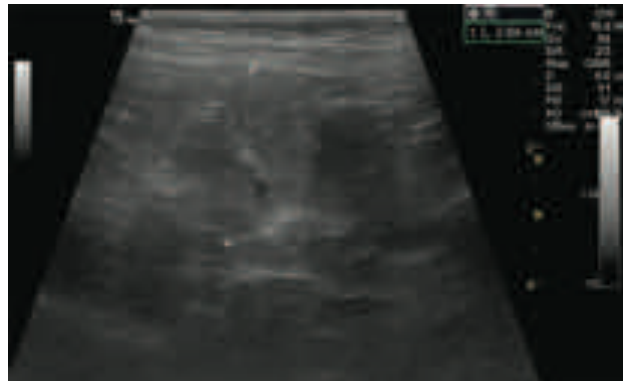**Conclusion:** The largest study of insulinoma patients identified a general MST of 547 days; however, the MST was 785 days for those undergoing pancreatectomy and 1316 days for those that relapsed after surgery and received treatment with prednisone. Other studies have reported an MST of 258 days with pancreatectomy. All of these results indicate that insulinoma is treatable. Using ultrasonography for staging and histopathological characterization is essential in order to determine whether the appropriate treatment should be surgical, medical, or both.

**IMAGING PERFORMED BY**

Dr. Belan

**HOSPITAL NAME**

Rockaway AH



Short axis of the left pancreatic limb in a cat with an insulinoma seen as a complex heterogenous mass lesion expanding the pancreatic capsule (between calipers). Note the mass effect of the tumor displacing the transverse colon caudally.

**REFERRING VET**

Alpine 24/7 V/C

**INVOICE**

91163

**DATE**

8/12/21



**PATIENT**

Newton Mireault

**SPECIES**

Feline

**BREED**

Domestic Shorthair

**SEX**

Neutered male

**AGE**

12 years

**WEIGHT**

4.7 kg

**INTERPRETED BY**

Eric Lindquist, DMV  
DABVP, Cert. IVUSS

**IMAGING PERFORMED BY**

Dr. Belan

**HOSPITAL NAME**

Rockaway AH

**REFERRING VET**

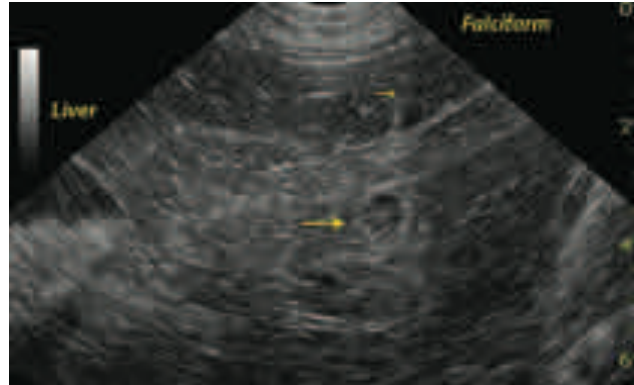
Alpine 24/7 V/C

**INVOICE**

91163

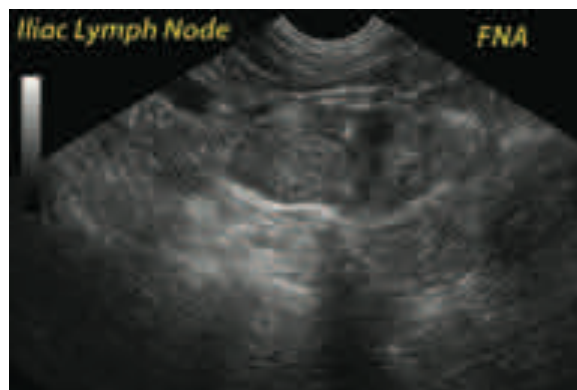
**DATE**

8/12/21



Subxiphoidal short axis of the liver in a dog with an insulinoma during ultrasound guided sampling of a suspected metastatic lesion.

The needle trajectory is seen as a hyperechoic line (small arrow) approaching the hypoechoic nodule (large arrow) within the liver parenchyma.



Long axis of the medial iliac lymph node during needle aspiration in a dog with multifocal metastatic spread of an insulinoma. The echogenic needle tip is seen within the lymph node. The metastatic lymph node is enlarged, rounded, hypoechoic and heterogeneous. The primary metastatic loci in insulinoma are the regional lymph nodes (hepatic, pancreaticoduodenal, gastric) and the liver. Hence, metastatic insulinoma lesions in the iliac lymph node in this case was not a typical occurrence.

**References:**

Buishand FO, Kik M, Kirpensteijn J. Evaluation of clinico-pathological criteria and the Ki67 index as prognostic indicators in canine insulinoma. *Vet J* 2010;185:62-67.

Fischer JR, Smith SA, Harkin KR: Glucagon constant-rate infusion: A novel strategy for management of hyperinsulinemic-hypoglycemia crisis in the dog. *J Am Anim Hosp Assoc* 2000;36:27-32.

Polton GA, White RN, Brearley MJ, et al. Improved survival in a retrospective cohort of 28 dogs with insulinoma. *J Small Anim Pract* 2000;48:151-56.

Steiner JM, Bruyette DS: Canine insulinoma. *Compend Contin Educ Pract Vet* 1996;18:31-36.

Tobin RL, Nelson RW, Lucroy MD, et al. Outcome of surgical versus medical treatment of dogs with beta cell neoplasia: 39 cases (1990-1997). *JAVMA* 1999;215:226-30.