



PATIENT

Sandy Moresi

SPECIES

Canine

BREED

Soft Wheat Terrier

SEX

Spayed Female

AGE

6 Years

WEIGHT

22.8

INTERPRETED BY

Eric Lindquist, DMV
DABVP, Cert. IVUSS

**IMAGING
PERFORMED BY**

JK

HOSPITAL NAME

Hamburg VC

REFERRING VET

Dr. Branning

INVOICE

23908

DATE

8/11/23

PRESENTING CLINICAL SIGNS

History: Poor appetite, lethargic, weight loss, and low pcv

Abnormal PE/Chem/CBC/UA Results: ALK PHOS 382, PCV 32%, RBC 4.0 PLATLET 120

ULTRASONOGRAPHIC EXAMINATION OF THE ABDOMEN

Urinary System

The **urinary bladder**, trigone, and pelvic urethra presented normal thicknesses and normal tone. The ureters were not visible which is normal. No uroliths or sediment were visualized and anechoic urine was present. No evidence of inflammatory or neoplastic changes were noted. Ureteral papillae were normal.

The **kidneys** revealed normal size and structure, corticomedullary definition and ratio for this age. The cortices presented largely uniform texture with normal echogenic relationship to liver and spleen. Medullary structure differed distinctly from the cortex and no evidence of pelvic dilation was present. The capsules were acceptably uniform without significant irregularities. Slight pinpoint mineralizations were noted. The right kidney measured 5.31 cm. The left kidney measured 5.15 cm.

Adrenal Glands

Both **adrenal glands** were visualized and recognized as having normal shape, size, position and echogenicity for this breed. The phrenic vasculature, glandular echogenicity and detail were unremarkable. Capsule, cortex, and medullary definition were normal for this age patient. The left adrenal gland measured 2.23 cm x 0.48 cm.

Spleen

The **spleen** revealed an expansive hypoechoic undifferentiated mass, measuring approximately 7.0 cm. The splenic mass revealed enhanced surrounding mesentery and areas of cavitation deriving from the cranial pole of the spleen.

Liver

The **liver** images submitted revealed subjectively normal liver size, contour, and structure. Parenchymal echogenicity was naturally coarse and hypoechoic to the spleen. Vascular and biliary tracts were of normal volume with no evidence of congestion. The gallbladder presented acceptably thin walls with primarily anechoic content. The cystic and common bile ducts were normal. No pathological hepatic lymphadenopathy was evident. No overt structural evidence of inflammatory, infiltrative or regenerative pathology was evident.

Gastrointestinal

Examination of the **gastrointestinal tract** revealed a stomach and intestine free of stasis, of normal wall thickness, acceptable curvilinear mural detail, and peristaltic activity. Small and large intestine demonstrated normal luminal chyme and stool consistency respectively. No obstructive or overt infiltrative disease was noted. No associated abnormal lymphatic activity was noted.

Pancreas



PATIENT

Sandy Moresi

The base and limbs of the **pancreas** were observed to be largely isoechoic to surrounding omental fat. Pancreatic duct and capsular contour were acceptably normal and parenchyma respected normal curvilinear patterns. No overt evidence of active inflammatory or neoplastic disease was noted.

SPECIES

Canine

ULTRASONOGRAPHIC FINDINGS

- Splenic mass- sarcoma is suspected. Hemangiosarcoma or round cell neoplasia are both possible.

BREED

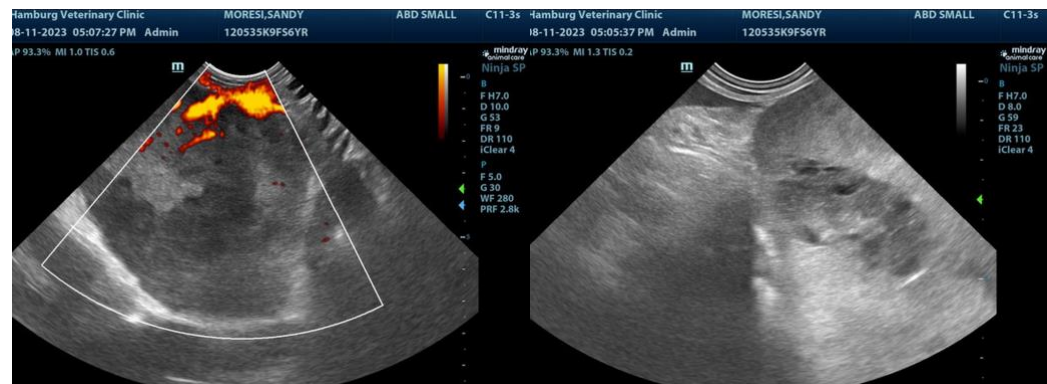Soft Wheat Terrier

INTERPRETATION OF THE FINDINGS & FURTHER RECOMMENDATIONS

No overt metastatic disease noted, however, micrometastasis cannot be ruled out. Chest radiographs, echocardiogram and immediate exploratory surgery/splenectomy are indicated.

SEX

Spayed Female



AGE

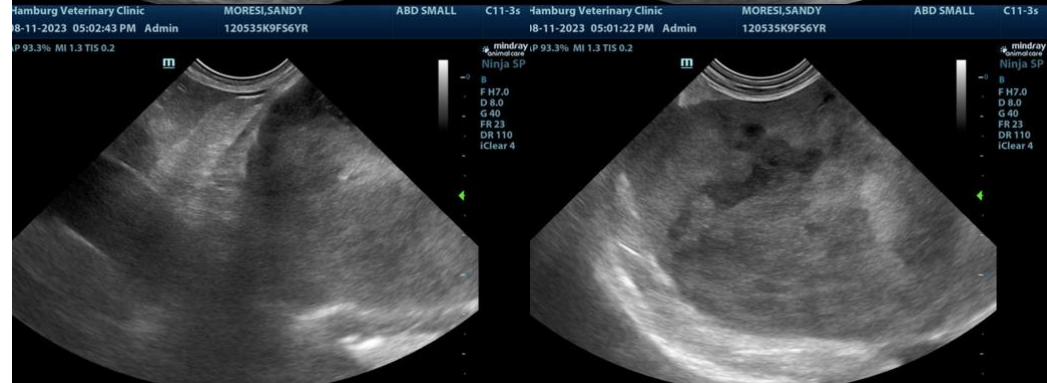6 Years

WEIGHT

22.8

INTERPRETED BY

Eric Lindquist, DMV
DABVP, Cert. IVUSS

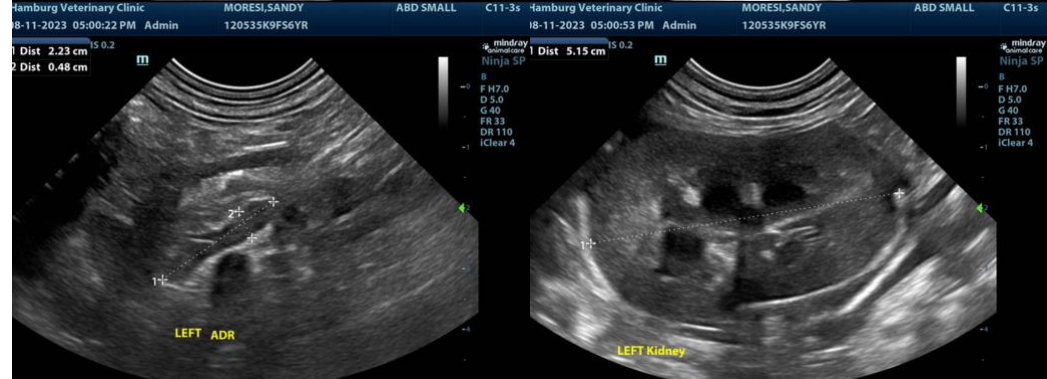

IMAGING PERFORMED BY

JK

HOSPITAL NAME

Hamburg VC



REFERRING VET

Dr. Branning

INVOICE

23908

DATE

8/11/23



PATIENT

Sandy Moresi

SPECIES

Canine

BREED

Soft Wheat Terrier

SEX

Spayed Female

AGE

6 Years

WEIGHT

22.8

INTERPRETED BY

Eric Lindquist, DMV
DABVP, Cert. IVUSS

IMAGING PERFORMED BY

JK

HOSPITAL NAME

Hamburg VC

REFERRING VET

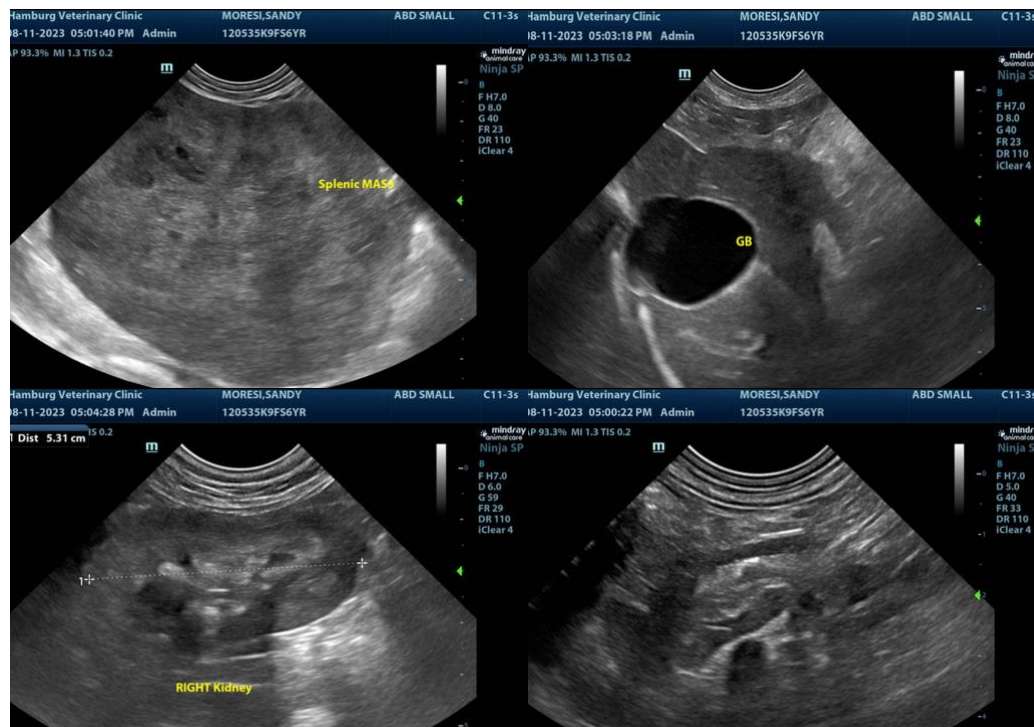
Dr. Branning

INVOICE

23908

DATE

8/11/23



The information and recommendations provided are based on the images presented by the referring veterinarian. No evaluation can be communicated regarding pathology that was not visible in the image/video clips provided.

Thank you for this referral. If the clinical or image interpretation does not parallel your findings or if I can be of any further assistance please contact me.

Eric Lindquist, DMV, DABVP, Cert. IVUSS, CEO of SonoPath.com
info@SonoPath.com