



PATIENT

Bucca Resnick

SPECIES

Canine

BREED

Catahoula X

SEX

Male

AGE

1

WEIGHT

55

INTERPRETED BY

Eric Lindquist, DMV
DABVP, Cert. IVUSS

IMAGING PERFORMED BY

Jenn

HOSPITAL NAME

Rockaway AH

REFERRING VET

Dr. Maniar

INVOICE

44619

DATE

8/11/23

PRESENTING CLINICAL SIGNS

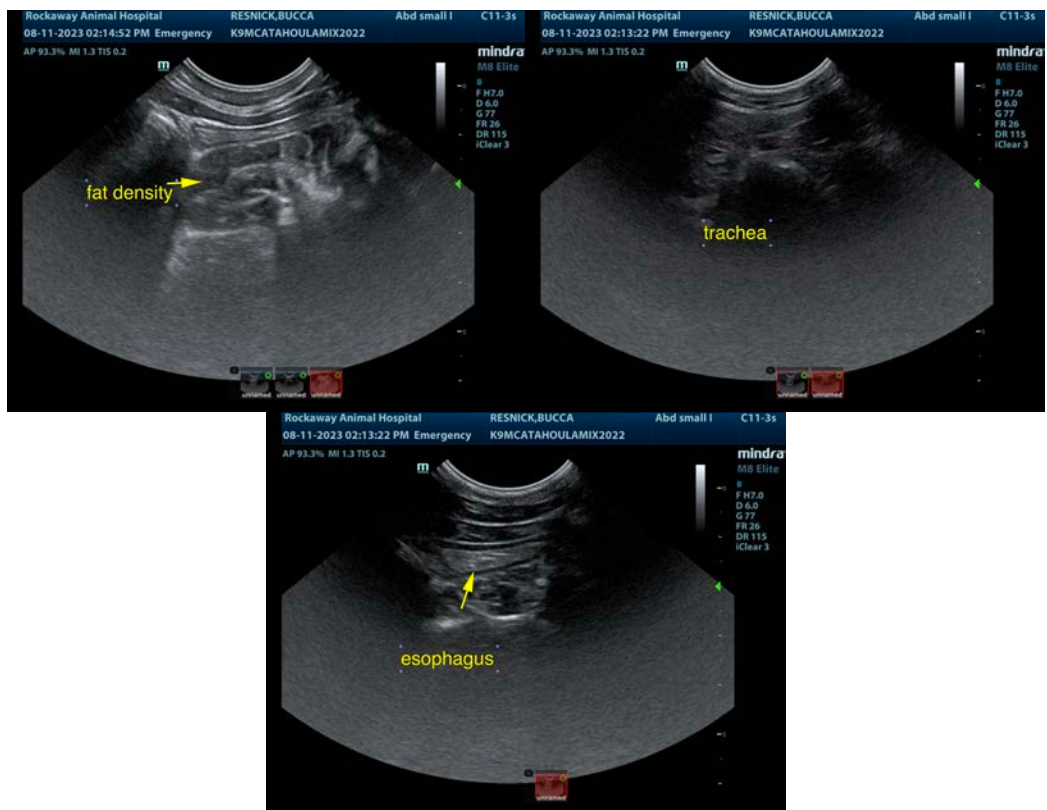
Pt has lump on neck, had blood draw from jugular 8/6 and has not gone down.

LIMITED ULTRASONOGRAPHIC EXAMINATION

A group of images submitted of the neck region revealed a normal esophagus and trachea. Regional fascia was normal. There is a lipomatous type accumulation adjacent to the vertebrae and muscle tissue.

INTERPRETATION OF THE FINDINGS & FURTHER RECOMMENDATIONS

No evidence of pathology.



The information and recommendations provided are based on the images presented by the referring veterinarian/sonographer. No evaluation can be communicated regarding pathology that was not visible in the image/video clips provided.

Thank you for this referral. If the clinical or image interpretation does not parallel your findings or if I can be of any further assistance please contact me.

Eric Lindquist, DMV, DABVP, Cert. IVUSS, CEO of SonoPath.com

info@SonoPath.com