



PATIENT

Tory Kossodo

SPECIES

Feline

BREED

Oriental Shorthair

SEX

Spayed female

AGE

21 years

WEIGHT

7.1 lbs

INTERPRETED BY

Eric Lindquist, DMV
DABVP, Cert. IVUS

IMAGING PERFORMED BY

Dr. Mandeville

HOSPITAL NAME

Bettervet

REFERRING VET

Dr. Mandeville

PRESENTING CLINICAL SIGNS

History: grade 3/6 left systolic murmur chronic CKD and chronic constipation
Abnormal PE/Chem/CBC/UA Results: Azotemic, elevated SDMA, ProBNP 1,042

ULTRASONOGRAPHIC EXAMINATION OF THE HEART

The echocardiogram in this patient demonstrated normal **left atrial** size based on 3 separate LA measurements. The cranial and caudal **mitral** valve leaflets presented normal linear structure and kinetics. The **left ventricle** presented normal thicknesses with linear contour and was not dilated nor restricted. The **myocardium** presented normal echogenicity without subjective evidence of significant fibrotic or ischemic disease. **Contractility** of the ventricular walls was adequate and in normal range for this patient evidenced by the fractional shortening measurement and subjective evaluation of the different regions and angles of the myocardium. There is minor turbulence at the **left ventricular outflow** tract/likely aortic insufficiency. The **right atrium** and auricle revealed normal size, structure and content. No evidence of masses was noted or chamber overload. **Tricuspid** valvular assessment demonstrated adequate linear morphology and kinetics. The **right ventricle** was of normal size (1/3 diameter of LV), chordae structure, myocardial echogenicity and thickness. **Pulmonic** insufficiency was noted. No visible **pericardial** or free pleura fluid was noted or extra cardiac pathology in the visible planes. The cranial **mediastinum and pericardial regions** were free of masses in the visible window.

FELINE CARDIAC PARAMETERS	BODY WEIGHT (kg)	HR (BPM)	IVSd (cm)	LVIDd (cm)	LVWd (cm)	FS (%)	EF (%)
NORMAL PARAMETER	-----	150-240	0.3-0.6	1.0-2.1	0.25-0.6	35-67	80-100
PATIENT		NM	0.32	1.8	0.43	35	
FELINE CARDIAC PARAMETERS	LA/AO (Boon)	LA/AO HEART BASE (Sisson)	LA 2D 4-chamber long axis AS to FW (Sisson) (cm)	LVOT VEL. (m/s)	RVOT VEL. (m/s)	IVRT (m/)	
NORMAL PARAMETER	<1.5	0.88-1.79	0.7-1.7	<1.6	<1.3	40-60	
PATIENT	1.1	1.4			0.95	NM	
Adapted from June Boon, Veterinary Echocardiography, 1998 Sisson D et al. JVIM 1991; 5: 232, Jacobs et al. Am J Vet Res 1985; 46:1705							

ULTRASONOGRAPHIC FINDINGS

Structurally unremarkable heart.
Trivial mitral, aortic and pulmonic insufficiency. Otherwise, structurally normal heart.

INVOICE

32322

DATE

8/11/22



PATIENT

Tory Kossodo

INTERPRETATION OF THE FINDINGS & FURTHER RECOMMENDATIONS

There is no evidence of significant disease. Volume shifts are likely playing a role in this patient given the global history. There is no contraindication to fluid therapy if necessary.

SPECIES

Feline

Benign flow murmurs are common in cats. This may be owing to volume shifts, tachycardia, benign (DRVOTO) right ventricular outflow changes, trivial turbulence in any of the valvular apparatuses, or possibly excessive stethoscope pressure against the chest according to a recent study These are physiologically benign and unrelated to specific pathology.

BREED

Oriental Shorthair

SEX

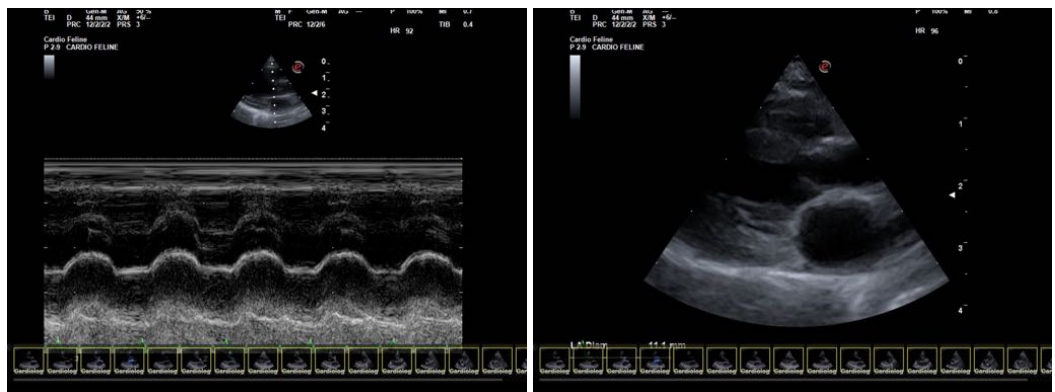
Spayed female

AGE

21 years

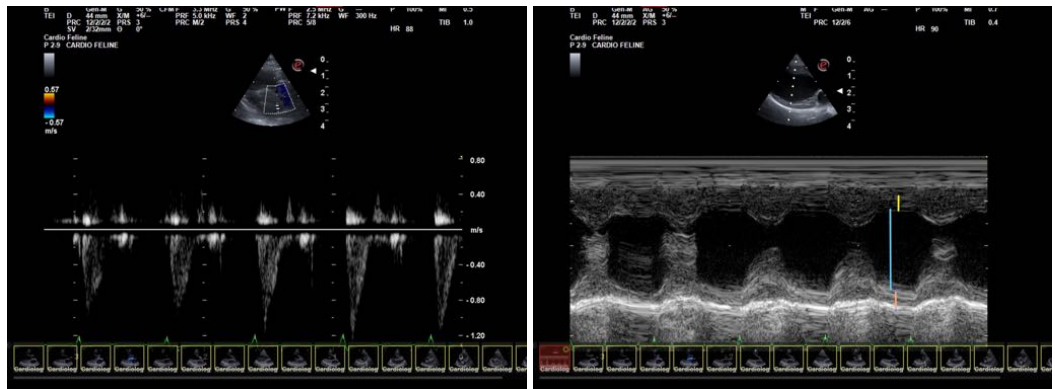
WEIGHT

7.1 lbs



INTERPRETED BY

Eric Lindquist, DMV
DABVP, Cert. IVUS

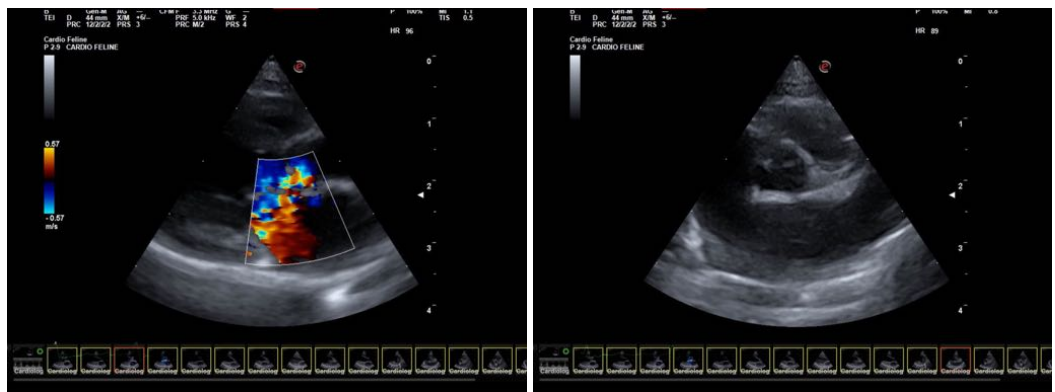


IMAGING PERFORMED BY

Dr. Mandeville

HOSPITAL NAME

Bettervet



REFERRING VET

Dr. Mandeville

INVOICE

32322

DATE

8/11/22



PATIENT

Tory Kossodo

SPECIES

Feline

BREED

Oriental Shorthair

SEX

Spayed female

AGE

21 years

WEIGHT

7.1 lbs

INTERPRETED BY

Eric Lindquist, DMV
DABVP, Cert. IVUSS

**IMAGING
PERFORMED BY**

Dr. Mandeville

HOSPITAL NAME

Bettervet

REFERRING VET

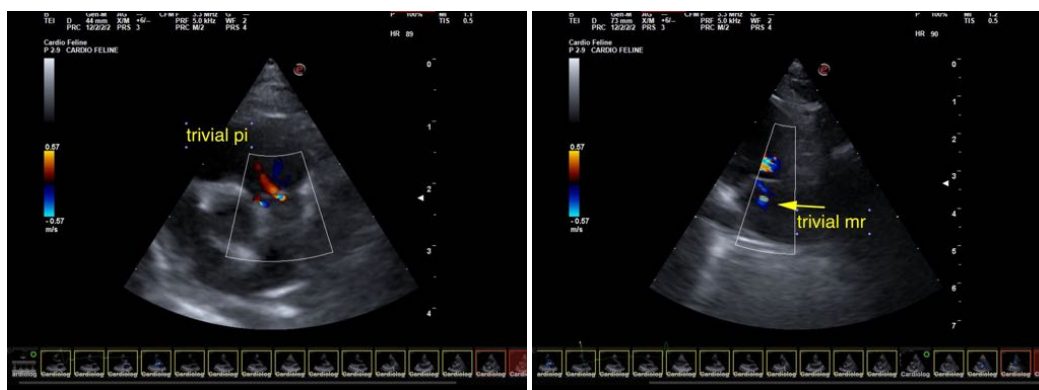
Dr. Mandeville

INVOICE

32322

DATE

8/11/22



The information and recommendations provided are based on the images presented by the referring veterinarian/sonographer. No evaluation can be communicated regarding pathology that was not visible in the image/video clips provided.

Thank you for this referral. If the clinical or image interpretation does not parallel your findings or if I can be of any further assistance please contact me.

Eric Lindquist, DMV, DABVP, Cert. IVUSS, CEO of SonoPath.com
info@SonoPath.com