



PATIENT PRESENTING CLINICAL SIGNS

Morgan Hall
SPECIES Abnormal PE/Chem/CBC/UA Results: PE: Quiet/depressed, visibly icteric. BCS 4/9. Dehydrated. ALT > 1,000, ALP 232, T Bili 12.3, GGT 37. CBC unremarkable except Plt 956 and Hct low normal. FPL normal.
 Feline

ULTRASONOGRAPHIC EXAMINATION OF THE ABDOMEN

BREED
Urinary System

DLH
SEX The **urinary bladder**, trigone, and pelvic urethra presented normal thicknesses and normal tone. The ureters were not visible which is normal. No uroliths or sediment were visualized and anechoic urine was present. No evidence of inflammatory or neoplastic changes were noted. Ureteral papillae were normal.

Spayed Female

AGE The **left kidney** revealed largely normal size and structure, corticomedullary definition and ratio (cortex 1/3 of medulla) were essentially maintained with some age-related loss of curvilinear patterns regarding the capsule and C/M junction. The cortex presented largely uniform texture with some increased echogenicity expected for his age patient. Medullary structure differed distinctly from that of the cortex. The left kidney measured 4.45 cm with pyelectasia of 0.6 cm x 0.5 cm.

14 Years

WEIGHT The **right kidney** was dystrophic, irregular, and subnormal in size at 2.27 cm with cortical infarcts and mineralization. The infarcts appear to be stable, no evidence of active inflammation. Likely minimal right renal function. Blood flow was minimal to almost non-existent on power doppler assessment.

7 lb 13 oz

Adrenal Glands

INTERPRETED BY Both **adrenal glands** were visualized and recognized as having normal shape, size, position and echogenicity for this breed. The phrenic vasculature, glandular echogenicity and detail were unremarkable. Capsule, cortex, and medullary definition were normal for this age patient. The left adrenal gland measured 0.50 cm. The right adrenal gland measured 0.51 cm.

Eric Lindquist, DMV

DABVP, Cert. IVUSS

IMAGING PERFORMED BY
Spleen

Dr. Ebersole
 The **spleen** was mildly enlarged (0.9 cm) with uniform, but subtly micronodular parenchyma, and undulating capsular contour. This is consistent with reactive spleen owing to immune stimulus or early infiltrative disease such as mast cell disease or lymphoma. 25-gauge FNA would be ideal if weight loss is an issue to differentiate early round cell neoplasia versus splenitis or reactive spleen all of which can present in this manner.

HOSPITAL NAME

Scanvet

Liver

REFERRING VET The **liver** images submitted revealed subjectively normal liver size, contour, and structure. Parenchymal echogenicity was naturally coarse and hypoechoic to the spleen. Vascular and biliary tracts were of normal volume with no evidence of congestion. The gallbladder wall was slightly edematous. The gallbladder was mildly overdistended.

Dr. Bonte

INVOICE
Gastrointestinal

40319
DATE The **gastrointestinal** presentation revealed mild uniform prominence of the gastric mucosa as well as areas of "ropey" small intestinal wall with slight disruption of the normal 1:3 muscularis/mucosal ratio. The stomach was partially full. The intestinal submucosa was slightly irregular, thickened and hyperechoic suggestive of low grade, chronic disease. Some distal small intestinal luminal dilation was noted and transit of chyme with partial obstructive pattern. However, no overt lesion present. Regional

8/11/22



PATIENT

Morgan Hall

dysfunctional bowel likely. No concerning lymphadenopathy was visible. No evidence of obstruction was present. Chronic inflammatory bowel disease is likely with a low possibility of an early neoplastic event such as lymphoma. Full thickness tissue biopsies via open laparotomy, ideally guided by intraoperative ultrasound in order to obtain the most representative mural sample, would be necessary to rule out this possibility.

SPECIES

Feline

Pancreas

The base and limbs of the **pancreas** were observed to be largely isoechoic to surrounding omental fat. Pancreatic duct and capsular contour were acceptably normal and parenchyma respected normal curvilinear patterns. No overt evidence of active inflammatory or neoplastic disease was noted.

BREED

DLH

ULTRASONOGRAPHIC FINDINGS

SEX

Spayed Female

- Dystrophic right kidney
- Minor degenerative left renal changes and pyelectasia – pelvic scarring versus possible pyelonephritis depending upon UA samples.
- Cholangitis liver pattern
- IBD GI pattern

AGE

14 Years

INTERPRETATION OF THE FINDINGS & FURTHER RECOMMENDATIONS

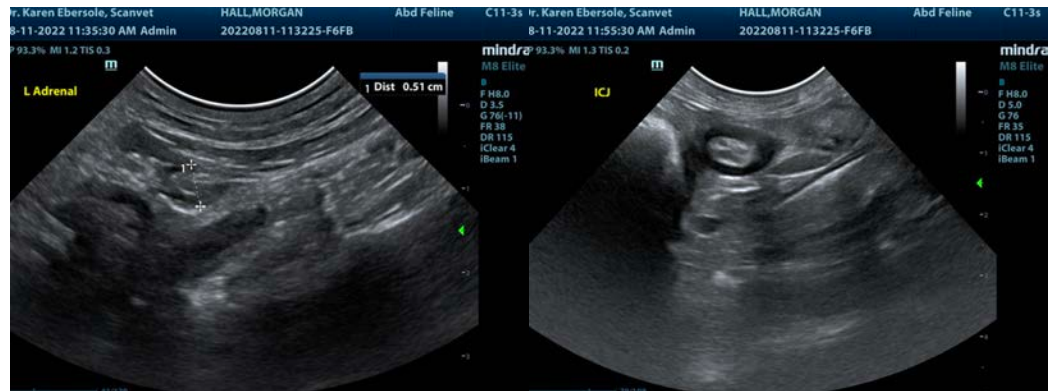
The icterus is likely owing to acute cholangitis/cholangiohepatitis. No overt suspicion of neoplasia. IV fluid support, toxoplasmosis and bartonella titers recommended, Enrofloxacin/Clindamycin combination could be considered. FNA of the liver indicated for further definition. Recheck sonogram after 48-72 hours of treatment.

WEIGHT

7 lb 13 oz

INTERPRETED BY

Eric Lindquist, DMV
DABVP, Cert. IVUSS

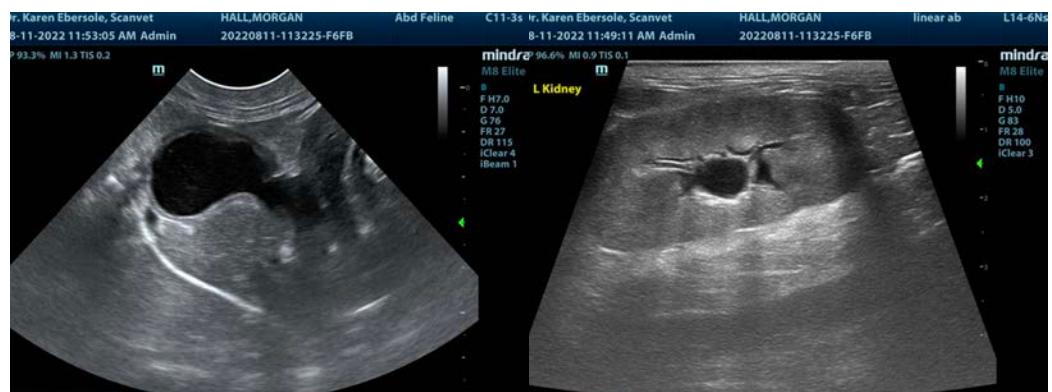


IMAGING PERFORMED BY

Dr. Ebersole

HOSPITAL NAME

Scanvet



REFERRING VET

Dr. Bonte

INVOICE

40319

DATE

8/11/22



PATIENT

Morgan Hall

SPECIES

Feline

BREED

DLH

SEX

Spayed Female

AGE

14 Years

WEIGHT

7 lb 13 oz

INTERPRETED BY

Eric Lindquist, DMV

DABVP, Cert. IVUSS

IMAGING PERFORMED BY

Dr. Ebersole

HOSPITAL NAME

Scanvet

REFERRING VET

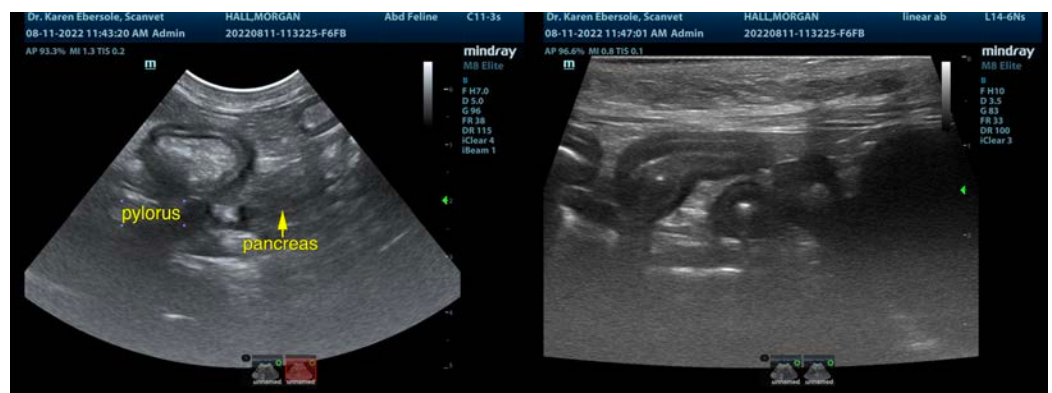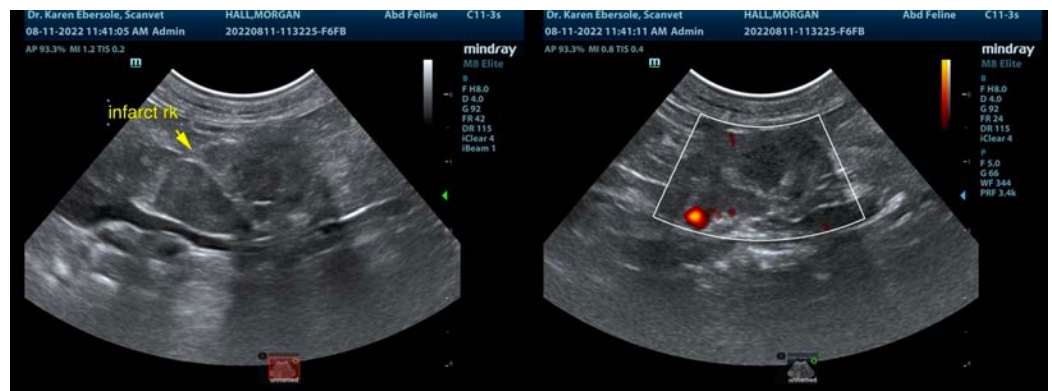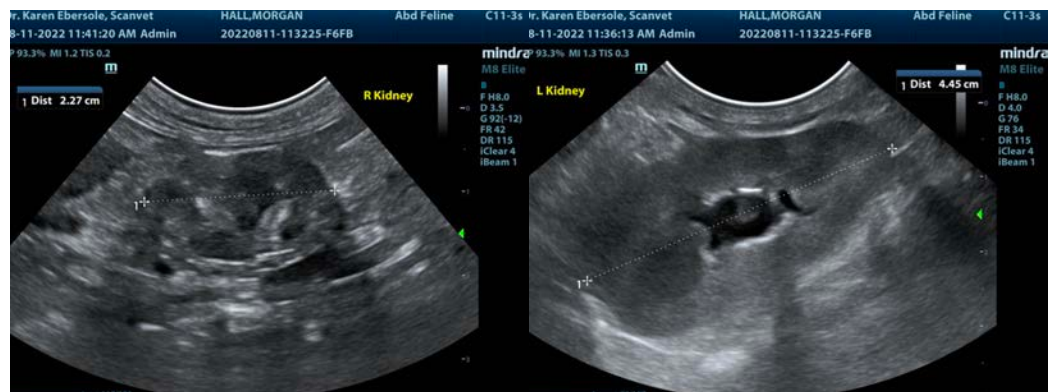
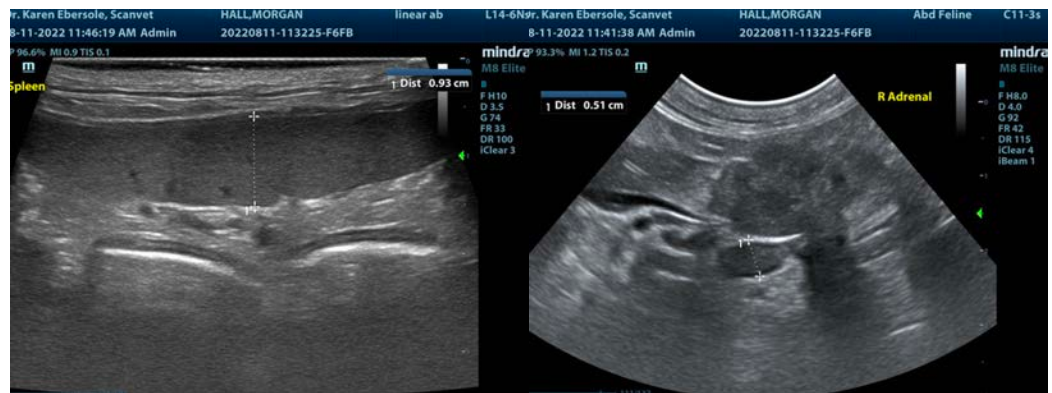
Dr. Bonte

INVOICE

40319

DATE

8/11/22





PATIENT

Morgan Hall

The information and recommendations provided are based on the images presented by the referring veterinarian/sonographer. No evaluation can be communicated regarding pathology that was not visible in the image/video clips provided.

SPECIES

Feline

Thank you for this referral. If the clinical or image interpretation does not parallel your findings or if I can be of any further assistance please contact me.

Eric Lindquist, DMV, DABVP, Cert. IVUSS, CEO of SonoPath.com

info@SonoPath.com

BREED

DLH

SEX

Spayed Female

AGE

14 Years

WEIGHT

7 lb 13 oz

INTERPRETED BY

Eric Lindquist, DMV

DABVP, Cert. IVUSS

IMAGING PERFORMED BY

Dr. Ebersole

HOSPITAL NAME

Scanvet

REFERRING VET

Dr. Bonte

INVOICE

40319

DATE

8/11/22