



**PATIENT PRESENTING CLINICAL SIGNS**

Miso Shi History: Pre neuter murmur check: 2/6 left systolic murmur heard at wellness exam. no other clinical signs.

**SPECIES**

Canine

**BREED**

Shiba Inu

**SEX**

Intact male

**AGE**

11 months

**WEIGHT**

23 lbs

**INTERPRETED BY**

Eric Lindquist, DMV  
DABVP, Cert. IVUS

**IMAGING PERFORMED BY**

Dr. Mandeville

**HOSPITAL NAME**

BetterVet

**REFERRING VET**

Dr. Mandeville

**ULTRASONOGRAPHIC EXAMINATION OF THE HEART**

The echocardiogram in this patient demonstrated normal **left atrial** size based on 3 separate methods of LA evaluation. The cranial and caudal **mitral** valve leaflets presented normal linear structure, extension in systole, and union in diastole with normal kinesis. The **left ventricle** presented thicknesses with linear contour and was not dilated nor restricted. The **myocardium** presented normal echogenicity without subjective evidence of significant fibrotic or ischemic disease. **Contractility** of the ventricular walls was adequate and in normal range for this patient evidenced by the fractional shortening measurement and subjective evaluation of the different regions of the myocardium. The **left ventricular outflow** tract demonstrated normal laminar flow and subjective structural integrity. The **right atrium** and auricle revealed normal size, structure and content. No evidence of masses was noted. **Tricuspid** valvular assessment demonstrated adequate linear morphology and kinesis. The **right ventricle** was of normal size (1/3 diameter of LV), chordae structure, myocardial echogenicity and thickness. **Pulmonary outflow** tract assessment revealed normal valve structure, laminar flow, and diameter (approx. 1:1 pa/ao ratio). No visible **pericardial** or free pleura fluid was noted. The cranial **mediastinum and pericardial and extra-cardiac regions** were free of masses in the visible window.

CANINE CARDIAC PARAMETERS	MR VMAX (m/s)	TR VMAX (m/s)	LA/AO (Boon method)	LA/AO (Heart Base; Swe)	FS (%)	EF (%)	EPSS (cm)
NORMAL PARAMETER	4.5-5.5	<2.7	1.3	<1.6	28-40	40-100	<0.6
PATIENT			1.28	1.28	24	49	0.8
CANINE CARDIAC PARAMETERS	HR (BPM)	AV VMAX (m/s)	PV MAX (m/s)	BODY WEIGHT	LA (2D short axis Base view) (cm)	LVIDd (Avg; 2D and m-mode short axis) (cm)	LVIDs (Avg; 2D and m-mode short axis) (cm)
NORMAL PARAMETER	50-100	0.7-1.7	0.7-1.6	BELOW	BELOW	BELOW	BELOW
PATIENT		1.3	1.2	23 lbs	3.0 max	2.9	

**ULTRASONOGRAPHIC FINDINGS**

**INVOICE** Normal echocardiogram, normal function and structure.

32321 Idiopathic flow murmur is suspected.

**DATE**

8/11/22



**PATIENT**

Miso Shi

**INTERPRETATION OF THE FINDINGS & FURTHER RECOMMENDATIONS**

There was no evidence of pathology. The exact cause of the murmur is unclear and was not evidenced on color flow assessment. There is no contraindication to anesthetic procedure. If the murmur is persistently present over the next year then a recheck sonogram is recommended in a year. Normal laminar flow was demonstrated in all valvular structures.

**SPECIES**

Canine

**BREED**

Shiba Inu

**SEX**

Intact male

**AGE**

11 months

**WEIGHT**

23 lbs

**INTERPRETED BY**

Eric Lindquist, DMV  
DABVP, Cert. IVUSS

**IMAGING PERFORMED BY**

Dr. Mandeville

**HOSPITAL NAME**

BetterVet

**REFERRING VET**

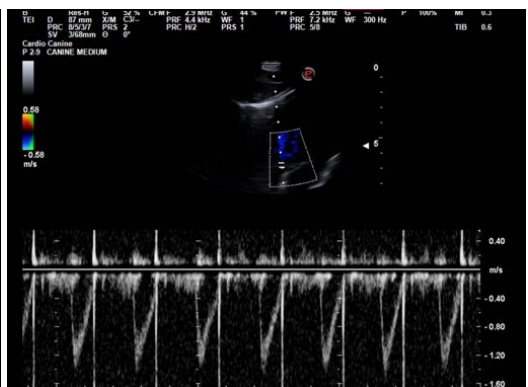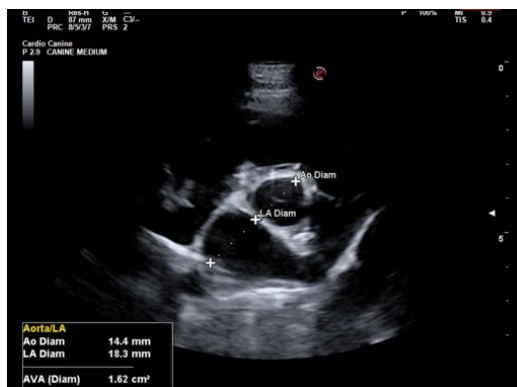
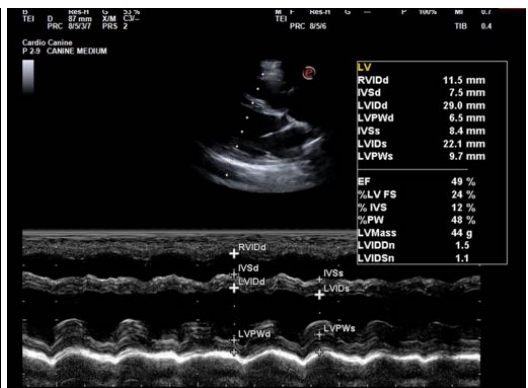
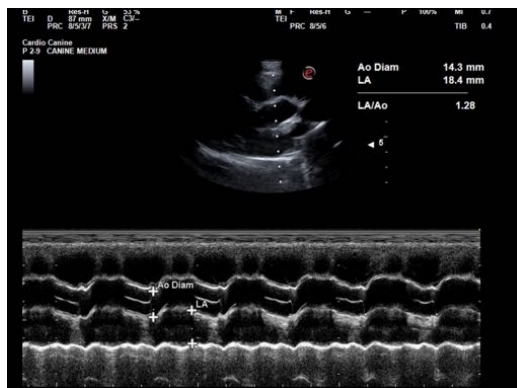
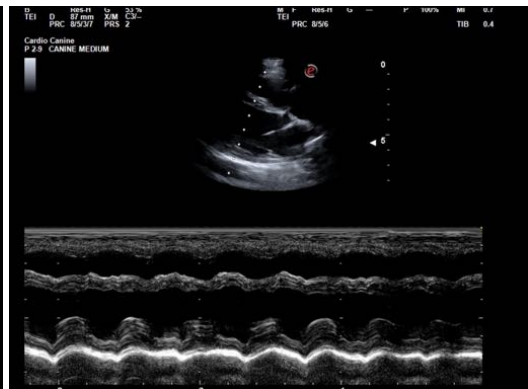
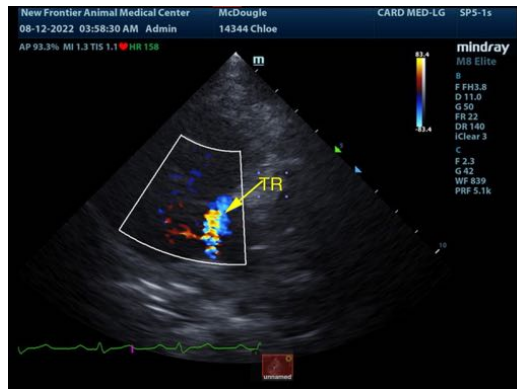Dr. Mandeville

**INVOICE**

32321

**DATE**

8/11/22





**PATIENT**

Miso Shi

**SPECIES**

Canine

**BREED**

Shiba Inu

**SEX**

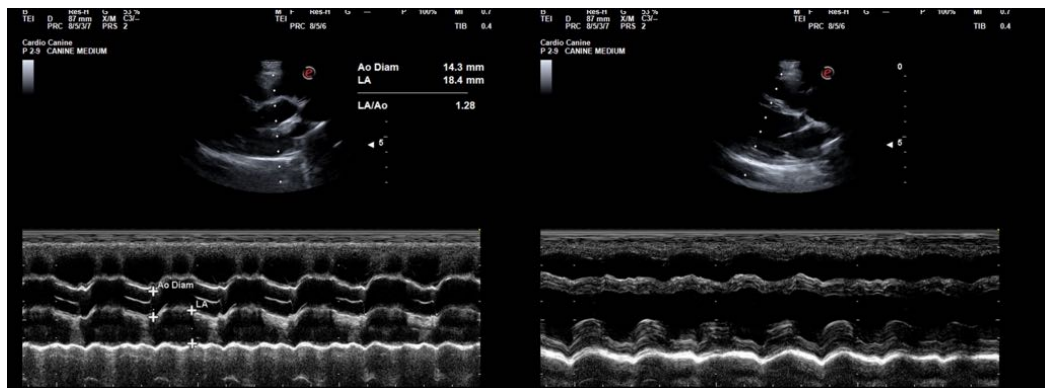
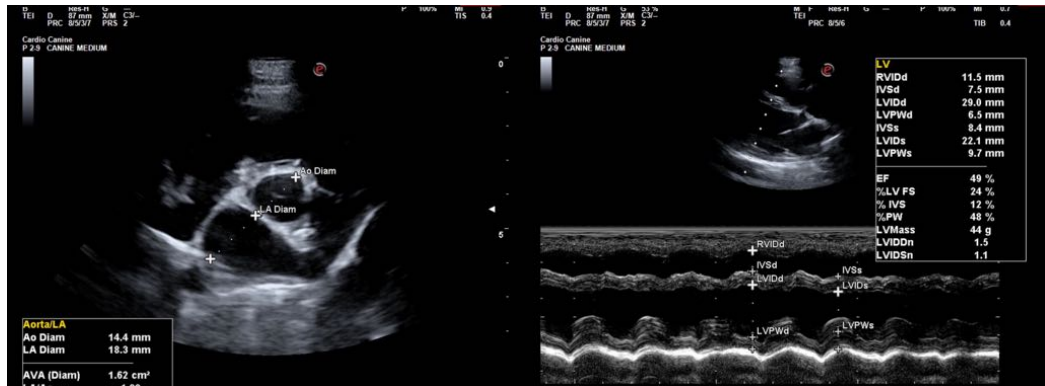
Intact male

**AGE**

11 months

**WEIGHT**

23 lbs



**INTERPRETED BY**

Eric Lindquist, DMV  
DABVP, Cert. IVUSS

**IMAGING PERFORMED BY**

Dr. Mandeville

**HOSPITAL NAME**

BetterVet

**REFERRING VET**

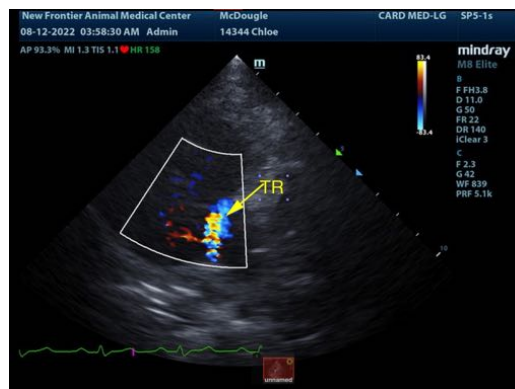
Dr. Mandeville

**INVOICE**

32321

**DATE**

8/11/22



The information and recommendations provided are based on the images presented by the referring veterinarian/sonographer. No evaluation can be communicated regarding pathology that was not visible in the image/video clips provided.

Thank you for this referral. If the clinical or image interpretation does not parallel your findings or if it can be of any further assistance please contact me.

**Eric Lindquist, DMV, DABVP, Cert. IVUSS, CEO of SonoPath.com**  
info@SonoPath.com