



**PATIENT**

Brody Tuber

**PRESENTING CLINICAL SIGNS**

History: searching for thyroid gland due to hyperthyroidism

**SPECIES**

Canine

**ULTRASONOGRAPHIC EXAMINATION OF THE THYROID**

The left and right thyroid lobes were visualized directly and obliquely. The parathyroids are not visualized. The contour of the thyroid was normal. The thyroid width was approximately 0.5 cm. The visible esophagus, trachea and salivary glands appeared unremarkable. There was no evidence of masses.

**BREED**

Cavachon

**SEX**

Neutered male

**ULTRASONOGRAPHIC FINDINGS**

**INTERPRETATION OF THE FINDINGS & FURTHER RECOMMENDATIONS**

Based on this image set the thyroid gland appears normal with no evidence of pathology. Neck meat ingestion in the patient's diet or ectopic thyroid production should be considered. However, there was no evidence of pathology in the region of the thyroid lobes.

**WEIGHT**

22.1 lbs

**INTERPRETED BY**

Eric Lindquist, DMV  
DABVP, Cert. IVUS

**IMAGING PERFORMED BY**

Dr. Barnea

**HOSPITAL NAME**

Tenafly VC

**REFERRING VET**

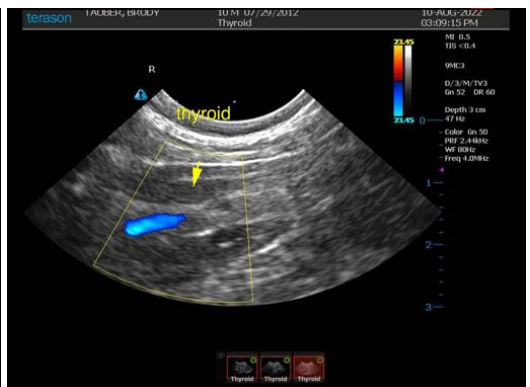
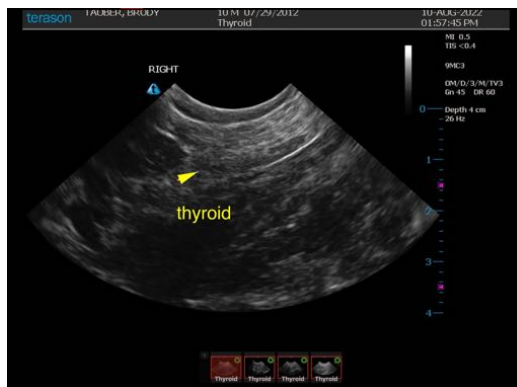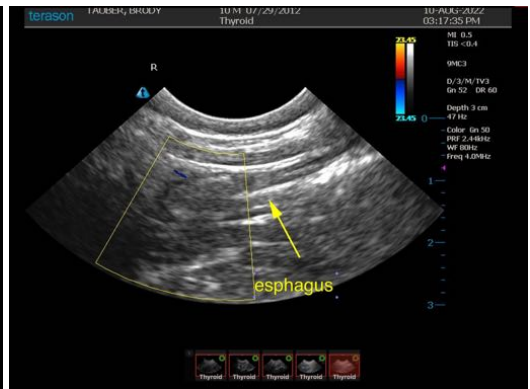
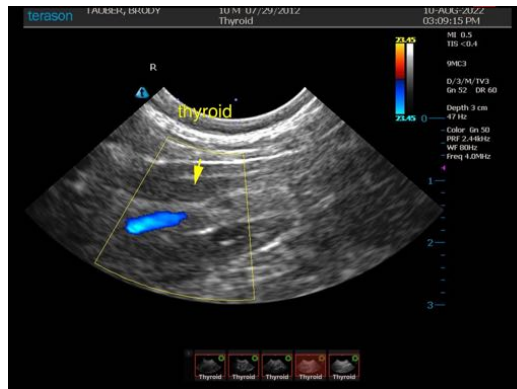
Dr. Barnea

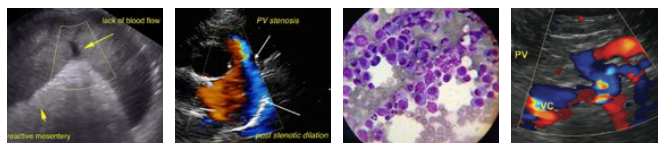
**INVOICE**

32308

**DATE**

8/11/22





**PATIENT**

Brody Tuber

**SPECIES**

Canine

**BREED**

Cavachon

**SEX**

Neutered male

**AGE**

10 years

**WEIGHT**

22.1 lbs

**INTERPRETED BY**

Eric Lindquist, DMV  
DABVP, Cert. IVUSS

**IMAGING  
PERFORMED BY**

Dr. Barnea

**HOSPITAL NAME**

Tenafly VC

**REFERRING VET**

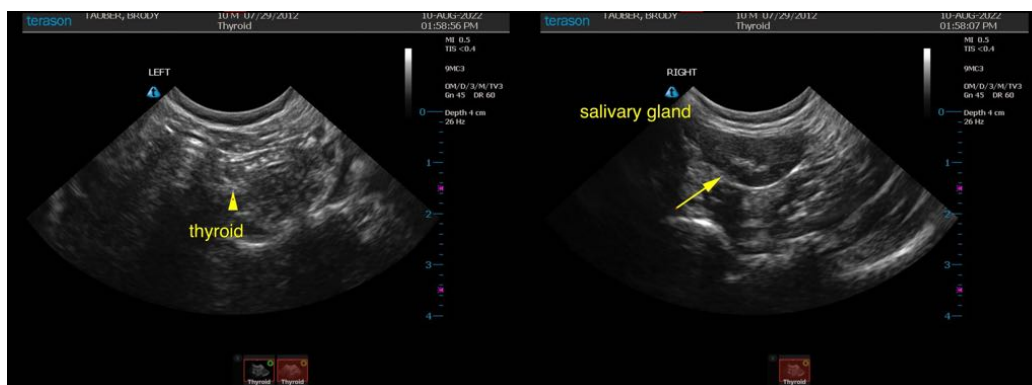
Dr. Barnea

**INVOICE**

32308

**DATE**

8/11/22



The information and recommendations provided are based on the images presented by the referring veterinarian/sonographer. No evaluation can be communicated regarding pathology that was not visible in the image/video clips provided.

Thank you for this referral. If the clinical or image interpretation does not parallel your findings or if I can be of any further assistance please contact me.

**Eric Lindquist**, DMV, DABVP, Cert. IVUSS, CEO of SonoPath.com  
info@SonoPath.com