



**PATIENT**

Leela Nelson

**PRESENTING CLINICAL SIGNS**

History: Chronic vomiting/regurgitating undigested food. Rads show no megaesophagus. No current meds.

**SPECIES**

Feline

**ULTRASONOGRAPHIC EXAMINATION OF THE ABDOMEN**

**Urinary System**

**BREED**

Domestic Shorthair

The **urinary bladder**, trigone, and pelvic urethra presented normal thicknesses and normal tone. The ureters were not visible which is normal. No uroliths or sediment were visualized and anechoic urine was present. No evidence of inflammatory or neoplastic changes was noted. Ureteral papillae were normal.

**SEX**

Spayed Female

The **kidneys** revealed normal size and structure, corticomedullary definition and ratio for this age. The cortices presented largely uniform texture with normal echogenic relationship to liver and spleen. Medullary structure differed distinctly from the cortex and no evidence of pelvic dilation was present. The capsules were acceptably uniform without significant irregularities. The left kidney measured 3.36 cm. The right kidney measured 3.54 cm.

**AGE**

3 years

**WEIGHT**

10 lbs

**Adrenal Glands**

Both **adrenal glands** were visualized and recognized as having normal shape, size, position and echogenicity for this breed. The phrenic vasculature, glandular echogenicity and detail were unremarkable. Capsule, cortex, and medullary definition were normal for this age patient. The right adrenal gland measured 0.34 cm. The left adrenal gland measured 0.29 cm.

**INTERPRETED BY**

Eric Lindquist, DMV  
DABVP, Cert. IVUSS

**Spleen**

The **spleen** was at the upper limits of normal and measured 0.94 cm with slight scalloping contour.

**IMAGING**

**PERFORMED BY**

Shari Reffi, CVT

**Liver**

**HOSPITAL NAME**

Animal General on  
Hudson

The **liver** images submitted revealed subjectively normal liver size, contour, and structure. Parenchymal echogenicity was naturally coarse and hypoechoic to the spleen. Vascular and biliary tracts were of normal volume with no evidence of congestion. The gallbladder presented acceptably thin walls with primarily anechoic content. The cystic and common bile ducts were normal. No pathological hepatic lymphadenopathy was evident. No overt structural evidence of inflammatory, infiltrative or regenerative pathology was evident.

**REFERRING VET**

Dr. Lang

**INVOICE**

91133

**Gastrointestinal**

Examination of the **gastrointestinal tract** revealed a stomach and intestine free of stasis, of normal wall thickness, acceptable curvilinear mural detail, and peristaltic activity. The stomach was followed to the gastroesophageal inlet and there was no evidence of pathology in this region. Small and large intestine

**DATE**

8/11/21



**PATIENT**

demonstrated normal luminal chyme and stool consistency respectively. No obstructive or overt infiltrative disease was noted. No associated abnormal lymphatic activity was noted.

Leela Nelson

**SPECIES**

**Pancreas**

Feline

The base and limbs of the **pancreas** were observed to be largely isoechoic to surrounding omental fat. Pancreatic duct and capsular contour were acceptably normal and parenchyma respected normal curvilinear patterns. No overt evidence of active inflammatory or neoplastic disease was noted.

**BREED**

Domestic Shorthair

**Free Abdomen**

**SEX**

A large amount of falciform fat was noted in this patient.

Spayed Female

**ULTRASONOGRAPHIC FINDINGS**

**AGE**

Structurally unremarkable abdomen.

3 years

Minor splenic enlargement.

**WEIGHT**

10 lbs

**INTERPRETATION OF THE FINDINGS & FURTHER RECOMMENDATIONS**

There was no evidence of visceral disease based on the abdominal sonogram. Endoscopy is warranted if the clinical signs are not improving on diet change. Supportive gastrointestinal care is recommended. If any weight loss is an issue FNA is indicated to ensure that an emerging neoplastic event such as lymphoma is not an issue.

**INTERPRETED BY**

Eric Lindquist, DMV  
DABVP, Cert. IVUSS

**IMAGING PERFORMED BY**

Shari Reffi, CVT

**HOSPITAL NAME**

Animal General on Hudson

**REFERRING VET**

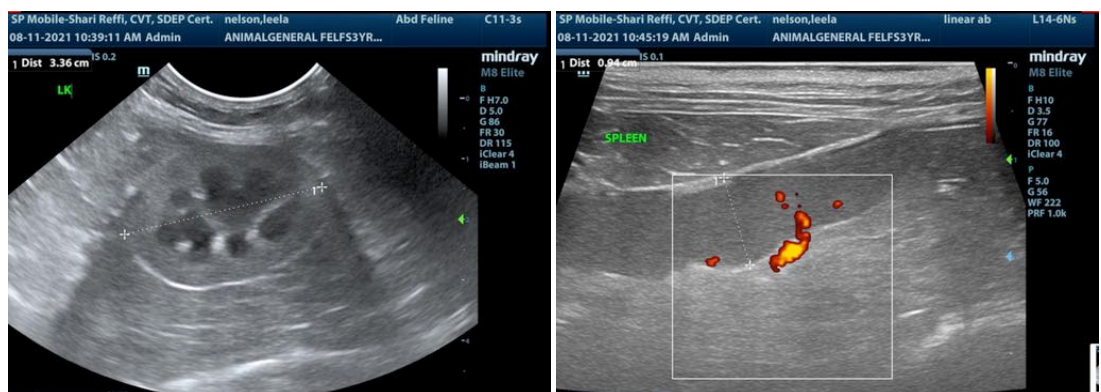
Dr. Lang

**INVOICE**

91133

**DATE**

8/11/21





**PATIENT**

Leela Nelson

**SPECIES**

Feline

**BREED**

Domestic Shorthair

**SEX**

Spayed Female

**AGE**

3 years

**WEIGHT**

10 lbs

**INTERPRETED BY**

Eric Lindquist, DMV  
DABVP, Cert. IVUSS

**IMAGING PERFORMED BY**

Shari Reffi, CVT

**HOSPITAL NAME**

Animal General on  
Hudson

**REFERRING VET**

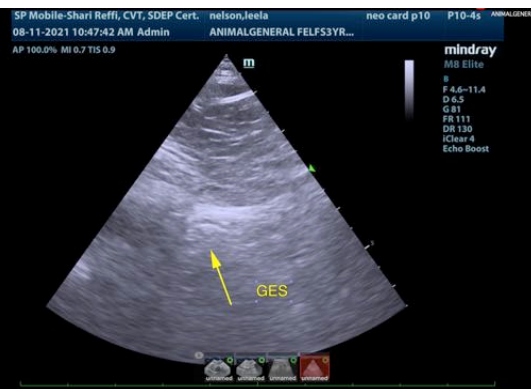
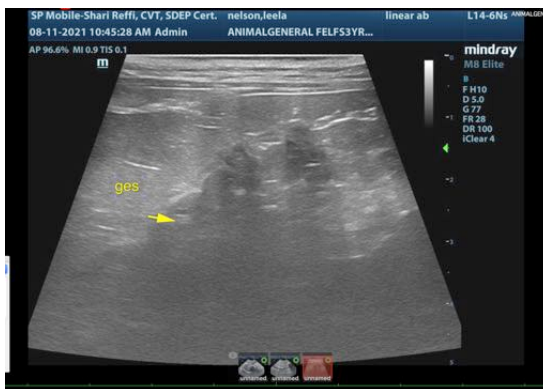
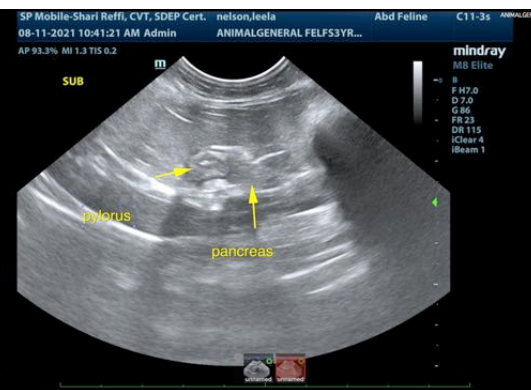
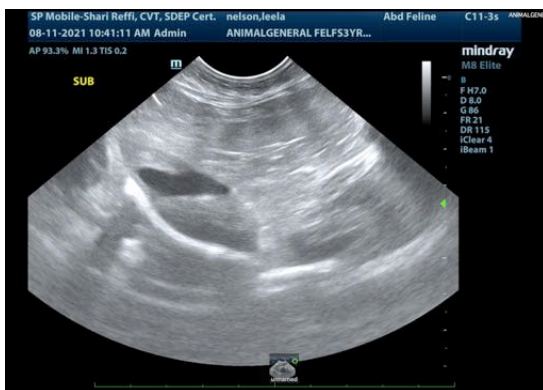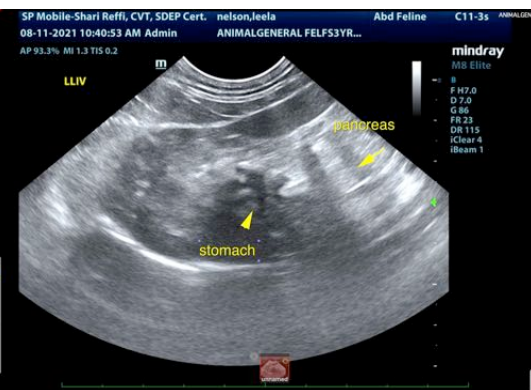
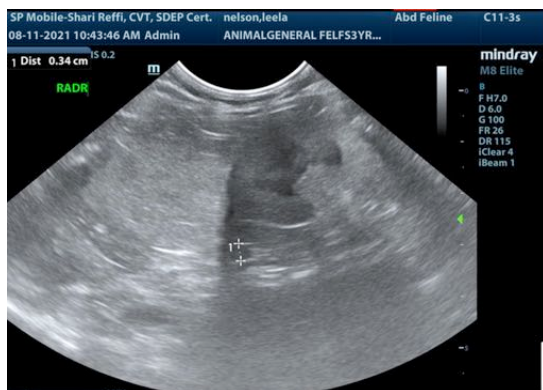Dr. Lang

**INVOICE**

91133

**DATE**

8/11/21



The information and recommendations provided are based on the images presented by the referring veterinarian. No evaluation can be communicated regarding pathology that was not visible in the image/video clips provided.

Thank you for this referral. If the clinical or image interpretation does not parallel your findings or if I can be of any further assistance please contact me.

Eric Lindquist, DMV, DABVP, Cert. IVUSS, CEO of SonoPath.com  
Info@SonoPath.com