

**DATE PRESENTING CLINICAL SIGNS**

8/10/23

Rechecking caudal abdominal lymphadenopathy- if still abnormal/enlarged will then schedule for surgical biopsy. Clinically he is doing well.

**PATIENT**

Sawyer Munko

Current Medications: None.

Date of Previous IntraPet Ultrasound: 7/10/23. See attached. And 2/16/23.

Sedation: Not required to complete full diagnostic ultrasound.

Stat Report: Not requested.

Imaging Performed By: Rachel Brillhart, RDMS.

**SPECIES**

Canine

**LIMITED ULTRASONOGRAPHIC EXAMINATION****BREED**

Golden Retriever

The urinary bladder, trigone, and pelvic urethra presented normal thicknesses and normal tone. The ureters were not visible which is normal. No uroliths or sediment were visualized and anechoic urine was present. No evidence of inflammatory or neoplastic changes were noted. Ureteral papillae were normal. The pelvic urethra was imaged 2.0 cm beyond the cystourethral junction.

**SEX**

Neutered Male

The kidneys presented normal size and contour. The right kidney measured 7.08 cm. The left kidney measured 7.1 cm. No significant pyelectasia noted, this appears to have resolved.

**AGE**

1/17/22

Mesenteric lymph nodes were persistently enlarged, yet length to width ratio was maintained at 3.2 cm x 0.93 cm in the largest node. However, smaller nodes are also enlarged.

**WEIGHT**

82 Pounds

Sublumbar lymph nodes were also enlarged, reactive, measuring 1.72 cm x 0.77 c.

**INTERPRETED BY**

Eric Lindquist, DMV  
DABVP, Cert. IVUSS

**ULTRASONOGRAPHIC FINDINGS**

- Lymphadenopathy – reactive pattern with mesenteric root and sublumbar lymph nodes.

**INTERPRETATION OF THE FINDINGS & FURTHER RECOMMENDATIONS****HOSPITAL NAME**

Stay Pet Vet

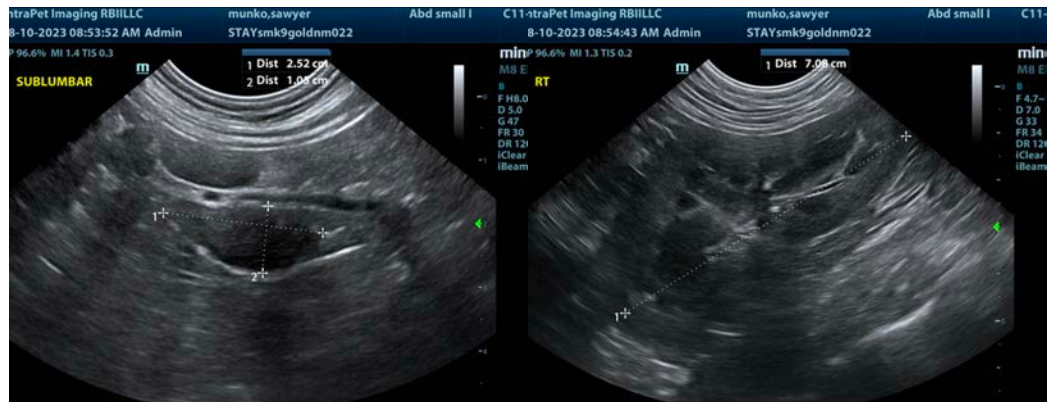
FNA cytology and culture indicated. No overt neoplastic criteria present. However, given the long-term enlargement of the lymph nodes, cytology and culture would be warranted to further define the changes.

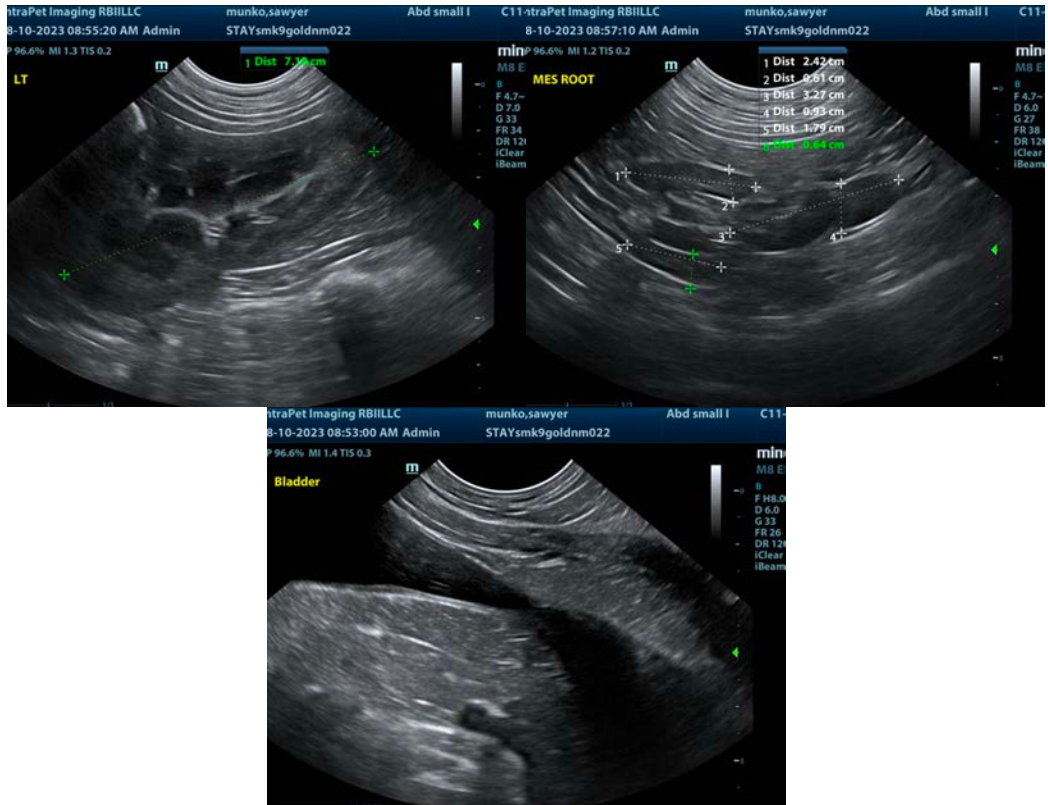
**REFERRING VET**

Dr. Klimovitz

**INVOICE**

44595





The information and recommendations provided are based on the images presented by the referring veterinarian/sonographer. No evaluation can be communicated regarding pathology that was not visible in the image/video clips provided.

Thank you for this referral. If the clinical or image interpretation does not parallel your findings or if I can be of any further assistance please contact me.

**Eric Lindquist**, DMV, DABVP, Cert. IVUSS, CEO of SonoPath.com  
[info@SonoPath.com](mailto:info@SonoPath.com)