

**DATE PRESENTING CLINICAL SIGNS**

8/10/23 Lethargy mild to moderate, and reluctant to go down or up steps. appetite and water intake are normal. azotemia and elevated liver value on labwork

**PATIENT**

Ruffles Galliano

Current Medications: None.

Lab Results: elevated SDMA and BUN, proteinuria, elev ALP. 4dx negative.

Radiographs: Poss IVDD, rest WNL.

**SPECIES**

Canine

Date of Previous IntraPet Ultrasound: No previous.

Sedation: Not required to complete full diagnostic ultrasound.

Stat Report: Not requested.

Imaging Performed By: Rachel Brillhart, RDMS.

**BREED**

Cocker Spaniel

**ULTRASONOGRAPHIC EXAMINATION OF THE ABDOMEN****SEX**

Spayed Female

**Urinary System**

The **urinary bladder**, trigone, and pelvic urethra presented normal thicknesses and normal tone. The ureters were not visible which is normal. No uroliths or sediment were visualized and anechoic urine was present. No evidence of inflammatory or neoplastic changes were noted. Ureteral papillae were normal.

**AGE**

4/21/20

The **kidneys** revealed normal size and structure, corticomedullary definition and ratio for this age. The cortices presented largely uniform texture with normal echogenic relationship to liver and spleen. Medullary structure differed distinctly from the cortex and no evidence of pelvic dilation was present. The capsules were acceptably uniform without significant irregularities. The right kidney measured 4.81 cm. The left kidney measured 4.91 cm.

**WEIGHT**

34 Pounds

**Adrenal Glands****INTERPRETED BY**Eric Lindquist, DMV  
DABVP, Cert. IVUSS

Both **adrenal glands** were visualized and recognized as having normal shape, size, position and echogenicity for this breed. The phrenic vasculature, glandular echogenicity and detail were unremarkable. Capsule, cortex, and medullary definition were normal for this age patient. The left adrenal gland measured 1.6 cm x 0.54 cm at the caudal pole and 0.51 cm at the cranial pole. The right adrenal gland measured 1.86 cm x 0.48 cm at the caudal pole and 0.53 cm at the cranial pole.

**HOSPITAL NAME**

Stay Pet Veterinary

**Spleen**

The **spleen** presented a smooth homogeneous parenchyma hyperechoic to liver and renal cortical parenchyma. The capsule was smooth without noticeable expansion or deviation from within the spleen or adjacent pathology. The splenic vasculature demonstrated normal volume without signs of congestion or thrombosis. No sonographic evidence of acute or chronic inflammatory, neoplastic, or infarctual changes were noted.

**REFERRING VET**

Dr. Klimovitz

**INVOICE**

44600

**Liver**

The **liver** images submitted revealed subjectively normal liver size, contour, and structure. Parenchymal echogenicity was naturally coarse and hypoechoic to the spleen. Vascular and biliary tracts were of normal volume with no evidence of congestion. The gallbladder presented acceptably thin walls with primarily anechoic content. The cystic and common bile ducts were normal. No pathological hepatic lymphadenopathy was evident. No overt structural evidence of inflammatory, infiltrative or regenerative pathology was evident.

### ***Gastrointestinal***

Examination of the **gastrointestinal tract** revealed a stomach and intestine free of stasis, of normal wall thickness, acceptable curvilinear mural detail, and peristaltic activity. Small and large intestine demonstrated normal luminal chyme and stool consistency respectively. No obstructive or overt infiltrative disease was noted. No associated abnormal lymphatic activity was noted.

### ***Pancreas***

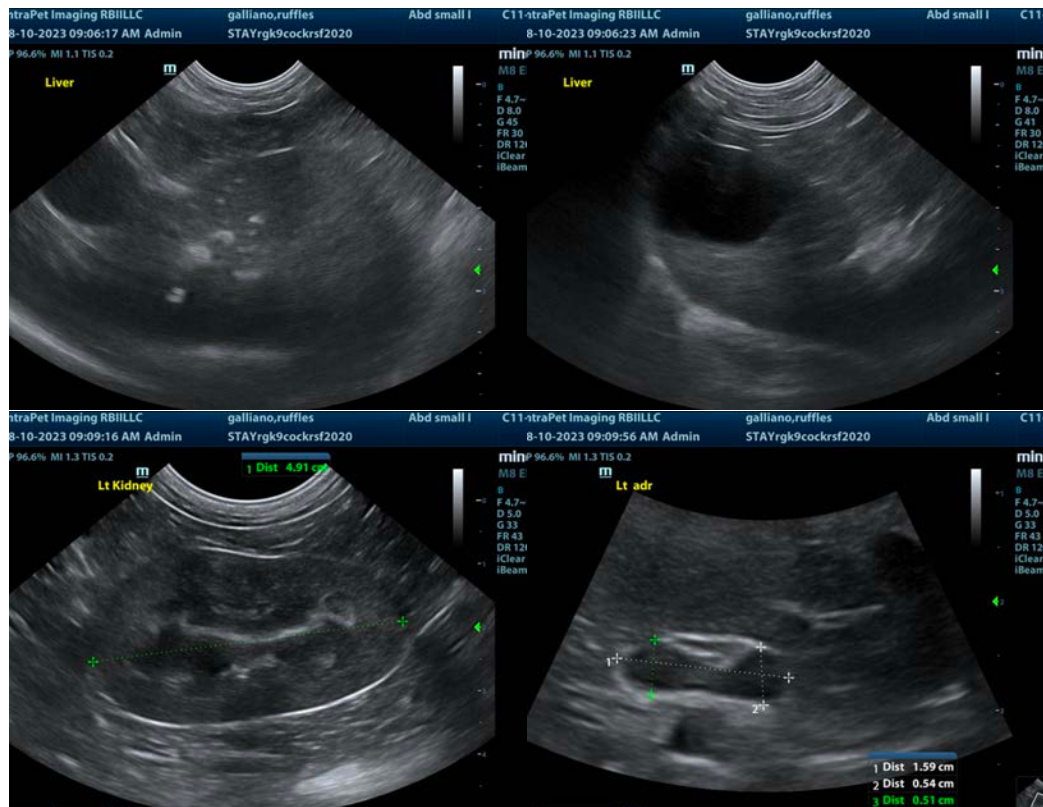
Slight heterogeneous **pancreatic** changes noted. Subxiphoid palpation is recommended to assess for pain or discomfort associated with the pancreas.

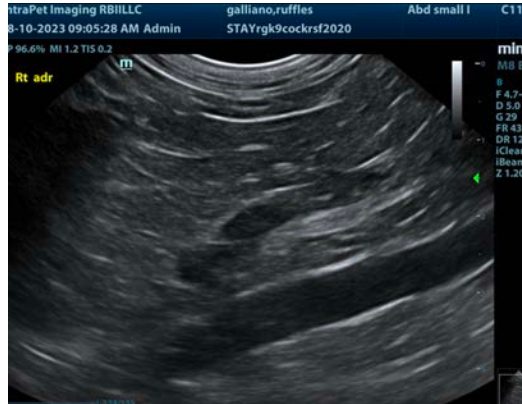### **ULTRASONOGRAPHIC FINDINGS**

- Structurally normal abdomen with slight heterogeneous pancreatic changes

### **INTERPRETATION OF THE FINDINGS & FURTHER RECOMMENDATIONS**

No evidence of visceral pathology responsible for the clinical signs. Other causes of the clinical signs such as orthopedic disease should be considered.





**The information and recommendations provided are based on the images presented by the referring veterinarian/sonographer. No evaluation can be communicated regarding pathology that was not visible in the image/video clips provided.**

Thank you for this referral. If the clinical or image interpretation does not parallel your findings or if I can be of any further assistance please contact me.

**Eric Lindquist**, DMV, DABVP, Cert. IVUSS, CEO of SonoPath.com  
[info@SonoPath.com](mailto:info@SonoPath.com)