



PATIENT

Tia Lucy Strelec

SPECIES

Canine

BREED

Bichon Mix

SEX

Spayed female

AGE

9 months

WEIGHT

12 lbs

INTERPRETED BY

Eric Lindquist, DMV
DABVP, Cert. IVUSS

IMAGING PERFORMED BY

Jenn

HOSPITAL NAME

Rockaway AH

REFERRING VET

Dr. Ascot

INVOICE

32264

DATE

8/9/22

PRESENTING CLINICAL SIGNS

History: intermittent fever post op OVH hyporexia Current meds Metacam
Abnormal PE/Chem/CBC/UA Results: WBC 18K Neutro 14.6K Mono 1.59K Glu 73 remainder WNL
U/A normal SG 1.031

ULTRASONOGRAPHIC EXAMINATION OF THE ABDOMEN

Urinary System

The **urinary bladder**, trigone, and pelvic urethra presented normal thicknesses and normal tone. The ureters were not visible which is normal. No uroliths or sediment were visualized and anechoic urine was present. No evidence of inflammatory or neoplastic changes was noted. Ureteral papillae were normal.

The **kidneys** revealed normal size and structure, corticomedullary definition and ratio for this age. The cortices presented largely uniform texture with normal echogenic relationship to liver and spleen. Medullary structure differed distinctly from the cortex and no evidence of pelvic dilation was present. The capsules were acceptably uniform without significant irregularities. The right kidney measured 4.31 cm.

Adrenal Glands

Both **adrenal glands** were visualized and recognized as having normal shape, size, position and echogenicity for this breed. The phrenic vasculature, glandular echogenicity and detail were unremarkable. Capsule, cortex, and medullary definition were normal for this age patient. The right adrenal gland measured 1.28 x 0.35 cm at the caudal pole and 0.45 cm at the cranial pole. The left adrenal gland measured 1.76 x 0.35 cm at the caudal pole and 0.47 cm at the cranial pole.

Spleen

The **spleen** presented a smooth homogeneous parenchyma hyperechoic to liver and renal cortical parenchyma. The capsule was smooth without noticeable expansion or deviation from within the spleen or adjacent pathology. The splenic vasculature demonstrated normal volume without signs of congestion or thrombosis. No sonographic evidence of acute or chronic inflammatory, neoplastic, or infarctual changes was noted.

Liver

The **liver** images submitted revealed subjectively normal liver size, contour, and structure. Parenchymal echogenicity was naturally coarse and hypoechoic to the spleen. Vascular and biliary tracts were of normal volume with no evidence of congestion. The gallbladder presented acceptably thin walls with primarily anechoic content. The cystic and common bile ducts were normal. No pathological hepatic lymphadenopathy was evident. No overt structural evidence of inflammatory, infiltrative or regenerative pathology was evident.



PATIENT

Gastrointestinal

Tia Lucy Strelec

There was some residual chyme and gas was noted in the **stomach**, yet not pathological. This is consistent with end post prandial presentation. Transit of chyme into the small intestine was normal. Curvilinear patterns were maintained throughout the GI tract. No evidence of pathology. Small and large intestine demonstrated normal luminal chyme and stool consistency respectively. No obstructive or overt infiltrative disease was noted. No associated abnormal lymphatic activity was noted.

SPECIES

Canine

BREED

Pancreas

Bichon Mix

The base and limbs of the **pancreas** were observed to be largely isoechoic to surrounding omental fat. Pancreatic duct and capsular contour were acceptably normal and parenchyma respected normal curvilinear patterns. No overt evidence of active inflammatory or neoplastic disease was noted.

SEX

Spayed female

ULTRASONOGRAPHIC FINDINGS

AGE

Structurally normal abdomen.

9 months

INTERPRETATION OF THE FINDINGS & FURTHER RECOMMENDATIONS

WEIGHT

There was no evidence of post surgery residual pathology.

12 lbs

INTERPRETED BY

Eric Lindquist, DMV
DABVP, Cert. IVUS

IMAGING PERFORMED BY

Jenn

HOSPITAL NAME

Rockaway AH

REFERRING VET

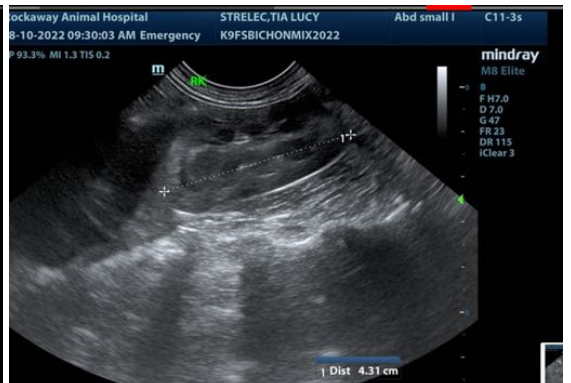
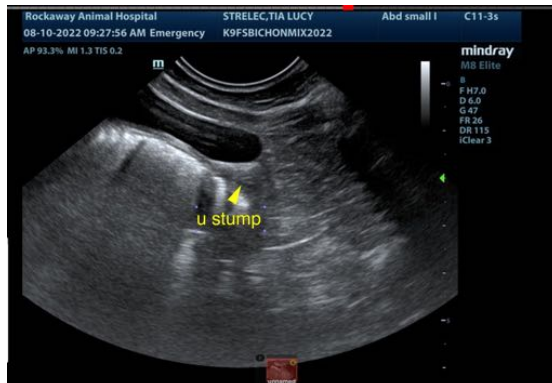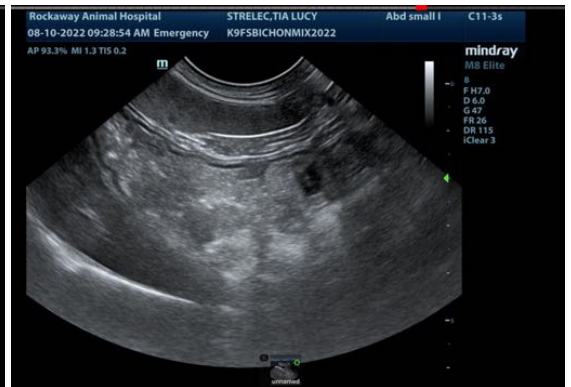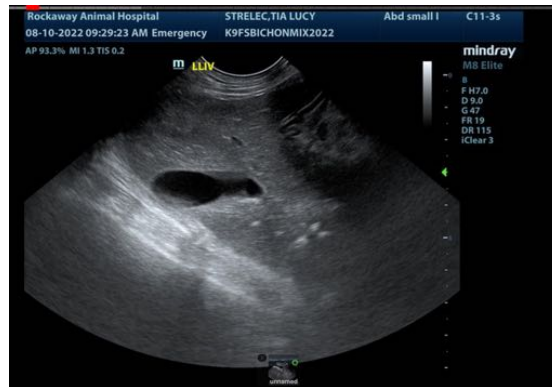
Dr. Ascot

INVOICE

32264

DATE

8/9/22





PATIENT

Tia Lucy Strelec

SPECIES

Canine

BREED

Bichon Mix

SEX

Spayed female

AGE

9 months

WEIGHT

12 lbs

INTERPRETED BY

Eric Lindquist, DMV
DABVP, Cert. IVUSS

IMAGING PERFORMED BY

Jenn

HOSPITAL NAME

Rockaway AH

REFERRING VET

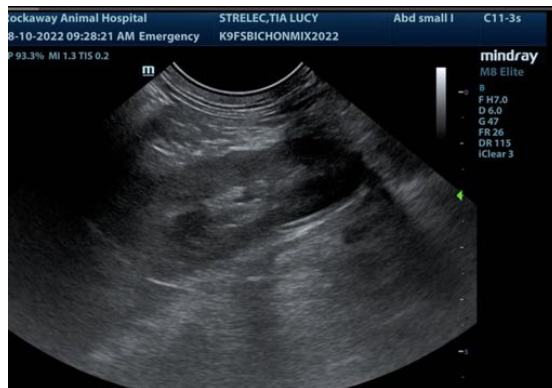
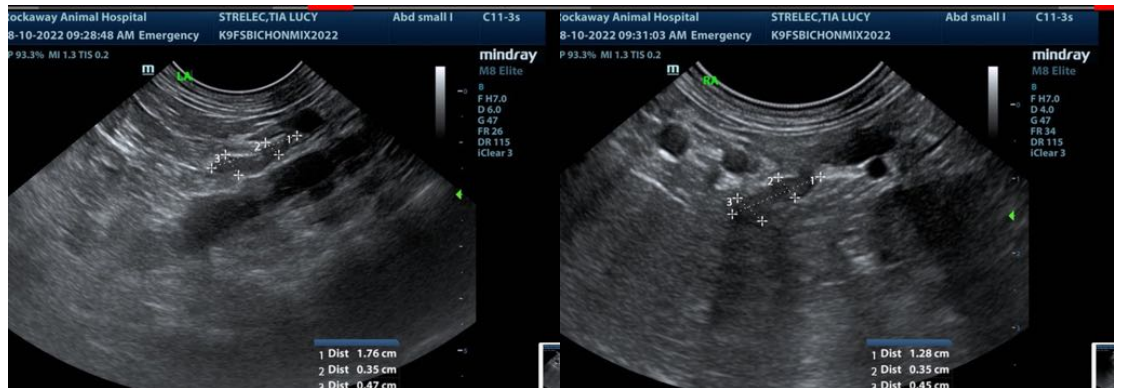
Dr. Ascot

INVOICE

32264

DATE

8/9/22



The information and recommendations provided are based on the images presented by the referring veterinarian/sonographer. No evaluation can be communicated regarding pathology that was not visible in the image/video clips provided.

Thank you for this referral. If the clinical or image interpretation does not parallel your findings or if I can be of any further assistance please contact me.

Eric Lindquist, DMV, DABVP, Cert. IVUSS, CEO of SonoPath.com
info@SonoPath.com





PATIENT

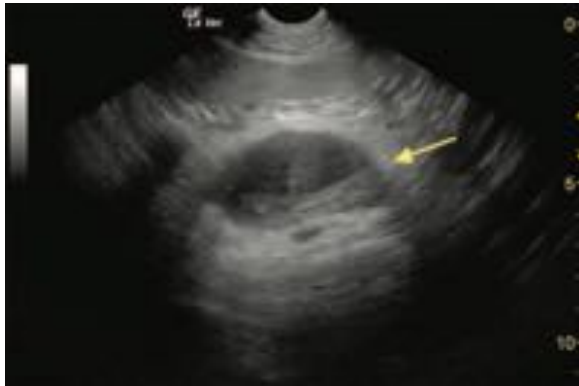
Tia Lucy Strelec

SPECIES

Canine

BREED

Bichon Mix



Long axis of the mid-abdomen in a dog with an omental abscess after foreign body penetration from the gastrointestinal tract. The hypoechoic necrotic center of the lesion is surrounded by a thick echogenic capsule and hyperechoic mesenteric fat (arrow) indicating focal peritonitis. The linear echogenic needle (5 cm depth) is barely visible owing to the density of the purulent material contained within the abscess.

SEX

Spayed female

AGE

9 months

WEIGHT

12 lbs

INTERPRETED BY

Eric Lindquist, DMV
DABVP, Cert. IVUSS

IMAGING PERFORMED BY

Jenn

HOSPITAL NAME

Rockaway AH

REFERRING VET

Dr. Ascot

INVOICE

32264

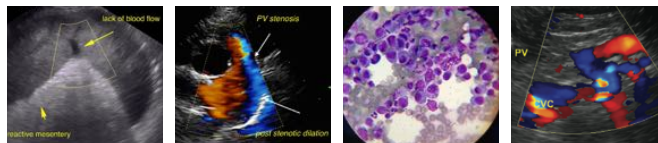
DATE

8/9/22

Description: The definition of a fever of unknown origin (FUO) has not been clearly defined for animals. Currently, it is either understood to be a fever that does not resolve within the period one would expect for a “self-limiting infection” being treated with appropriate antimicrobial therapy, or that for which an underlying diagnosis has not been determined despite considerable diagnostic effort. The common causes of FUO were summarized concisely in a presentation at the American College of Veterinary Internal Medicine 2004 Forum. The presenters synthesized information from three veterinary papers on the subject, which suggested the following:

Final Diagnosis	Bennett (dogs & cats)	Dunn and Dunn (dogs only)	Lunn (dogs & one cat)	Total
Infection	21	16	10	47
Immune	18	22	6	46
Bone marrow disease	4	22	2	28
Neoplasia (outside marrow)	0	10	2	12
Miscellaneous	2	12	2	16
No diagnosis	0	19	2	21
TOTALS	45	101	24	170

The types of infection diagnosed in this case series were varied, ranging from discospondylitis (8 cases), blastomycosis (6), and bacterial endocarditis (4), to leishmaniasis (1), prostatitis (1), and *Ehrlichia canis* infection (1); a multitude of other infectious causes also fell within the spectrum. Of the cases in which immune-mediated disease was found, 44% had immune-mediated



PATIENT

Tia Lucy Strelec

polyarthritis. Bone marrow diseases included myeloproliferative disease, myelodysplasia (8), lymphocytic leukemia (8), myeloma (3), chronic granulocytic leukemia (3), lymphoblastic leukemia, and malignant histiocytosis. The types of neoplasia located outside the bone marrow included lymphoma (6), metastatic disease (2), and neoplasms of the lung, spleen, and stomach. Finally, miscellaneous diseases included hypertrophic osteodystrophy (6), meningitis (3), portosystemic shunt (3), lymphadenitis (2), panosteitis, and intervertebral disc disease. Overall, the most common causes across all cases were polyarthritis (44), lymphoid neoplasia (15), discospondylitis (8), myelodysplasia (8), hypertrophic osteodystrophy (6), and blastomycosis (6).

SPECIES

Canine

BREED

Bichon Mix

SEX

Spayed female

AGE

9 months

WEIGHT

12 lbs

INTERPRETED BY

Eric Lindquist, DMV
DABVP, Cert. IVUS

IMAGING PERFORMED BY

Jenn

HOSPITAL NAME

Rockaway AH

REFERRING VET

Dr. Ascot

INVOICE

32264

DATE

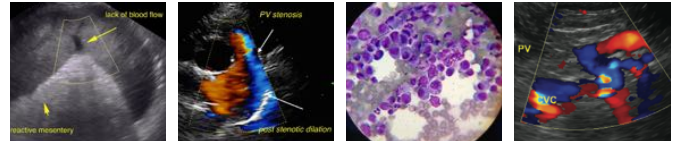
8/9/22

Clinical Signs: Animals usually present with either persistent or waxing and waning fevers ranging from 103°F to 106°F. Other clinical signs depend on the underlying cause of the fever. Careful and thorough physical examination is required to assess potential causes.

Diagnostics: FUO etiologies are partly related to geography, and thus locale or travel history should factor into a practitioner's diagnostic approach. A patient's lifestyle may also provide clues regarding exposure to certain etiologic agents. Therefore, conducting a thorough history can unveil important pieces of the diagnostic puzzle. Physical examination is especially important and should include an inspection of all accessible lymph nodes, palpation and movement of the joints, a fundic examination, a neurological evaluation, spinal and limb palpation and range of motion tests, and a rectal examination.

A minimum database should include a CBC reviewed by a clinical pathologist, as well as a biochemical profile and urinalysis. Retroviral testing should also be considered in cats. In areas where tick-borne disease is prevalent, in-house testing should be performed early. Advanced laboratory work can include: urine culture, blood culture, and infectious disease panels (PCR and/or serology). In dogs, one may screen for the following infectious agents: *Ehrlichia* spp., *Borrelia burgdorferi*, Rock Mountain Spotted Fever, *Bartonella* spp. (culture and PCR), and *Leptospira* spp. in cases of hepatic or renal involvement. In cats, one should evaluate for FeLV, FIV, feline infectious peritonitis (FIP) virus, toxoplasmosis, *Hemoplasma* spp. (*Mycoplasma*), and *Bartonella* spp. (culture and PCR). Testing for *Ehrlichia* spp., *Rickettsia* spp., and *Anaplasma phagocytophilum* can also be considered. A fungal assay is indicated if the patient lives in or has had exposure to a region with a higher incidence of fungal disease. Other infectious disease tests may be performed depending on the geographical location of the pet. Screening for *Brucella* should be done in breeding dogs. Immune-mediated disease screening can include a Coomb's test, a slide agglutination test (if the patient is anemic), and an antinuclear antibody (ANA) test. Immune disease is often a diagnosis of exclusion.

Imaging should include thoracic radiographs, abdominal ultrasound, and/or abdominal radiographs. Ultrasound can be very useful for assessing evidence of cholangiohepatitis, pyelonephritis, chronic urinary tract infection, abscess formation, peritonitis, and neoplasia; it also permits an examination of the intra-abdominal lymph nodes. An echocardiogram can offer assessment for vegetative endocarditis, whereas spinal radiographs offer assessment for discospondylitis. In cases where all other testing has proven negative and the patient has not responded to broad-spectrum antibiotics and supportive care, arthrocentesis should be considered to evaluate for septic joint disease, immune-mediated polyarthritis, and infectious disease. Finally, one can consider assessing the cerebrospinal fluid for meningoencephalitis,



PATIENT

GME, and meningitis/arteritis. A bone marrow exam should be performed if blood dyscrasias are noted on the CBC.

Tia Lucy Strelec

SPECIES

Treatment: Treatment of the fever depends entirely on the underlying cause. Ideally, a thorough diagnostic plan will yield a diagnosis that will guide the appropriate therapeutic course. However, if an exhaustive approach has not produced a definitive diagnosis and there is no response to broad-spectrum antibiotics, trial therapy with immunosuppressive agents such as prednisolone can be considered to treat presumed immune-mediated diseases. Given the potential for negative sequelae should an underlying infection be present, one must be certain that the investigation is thorough and monitor the patient's response carefully.

Canine

BREED

Bichon Mix

SEX

Conclusion: If a documented fever has not responded to antibiotics, antipyretics, or general nursing care, it is important to obtain a diagnosis to guide more specific treatment. A systematic physical examination and thorough history-taking will help inform further diagnostics in addition to what is revealed by the minimum database.

Spayed female

AGE

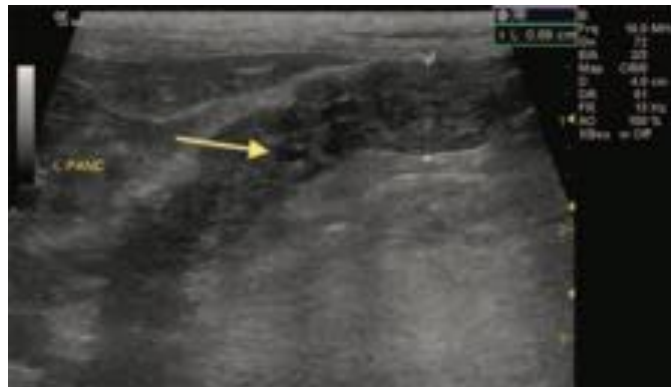
9 months

WEIGHT

12 lbs

INTERPRETED BY

Eric Lindquist, DMV
DABVP, Cert. IVUSS



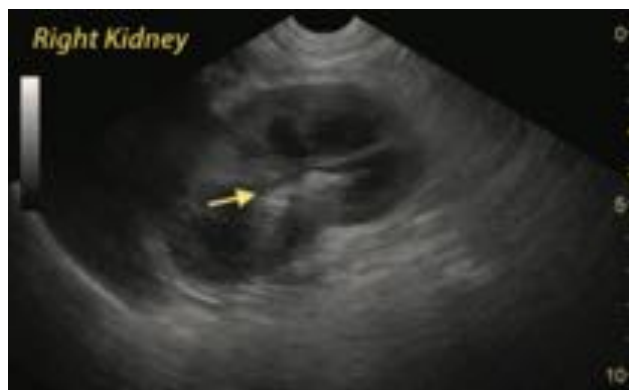Long axis of the left pancreatic limb (between calipers) in a cat with pancreatitis after undergoing a renal transplant. Note the decrease in echogenicity and mild loss of regular echotexture of the swollen and irregularly contoured pancreas. Also note the mild dilation of the pancreatic duct (arrow). Focal peritonitis is evident by increased echogenicity and loss of the linear echotexture of the surrounding mesentery.

IMAGING PERFORMED BY

Jenn

HOSPITAL NAME

Rockaway AH



Long axis of the right kidney in a dog with pyelonephritis. Note the increased echogenicity and irregular outline of the renal crest and diverticuli and the mild dilation of the renal pelvis (arrow).

REFERRING VET

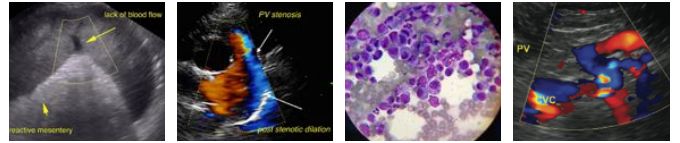
Dr. Ascot

INVOICE

32264

DATE

8/9/22



PATIENT

Tia Lucy Strelec

SPECIES

Canine

BREED

Bichon Mix

SEX

Spayed female

AGE

9 months

WEIGHT

12 lbs

INTERPRETED BY

Eric Lindquist, DMV
DABVP, Cert. IVUSS

IMAGING PERFORMED BY

Jenn

HOSPITAL NAME

Rockaway AH

REFERRING VET

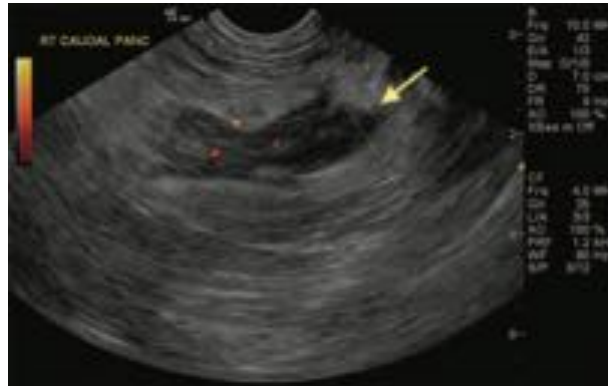
Dr. Ascot

INVOICE

32264

DATE

8/9/22



Long axis of the right pancreatic limb in a dog with acute pancreatitis. The swollen hypoechoic pancreas is embedded in hyperechoic mesenteric fat (arrow). Note the regional differences in blood flow intensity within the parenchyma as demonstrated by Power Doppler interrogation compatible with multifocal disruption of vascularization as a sequela of the severe inflammation.

References:

Bennet D. Diagnosis of pyrexia of unknown origin. *In Practice* 1995;17(10):470-81.

Dunn KJ, Dunn JK. Diagnostic investigations in 101 dogs with pyrexia of unknown origin. *J Sm Anim Pract* 1998;39(12):574-80.

Flood J. The diagnostic approach to fever of unknown origin in cats. *Compend Contin Educ Vet* 2009;31(1):26-31.

Flood J. The diagnostic approach to fever of unknown origin in dogs. *Compend Contin Educ Vet* 2009;31(1):14-21.

Lappin MR. The role of blood borne pathogens in feline fever of unknown origin. Proceedings from the American College of Veterinary Internal Medicine, Denver, CO, June 15-18, 2011.

Lunn KF. Fever of unknown origin: a systematic approach to diagnosis. *Compend Contin Educ Vet* 2001;23(11):976-92.

Lunn KF. Fever of unknown origin: appropriate choice of diagnostic tests. Proceedings from the American College of Veterinary Internal Medicine, Minneapolis, MN, June 9-12, 2004.