



PATIENT

Knox Weeks

SPECIES

Canine

BREED

English Setter

SEX

Male

AGE

1 year 5 months

WEIGHT

48.2 lbs

INTERPRETED BY

Eric Lindquist, DMV
DABVP, Cert. IVUSS

IMAGING PERFORMED BY

Jessica Miller, RDMS

HOSPITAL NAME

Long Valley AH

REFERRING VET

Dr. Earl

INVOICE

91099

DATE

8/10/21

PRESENTING CLINICAL SIGNS

History: Chronic intermittent diarrhea, weight loss, Dysbiosis
Abnormal PE/Chem/CBC/UA Results: CBC: WNL Chem: SDMA 15 Multiple fecals and comprehensive diarrhea profile: negative GI panel with spec PL: folate 22.5, Dysbiosis Index 8.9, ACTH Stim normal

ULTRASONOGRAPHIC EXAMINATION OF THE ABDOMEN

Urinary System

The **urinary bladder**, trigone, and pelvic urethra presented normal thicknesses and normal tone. The ureters were not visible which is normal. No uroliths or sediment were visualized and anechoic urine was present. No evidence of inflammatory or neoplastic changes was noted. Ureteral papillae were normal.

The prostate was uniform and measured 1.5 cm. The iliac trifurcation was unremarkable.

The testicles were imaged and found to be uniform with no evidence of pathology.

The **kidneys** revealed normal size and structure, corticomodullary definition and ratio for this age. The cortices presented largely uniform texture with normal echogenic relationship to liver and spleen. Medullary structure differed distinctly from the cortex and no evidence of pelvic dilation was present. The capsules were acceptably uniform without significant irregularities. The left kidney measured 6.08 cm. The right kidney measured 5.73 cm.

Adrenal Glands

Both **adrenal glands** were visualized and recognized as having normal shape, size, position and echogenicity for this breed. The phrenic vasculature, glandular echogenicity and detail were unremarkable. Capsule, cortex, and medullary definition were normal for this age patient. The left adrenal gland measured 1.53 x 0.54 cm at the caudal pole and 0.49 cm at the cranial pole. The right adrenal gland measured 0.8 cm at the cranial pole and 0.5 cm at the caudal pole.

Spleen

The **spleen** presented a smooth homogeneous parenchyma hyperechoic to liver and renal cortical parenchyma. The capsule was smooth without noticeable expansion or deviation from within the spleen or adjacent pathology. The splenic vasculature demonstrated normal volume without signs of congestion or thrombosis. No sonographic evidence of acute or chronic inflammatory, neoplastic, or infarctual changes was noted.

Liver

The **liver** images submitted revealed subjectively normal liver size, contour, and structure. Parenchymal echogenicity was naturally coarse and hypoechoic to the spleen. Vascular and biliary tracts were of normal volume with no evidence of congestion. The gallbladder presented acceptably thin walls with primarily anechoic content. The cystic and common bile ducts were normal. No pathological hepatic lymphadenopathy was evident. No overt structural evidence of inflammatory, infiltrative or regenerative pathology was evident.



PATIENT

Knox Weeks

Gastrointestinal

SPECIES

Canine

Examination of the **gastrointestinal tract** revealed a stomach and intestine free of stasis, of normal wall thickness, acceptable curvilinear mural detail, and peristaltic activity. Small and large intestine demonstrated normal luminal chyme and stool consistency respectively. No obstructive or overt infiltrative disease was noted. No associated abnormal lymphatic activity was noted.

BREED

English Setter

Pancreas

SEX

Male

The base and limbs of the **pancreas** were observed to be largely isoechoic to surrounding omental fat. Pancreatic duct and capsular contour were acceptably normal and parenchyma respected normal curvilinear patterns. No overt evidence of active inflammatory or neoplastic disease was noted.

AGE

1 year 5 months

ULTRASONOGRAPHIC FINDINGS

Unremarkable abdomen.

WEIGHT

48.2 lbs

INTERPRETATION OF THE FINDINGS & FURTHER RECOMMENDATIONS

Hydrolyzed diet trial may be in the patient's best interest +/- B complex +/- pancreatic supplementation trial despite negative GI panel.

INTERPRETED BY

Eric Lindquist, DMV
DABVP, Cert. IVUSS

For an additional charge an internal medicine consult can be utilized through [Sonopath.com](http://sonopath.com). You can select the internal medicine drop down at <http://spa.sonopath.com/>.

One of the world's top internists & SonoPath associate Dr. Remo Lobetti BVSc, MMedVet, PhD, DECVIM can evaluate your case through SonoPath. <https://sonopath.com/resources/sonopath-services/internal-medicine-teleconsultation-services>

IMAGING PERFORMED BY

Jessica Miller, RDMS

HOSPITAL NAME

Long Valley AH

REFERRING VET

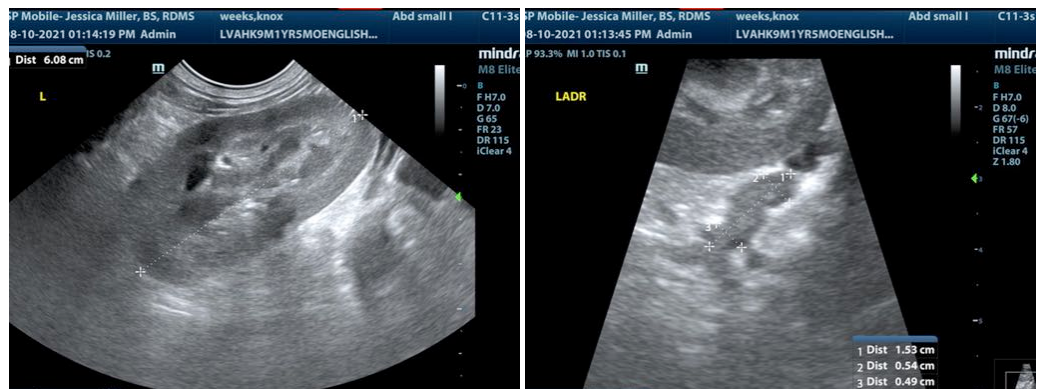
Dr. Earl

INVOICE

91099

DATE

8/10/21





PATIENT

Knox Weeks

SPECIES

Canine

BREED

English Setter

SEX

Male

AGE

1 year 5 months

WEIGHT

48.2 lbs

INTERPRETED BY

Eric Lindquist, DMV
DABVP, Cert. IVUSS

IMAGING PERFORMED BY

Jessica Miller, RDMS

HOSPITAL NAME

Long Valley AH

REFERRING VET

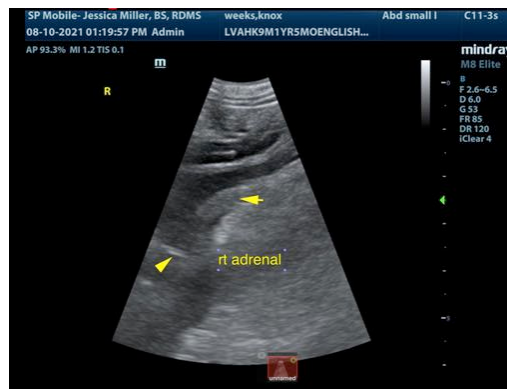
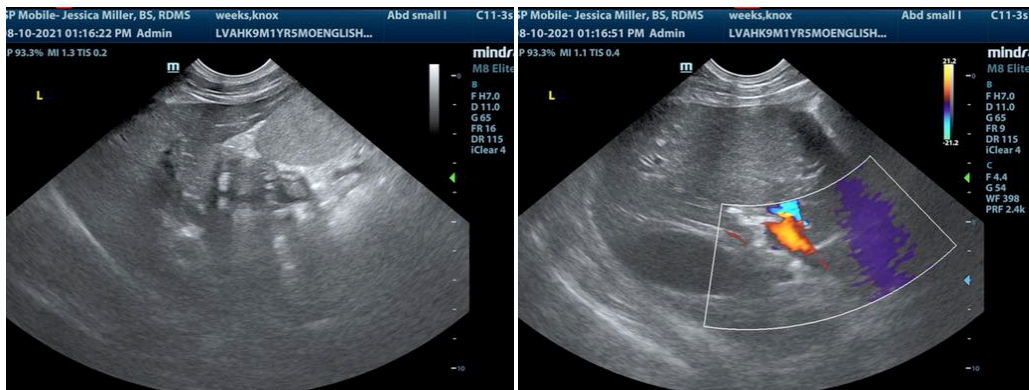
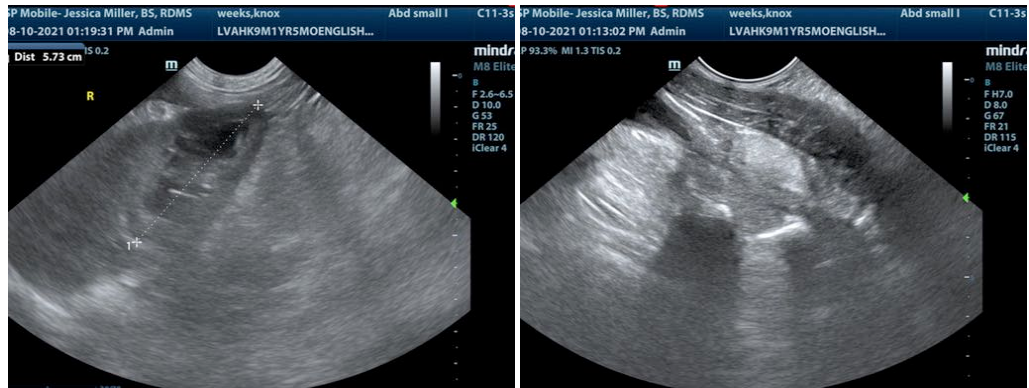
Dr. Earl

INVOICE

91099

DATE

8/10/21



The information and recommendations provided are based on the images presented by the referring veterinarian. No evaluation can be communicated regarding pathology that was not visible in the image/video clips provided.

Thank you for this referral. If the clinical or image interpretation does not parallel your findings or if I can be of any further assistance please contact me.

Eric Lindquist, DMV, DABVP, Cert. IVUSS, CEO of SonoPath.com
info@SonoPath.com