



PATIENT

Chewie Coppola

SPECIES

Canine

BREED

Airdale Terrier

SEX

Neutered Male

AGE

7 Yrs 2 Mos

WEIGHT

67 lbs

INTERPRETED BY

Eric Lindquist, DMV
DABVP, Cert IVUSS

**IMAGING
PERFORMED BY**

Denise Bruno, LVT,
RDMS

HOSPITAL NAME

Kenilworth AH

REFERRING VET

Dr. Mansour

INVOICE

91117

DATE

08/10/21

PRESENTING CLINICAL SIGNS

History: Removed Sarcoma mass – grew back

Previous ultrasounds attached.

ULTRASONOGRAPHIC EXAMINATION OF THE ABDOMEN

Urinary System

The **urinary bladder**, trigone, and pelvic urethra presented normal thicknesses and normal tone. The ureters were not visible which is normal. No uroliths or sediment were visualized and anechoic urine was present. No evidence of inflammatory or neoplastic changes was noted. Ureteral papillae were normal.

The prostate measured 1.0 cm.

The **kidneys** revealed normal size and structure, corticomedullary definition and ratio for this age. The cortices presented largely uniform texture with normal echogenic relationship to liver and spleen. Medullary structure differed distinctly from the cortex and no evidence of pelvic dilation was present. The capsules were acceptably uniform without significant irregularities. The right kidney measured 6.0 cm. The left kidney measured 6.92 cm.

Adrenal Glands

Both **adrenal glands** were visualized and recognized as having normal shape, size, position and echogenicity for this breed. The phrenic vasculature, glandular echogenicity and detail were unremarkable. Capsule, cortex, and medullary definition were normal for this age patient. The right adrenal gland measured 0.69 cm. The left adrenal gland measured 3.3 x 0.74 cm at the caudal pole and 0.42 cm at the cranial pole.

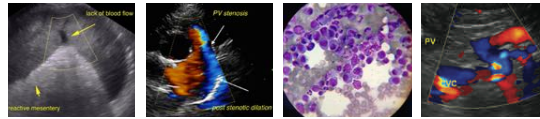
Spleen

The **spleen** presented a smooth homogeneous parenchyma hyperechoic to liver and renal cortical parenchyma. The capsule was smooth without noticeable expansion or deviation from within the spleen or adjacent pathology. The splenic vasculature demonstrated normal volume without signs of congestion or thrombosis. No sonographic evidence of acute or chronic inflammatory, neoplastic, or infarctual changes was noted.

Liver

The **liver** images submitted revealed subjectively normal liver size, contour, and structure. Parenchymal echogenicity was naturally coarse and hypoechoic to the spleen. Vascular and biliary tracts were of normal volume with no evidence of congestion. The gallbladder presented acceptably thin walls with primarily anechoic content. The cystic and common bile ducts were normal. No pathological hepatic lymphadenopathy was evident. No overt structural evidence of inflammatory, infiltrative or regenerative pathology was evident.

Gastrointestinal



PATIENT

Chewie Coppola

Examination of the **gastrointestinal tract** revealed a stomach and intestine free of stasis, of normal wall thickness, acceptable curvilinear mural detail, and peristaltic activity. Small and large intestine demonstrated normal luminal chyme and stool consistency respectively. No obstructive or overt infiltrative disease was noted. No associated abnormal lymphatic activity was noted.

SPECIES

Canine

Pancreas

The base and limbs of the **pancreas** were observed to be largely isoechoic to surrounding omental fat. Pancreatic duct and capsular contour were acceptably normal and parenchyma respected normal curvilinear patterns. No overt evidence of active inflammatory or neoplastic disease was noted.

BREED

Airdale Terrier

SEX

Neutered Male

Stifle

The mass along the stifle in this patient appears to be muscle based with an infiltrative connection with multi-focal, hypoechoic nodular changes entering into the fascia and subcutaneous space. Regional inflammation/cellulitis was noted. The mass does not appear cleanly resectable. The primary mass measures 6.7 x 4.47 cm. Given the infiltrative peripheral pattern to the mass I recommend amputation or chemotherapy and radiation depending upon cytology results.

AGE

7 Yrs 2 Mos

WEIGHT

67 lbs

ULTRASONOGRAPHIC FINDINGS

Unremarkable abdomen.

INTERPRETED BY

Eric Lindquist, DMV
DABVP, Cert IVUSS

Non-resectable, infiltrative mass on the stifle. Not cleanly resectable without amputation. Suspect sarcoma.

IMAGING PERFORMED BY

Denise Bruno, LVT,
RDMS

INTERPRETATION OF THE FINDINGS & FURTHER RECOMMENDATIONS

FNA of the mass on the stifle is indicated. There was no evidence of metastatic disease.

HOSPITAL NAME

Kenilworth AH

REFERRING VET

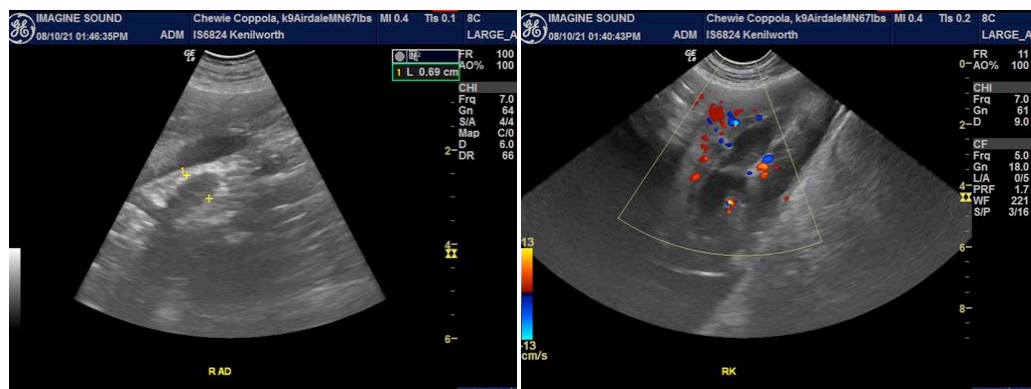
Dr. Mansour

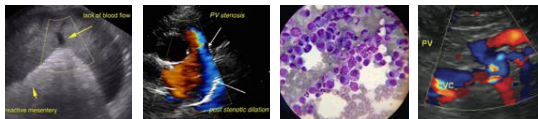
INVOICE

91117

DATE

08/10/21





PATIENT

Chewie Coppola

SPECIES

Canine

BREED

Airdale Terrier

SEX

Neutered Male

AGE

7 Yrs 2 Mos

WEIGHT

67 lbs

INTERPRETED BY

Eric Lindquist, DMV
DABVP, Cert IVUSS

IMAGING PERFORMED BY

Denise Bruno, LVT,
RDMS

HOSPITAL NAME

Kenilworth AH

REFERRING VET

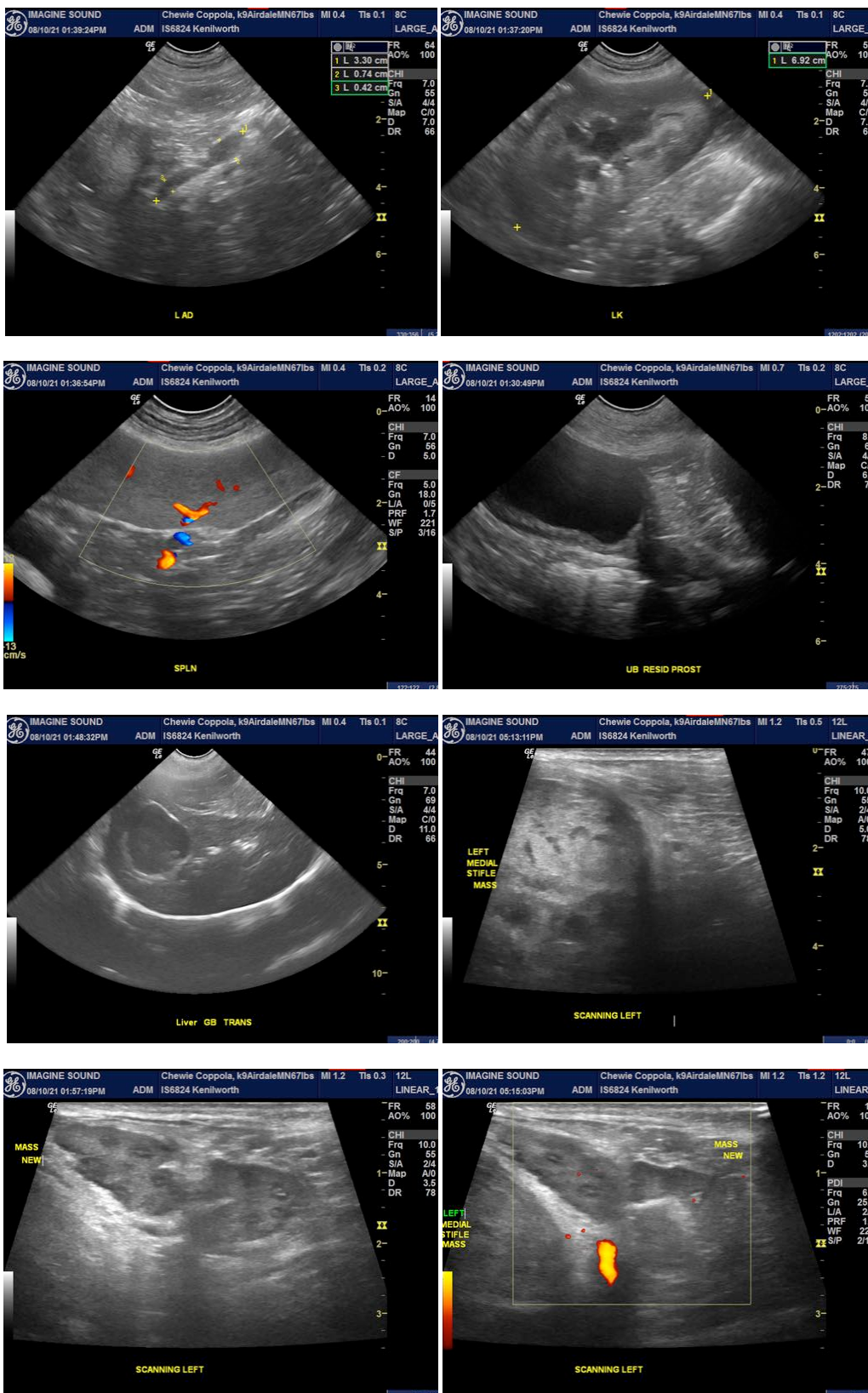
Dr. Mansour

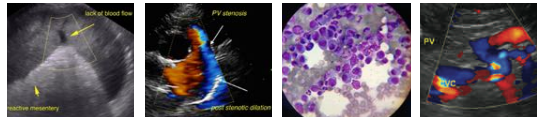
INVOICE

91117

DATE

08/10/21





PATIENT

Chewie Coppola

SPECIES

Canine

BREED

Airdale Terrier

SEX

Neutered Male

AGE

7 Yrs 2 Mos

WEIGHT

67 lbs

INTERPRETED BY

Eric Lindquist, DMV
DABVP, Cert IVUSS

IMAGING PERFORMED BY

Denise Bruno, LVT,
RDMS

HOSPITAL NAME

Kenilworth AH

REFERRING VET

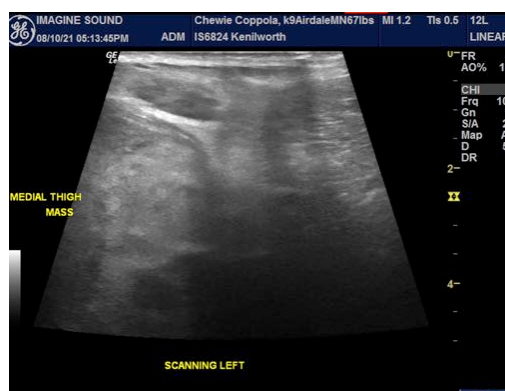
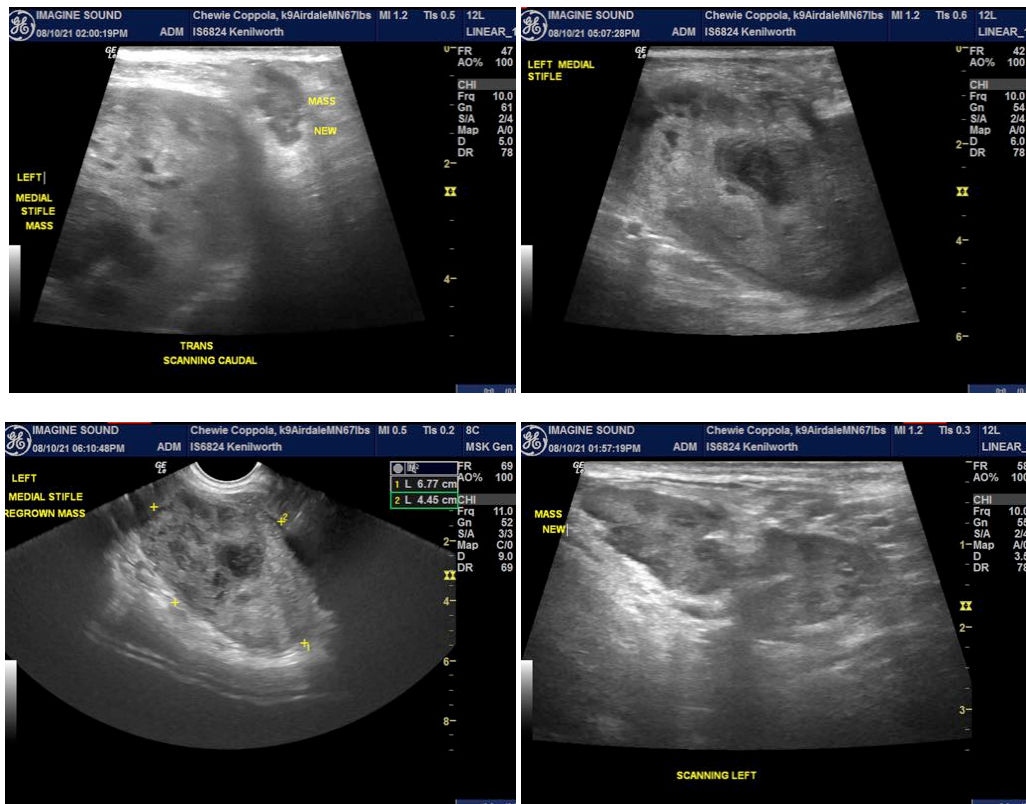
Dr. Mansour

INVOICE

91117

DATE

08/10/21



The information and recommendations provided are based on the images presented by the referring veterinarian. No evaluation can be communicated regarding pathology that was not visible in the image/video clips provided.

Thank you for this referral. If the clinical or image interpretation does not parallel your findings or if I can be of any further assistance please contact me.

Eric Lindquist, DMV, DABVP, Cert. IVUSS, CEO of SonoPath.com
Eric.Lindquist@SonoPath.com