



**PATIENT PRESENTING CLINICAL SIGNS**

Willow Scerbo

Elevated free T4. R/O thyroid vs other. No current meds  
Abnormal PE/Chem/CBC/UA Results: Free T4 >6.0 mg/dl., Neu 11.96; MPV 14.3

**SPECIES**

Canine

**BREED**

Chihuahua

**SEX**

Female

**AGE**

10 Years

**WEIGHT**

5.4 Pounds

**ULTRASONOGRAPHIC EXAMINATION OF THE THYROID**

Both thyroid lobes were fully visualized with uniform parenchyma, measuring 0.50 cm in width. Regional retromandibular lymph nodes were mildly enlarged and heterogeneous on both the left and right lobes. The salivary glands, esophagus and trachea were all normal.

**ULTRASONOGRAPHIC FINDINGS**

- Retromandibular lymphadenopathy
- Normal thyroid

**INTERPRETATION OF THE FINDINGS & FURTHER RECOMMENDATIONS**

The cause of hyperthyroidism is unclear in this patient. Ectopic thyroid tissue possible. Chest radiographs or cervical CT would be recommended to assess for potential ectopic thyroid tissue. Full thyroid profile recommended. FNA of the retromandibular lymph nodes could be considered with cytology and culture, likely reactive.

**INTERPRETED BY**

Eric Lindquist, DMV  
DABVP, Cert. IVUSS

**IMAGING PERFORMED BY**

Shari Reffi, CVT

**HOSPITAL NAME**

Smithfield Animal Hospital

**REFERRING VET**

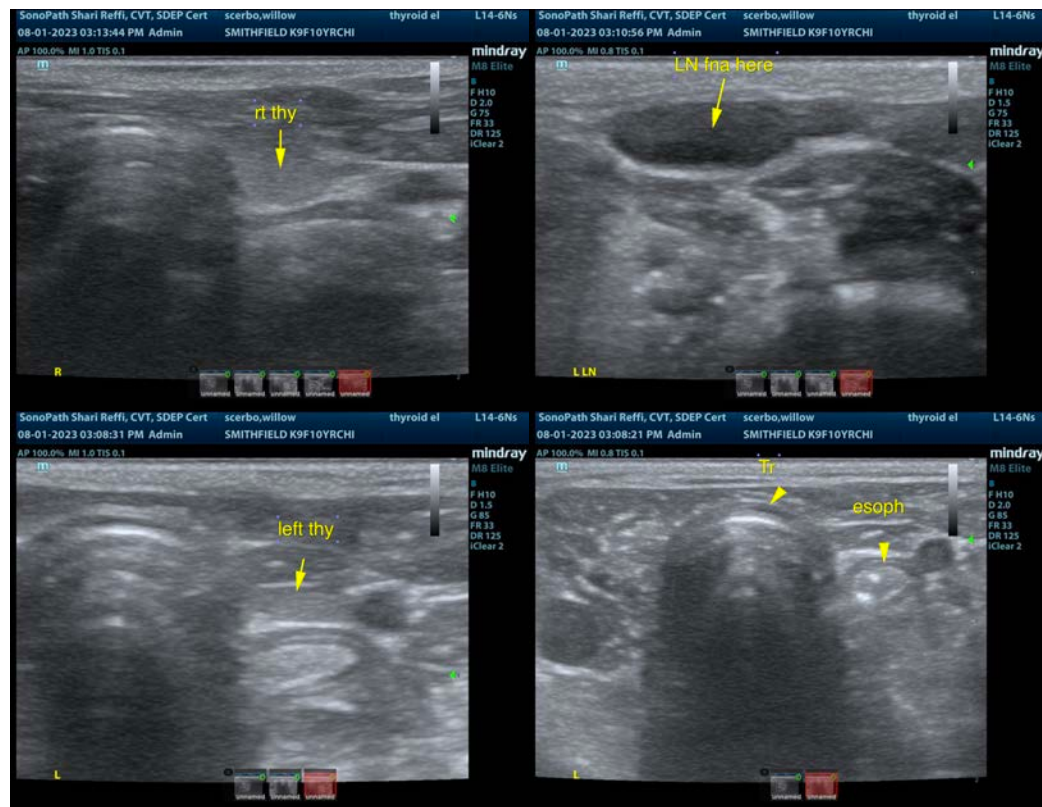
Dr. Boe

**INVOICE**

44561

**DATE**

8/1/23





**PATIENT**

Willow Scerbo

**SPECIES**

Canine

**BREED**

Chihuahua

**SEX**

Female

**AGE**

10 Years

**WEIGHT**

5.4 Pounds

**INTERPRETED BY**

Eric Lindquist, DMV

DABVP, Cert. IVUSS

**IMAGING PERFORMED BY**

Shari Reffi, CVT

**HOSPITAL NAME**

Smithfield Animal Hospital

**REFERRING VET**

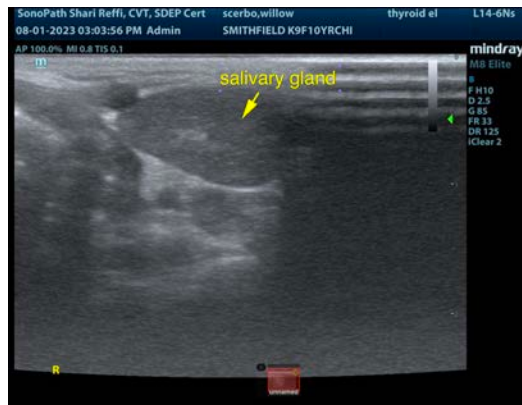Dr. Boe

**INVOICE**

44561

**DATE**

8/1/23



The information and recommendations provided are based on the images presented by the referring veterinarian/sonographer. No evaluation can be communicated regarding pathology that was not visible in the image/video clips provided.

Thank you for this referral. If the clinical or image interpretation does not parallel your findings or if I can be of any further assistance please contact me.

Eric Lindquist, DMV, DABVP, Cert. IVUSS, CEO of SonoPath.com

[info@SonoPath.com](mailto:info@SonoPath.com)