


PATIENT

Wally Turner

PRESENTING CLINICAL SIGNS

History: Presented due to anorexia and lethargy 24-48 hours duration. Pleural effusion noted on thoracic radiographs. Ultrasound guided FNA yielded blood.
 Mild fever (103.3°F), CBC: mild neutrophilia, NSF otherwise, chemistry WNL

SPECIES

Canine

ULTRASONOGRAPHIC EXAMINATION OF THE HEART
BREED

Great Dane

The heart revealed normal contractility and volume. No primary cardiac disease was present. The right heart was slightly enlarged with minor, tricuspid insufficiency> This is likely secondary to increased thoracic pressures. A 6.9 cm mixed, hypoechoic, undifferentiated mass was noted in the chest surrounded by pleural effusion. Areas of lung consolidations were noted.

SEX

Neutered male

CANINE	MR	TR	LA/AO	LA/AO	FS	EF	EPSS
CARDIAC PARAMETERS	VMAX (m/s)	VMAX (m/s)	(Boon method)	(Heart Base;)	(%)	(%)	(cm)
NORMAL PARAMETER	4.5-5.5	<2.7	1.3	Up to 1.6	28-40	40-100	<0.6
PATIENT			NM	0.9			NM
CANINE	HR	AV	PV	BODY WEIGHT	LA	LVIDd	LVIDs
CARDIAC PARAMETERS	(BPM)	VMAX (m/s)	MAX (m/s)		2D short axis Base view (cm)	Avg; 2D and m-mode short axis (cm)	Avg; 2D and m-mode short axis (cm)
NORMAL PARAMETER	50-100	0.7-1.7	0.7-1.6	BELOW	BELOW	BELOW	BELOW
PATIENT				135.5 lbs			

AGE

7 ½ years

WEIGHT

135.5 lbs

INTERPRETED BY

 Eric Lindquist, DMV
 DABVP, Cert. IVUSS

IMAGING PERFORMED BY

Dr. Green

ULTRASONOGRAPHIC FINDINGS

Non-cardiogenic pleural effusion with undefined, thoracic mass, suspect lymph node origin, possible lung, yet no peripheral air was noted around the lesion.

HOSPITAL NAME

 Healing Spirit Animal
 Wellness

REFERRING VET

Dr. Green

INTERPRETATION OF THE FINDINGS & FURTHER RECOMMENDATIONS

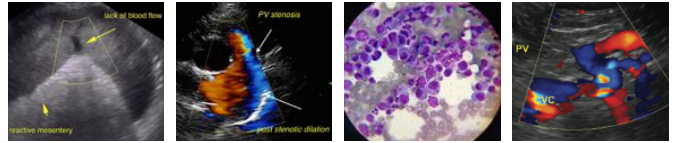
Ultrasound-guided FNA of the accessible mass is indicated. I recommend chest CT, pleurocentesis and cytospin can also be considered from a diagnostic standpoint. An abdominal sonogram is warranted to assess for primary disease that may be playing a role with metastatic changes in the chest.

INVOICE

76336

DATE

8/1/23



PATIENT

Wally Turner

SPECIES

Canine

BREED

Great Dane

SEX

Neutered male

AGE

7 ½ years

WEIGHT

135.5 lbs

INTERPRETED BY

Eric Lindquist, DMV
DABVP, Cert. IVUSS

IMAGING PERFORMED BY

Dr. Green

HOSPITAL NAME

Healing Spirit Animal
Wellness

REFERRING VET

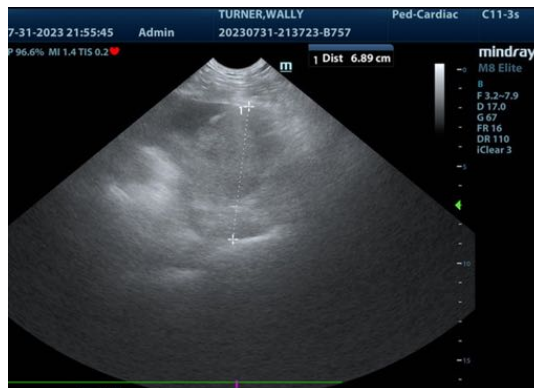
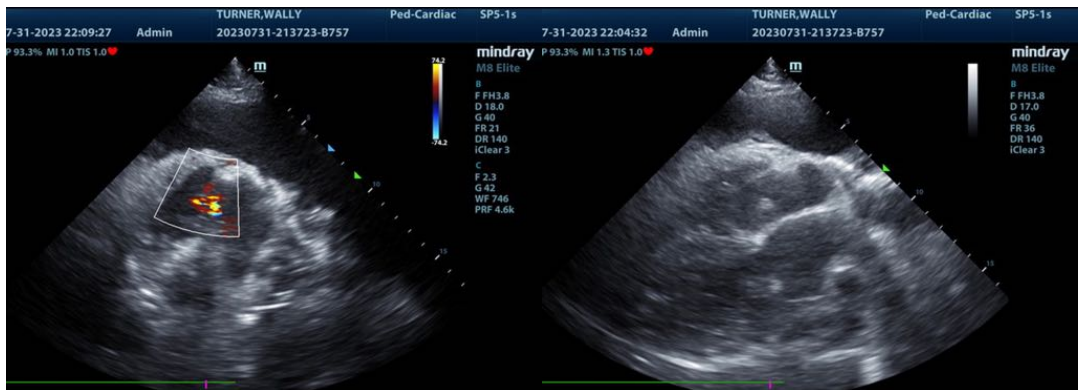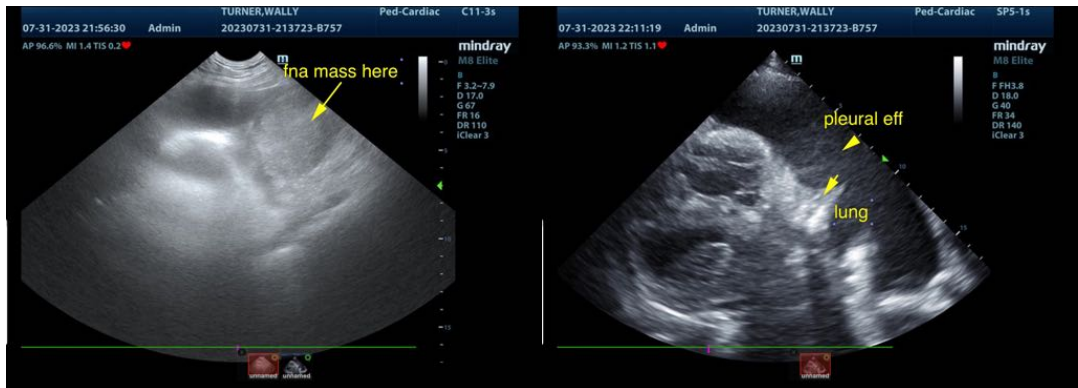
Dr. Green

INVOICE

76336

DATE

8/1/23



The information and recommendations provided are based on the images presented by the referring veterinarian/sonographer. No evaluation can be communicated regarding pathology that was not visible in the image/video clips provided.

Thank you for this referral. If the clinical or image interpretation does not parallel your findings or if I can be of any further assistance please contact me.

Eric Lindquist, DMV, DABVP, Cert. IVUSS, CEO of SonoPath.com
info@SonoPath.com