



PATIENT PRESENTING CLINICAL SIGNS

Scuffles Orr

History: Grade 3/6 L systolic murmur and HW +

SPECIES ULTRASONOGRAPHIC EXAMINATION OF THE HEART

Canine

BREED

Terrier mix

SEX

Neutered male

AGE

3 years

The echocardiogram in this patient demonstrated normal **left atrial** size based on 3 separate methods of LA evaluation. Minor **mitral** valve insufficiency was noted. Prolapse of the anterior mitral valve leaflet was noted. The **left ventricle** presented thicknesses with linear contour and was not dilated nor restricted. The **myocardium** presented normal echogenicity without subjective evidence of significant fibrotic or ischemic disease. **Contractility** of the ventricular walls was adequate and in normal range for this patient evidenced by the fractional shortening measurement and subjective evaluation of the different regions of the myocardium. The **left ventricular outflow** tract demonstrated normal laminar flow and subjective structural integrity. The **right atrium** and auricle revealed normal size, structure and content. No evidence of masses was noted. **Tricuspid** insufficiency was noted. The **right ventricle** was of normal size (1/3 diameter of LV), chordae structure, myocardial echogenicity and thickness. **Pulmonary outflow** tract assessment revealed normal valve structure, laminar flow, and diameter (approx. 1:1 pa/ao ratio). No visible **pericardial** or free pleura fluid was noted. The cranial **mediastinum and pericardial and extra-cardiac regions** were free of masses in the visible window. Arrhythmogenic activity was noted.

WEIGHT

11.7 lbs

INTERPRETED BY

Eric Lindquist, DMV
DABVP, Cert. IVUSS

IMAGING PERFORMED BY

Jenn

HOSPITAL NAME

Rockaway AH

CANINE CARDIAC PARAMETERS	MR VMAX (m/s)	TR VMAX (m/s)	LA/AO (Boon method)	LA/AO (Heart Base;)	FS (%)	EF (%)	EPSS (cm)
NORMAL PARAMETER	4.5-5.5	<2.7	1.3	Up to 1.6	28-40	40-100	<0.6
PATIENT	-	-	1.1	1.4	45	90	0.1
CANINE CARDIAC PARAMETERS	HR (BPM)	AV VMAX (m/s)	PV MAX (m/s)	BODY WEIGHT	LA (2D short axis Base view) (cm)	LVIDd (Avg; 2D and m-mode short axis) (cm)	LVIDs (Avg; 2D and m-mode short axis) (cm)
NORMAL PARAMETER	50-100	0.7-1.7	0.7-1.6	BELOW	BELOW	BELOW	BELOW
PATIENT		1.26	0.61	11.7 lbs	2.65 max	2.8	

REFERRING VET

Dr. Harrs

ULTRASONOGRAPHIC FINDINGS

Mitral and tricuspid insufficiency. Stage B1 valvular disease.
Arrhythmia.

INVOICE

76337

INTERPRETATION OF THE FINDINGS & FURTHER RECOMMENDATIONS

DATE

8/1/23

There was no significant volume overload. Blood pressure measurements and EKG are indicated. No visible heartworm was noted.



PATIENT

Scruffles Orr

SPECIES

Canine

BREED

Terrier mix

SEX

Neutered male

AGE

3 years

WEIGHT

11.7 lbs

INTERPRETED BY

Eric Lindquist, DMV
DABVP, Cert. IVUS

IMAGING PERFORMED BY

Jenn

HOSPITAL NAME

Rockaway AH

REFERRING VET

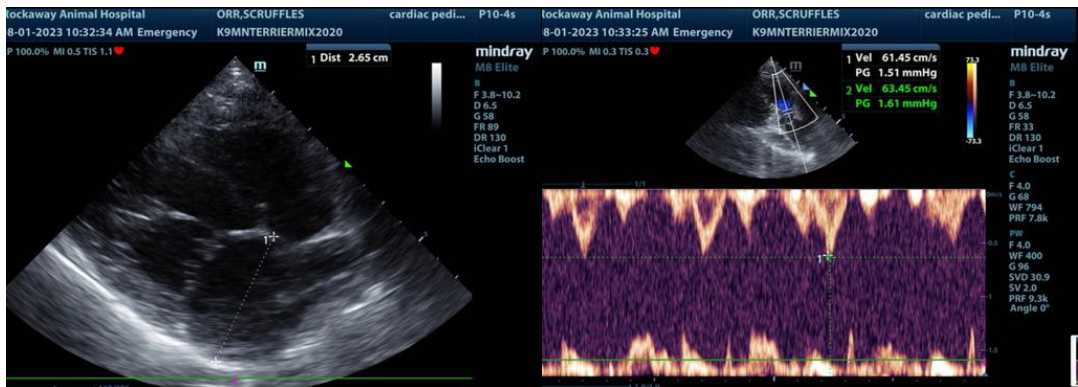
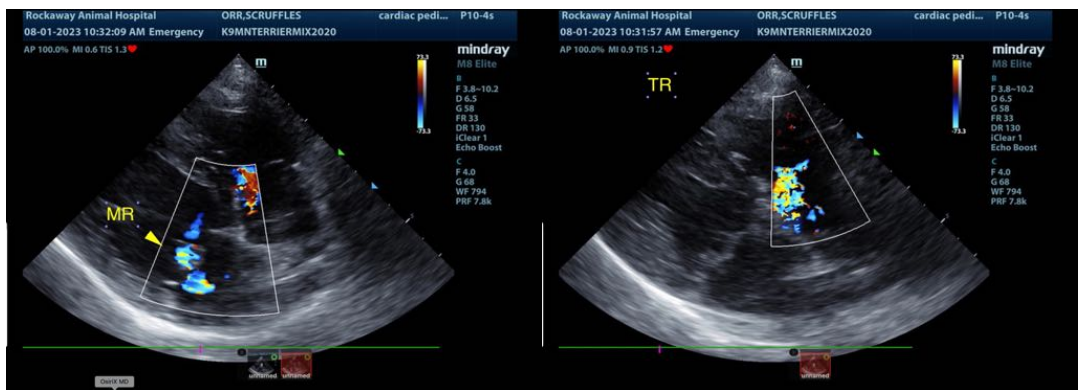
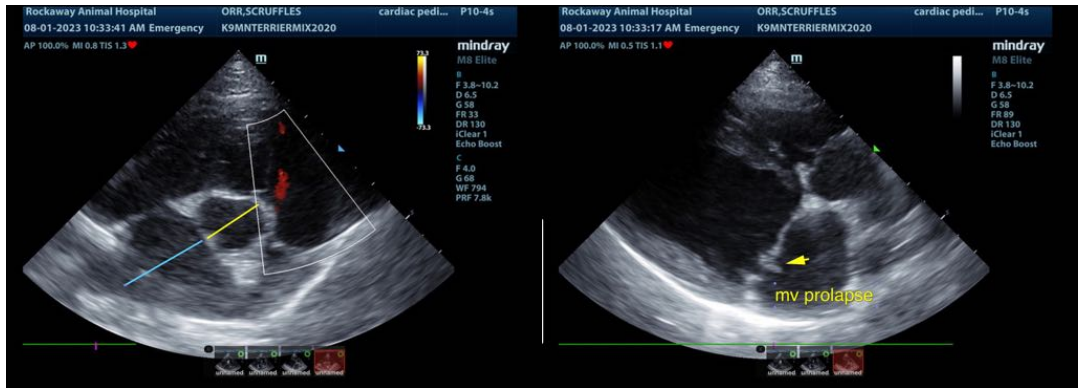
Dr. Harrs

INVOICE

76337

DATE

8/1/23





PATIENT

Scruffles Orr

SPECIES

Canine

BREED

Terrier mix

SEX

Neutered male

AGE

3 years

WEIGHT

11.7 lbs

INTERPRETED BY

Eric Lindquist, DMV
DABVP, Cert. IVUSS

IMAGING PERFORMED BY

Jenn

HOSPITAL NAME

Rockaway AH

REFERRING VET

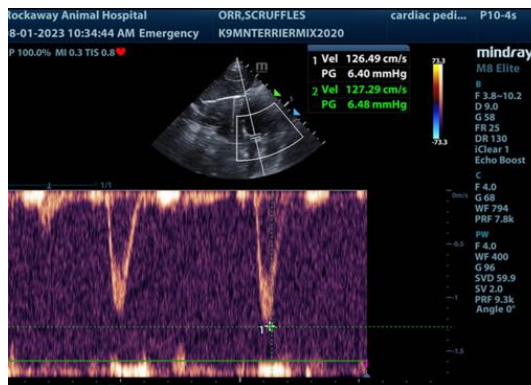
Dr. Harrs

INVOICE

76337

DATE

8/1/23



The information and recommendations provided are based on the images presented by the referring veterinarian/sonographer. No evaluation can be communicated regarding pathology that was not visible in the image/video clips provided.

Thank you for this referral. If the clinical or image interpretation does not parallel your findings or if I can be of any further assistance please contact me.

Eric Lindquist, DMV, DABVP, Cert. IVUSS, CEO of SonoPath.com
info@SonoPath.com