

**DATE PRESENTING CLINICAL SIGNS**

8/1/23

Ivy vomited on Tuesday (x2 containing yellow bile and hairballs). Normal defecation on Tuesday outside of the litterbox (in owner's bed). Since then, small amounts of brown liquid feces, less than normal amount. Eating well and drinking well. Urinating normally in the litterbox. No lethargy. Owner has been giving Miralax and pumpkin. History of eating string. PE: BAR, no firm feces in colon, soft small urinary bladder, no pain on abdominal palpation, mildly dehydrated.

**PATIENT**

Ivy Endrich

**SPECIES**

Feline

Current Medications: Miralax 1/8tsp PO q12-24hrs, Pumpkin 1tsp PO q12-24hrs.

Lab Results: Pending.

Radiographs: possibly two populations of small intestines, diarrhea in colon, empty stomach, possible intestinal plication.

**BREED**

DSH

Date of Previous IntraPet Ultrasound: No previous.

Sedation: Not required to complete full diagnostic ultrasound.

Stat Report: Not requested.

Imaging Performed By: Andi Parkinson, BS, RDMS.

**SEX**

Spayed Female

**ULTRASONOGRAPHIC EXAMINATION OF THE ABDOMEN****Urinary System**

Urinary bladder is adequately distended. It has a normal uniform wall thickness. Contents include primarily anechoic fluid with a moderate to large amount of echogenic non-shadowing debris, which could be partially consistent with incidental suspended lipid in a cat, likely combined with exfoliated cells, mucous and/or small blood clots. Both sterile inflammation as well as urinary tract infection can also present with echogenic debris. No masses or cystoliths are observed. The trigone and visible pelvic urethra are normal in thickness with a smooth mucosal surface.

**AGE**

10/30/15

The right kidney is normal in size (4.06 cm), shape and echogenicity. It has smooth peripheral margination. There is a normal 1:3 cortex to medulla ratio with appropriate corticomedullary distinction. There is no evidence of pyelectasia, mineral or infarcts observed.

**WEIGHT**

12 Pounds

The left kidney is normal in size (4.01 cm), shape and echogenicity. It has smooth peripheral margination. There is a normal 1:3 cortex to medulla ratio with appropriate corticomedullary distinction. There is no evidence of pyelectasia, mineral or infarcts observed.

**INTERPRETED BY**Beth Johnson, DVM  
DACVIM**Adrenal Glands**

The adrenal glands were unable to be well visualized in these images.

**HOSPITAL NAME**

Essex Middle River VC

**Spleen**

The spleen is subjectively normal in size with a normal smooth capsular contour. Parenchyma is appropriately finely textured and homogenous with normal echogenicity relative to surrounding tissue (hyperechoic to liver). No focal nodules or masses are observed. Splenic vasculature appears normal.

**REFERRING VET**

Dr. Stoll

**INVOICE**

44542

**Liver**

The liver is subjectively normal in size with normal smooth curvilinear peripheral contour. Parenchyma is appropriately hypoechoic to the spleen in echogenicity and appropriately mildly coarse and homogenous in echotexture. No focal lesions are observed. Visible vasculature and biliary tree appear normal without distension or congestion.

Gallbladder is moderately distended with anechoic bile as well as suspended and gravity dependent echogenic debris. The wall is smooth without visible thickening. There is no evidence of cystic or CBD dilation. There is no evidence of effusion or inflammation.

### ***Gastrointestinal***

The stomach wall is normal in thickness (canine < 0.5 cm and feline < 0.4 cm) and layering. The lumen of the stomach is empty with no evidence of obstruction, foreign material or infiltrative disease. Pyloric outflow tract appears patent.

The visible small intestines are normal in wall thickness and layering (canine duodenum < 0.5 cm and feline duodenum < 0.4 cm; other < 0.3 cm). Small intestinal motility appears adequate (1-3 contractions per min). The lumen of the small intestine is empty with no evidence of obstruction, foreign material or infiltrative disease.

The visible colon is normal in wall thickness (< 0.2 cm) and layering. Contents are consistent with normal formed feces and gas.

### ***Pancreas***

The observed pancreas is mildly prominent in size and mildly hypoechoic to surrounding tissue. Normal shape and contour are maintained. No pancreatic duct dilation is noted. Subtly enhanced surrounding hyperechoic mesenteric fat is suspected.

### ***Free Abdomen***

There is no evidence of free peritoneal effusion noted in these images.

There is no apparent lymphadenopathy noted in these images.

## **ULTRASONOGRAPHIC FINDINGS**

- The pancreatic changes are subtle/mild and may be not clinically relevant. However, mild or potentially resolving pancreatitis can't be ruled out.
- Urinary bladder debris
- Mild gallbladder debris - Cholecystic debris is of unknown clinical significance. It can be seen with biliary stasis from fasting or illness, however, it can also be associated with hepatobiliary disease in cats and should be interpreted in combination with clinical signs such as nausea, inappetence, cranial abdominal discomfort and/or laboratory changes such as increased ALP and/or increased Tbili.

## **INTERPRETATION OF THE FINDINGS & FURTHER RECOMMENDATIONS**

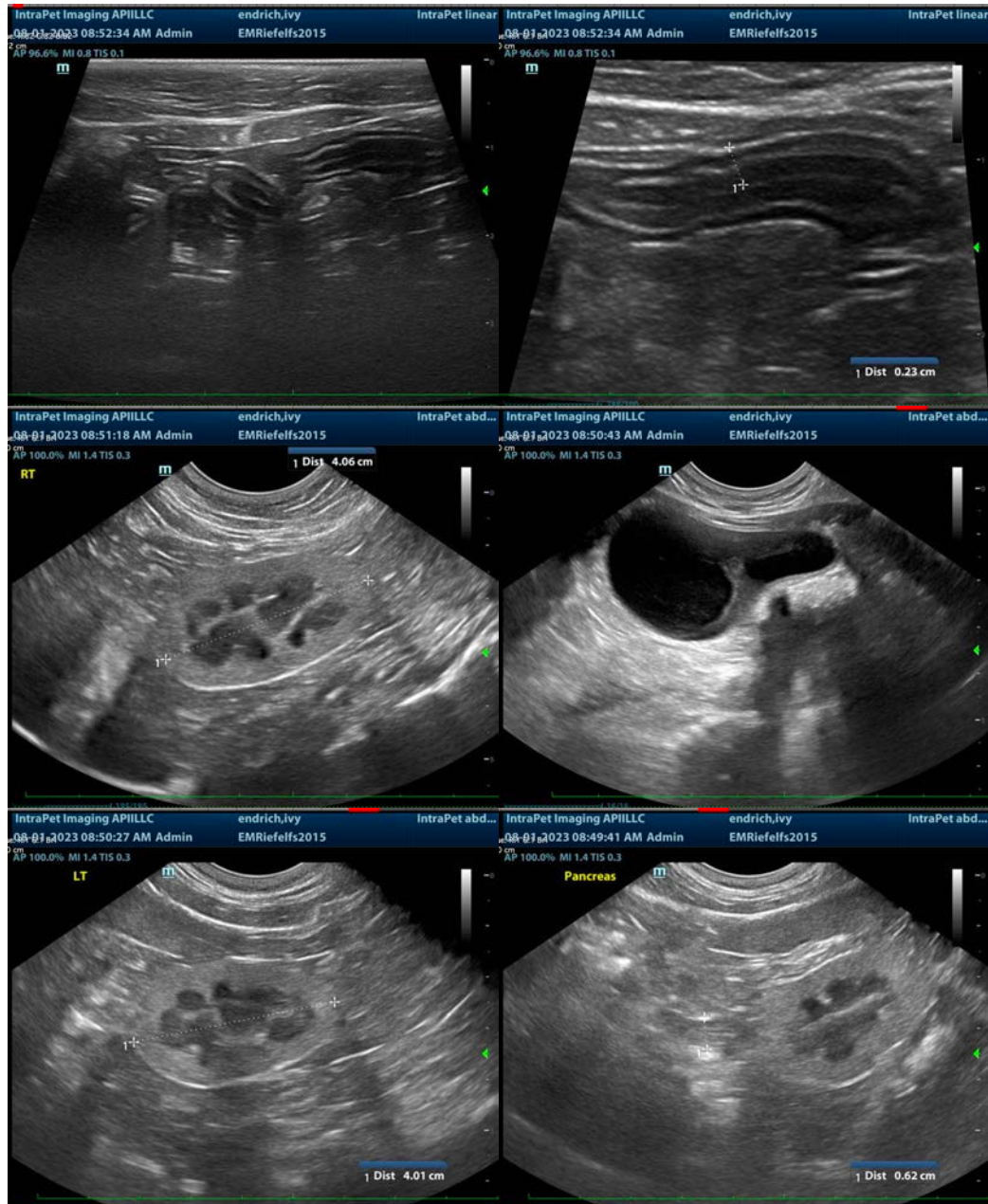
There is no ultrasonographically visible evidence of an obstructive pattern, plication, or foreign material in these images at this time. Given that combined with patient's reported improvement, a previous, potentially resolving gastroenteritis possibly with concurrent resolving pancreatitis is suspected.

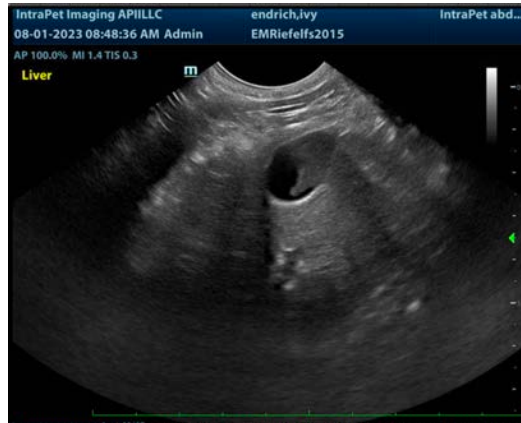If clinical signs return/progress, next diagnostic considerations could include a fecal exam if not recently evaluated.

A gastrointestinal malabsorption panel (including cobalamin, folate, TLI and PLI) to Texas A&M GI Laboratory is recommended for further evaluation of GI and pancreatic function.

A fecal enteropathogen PCR panel to Texas A&M GI Laboratory could be considered for further evaluation of possible infectious disease.

In the meantime, continued supportive/symptomatic medical management, given patient's reported improvement, is recommended.





**The information and recommendations provided are based on the images presented by the referring veterinarian/sonographer. No evaluation can be communicated regarding pathology that was not visible in the image/video clips provided.**

Thank you for this referral. If the clinical or image interpretation does not parallel your findings or if I can be of any further assistance please contact me.

**Beth Johnson, DVM, DACVIM**  
info@sonopath.com