



**PATIENT**

**PRESENTING CLINICAL SIGNS**

Ellie Dean

History: eating a lot, gained 3 pound recently, wondering of cushings disease  
Abnormal PE/Chem/CBC/UA Results: Alk phos 256

**SPECIES**

Canine

**ULTRASONOGRAPHIC EXAMINATION OF THE ABDOMEN**

**Urinary System**

**BREED**

Maltese

The **urinary bladder**, trigone, and pelvic urethra presented normal thicknesses and normal tone. The ureters were not visible which is normal. No uroliths or sediment were visualized and anechoic urine was present. No evidence of inflammatory or neoplastic changes was noted. Ureteral papillae were normal.

**SEX**

Spayed female

The **kidneys** revealed largely normal size and structure, corticomedullary definition and ratio (cortex 1/3 of medulla) were essentially maintained with some age-related loss of curvilinear patterns regarding the capsule and C/M junction. The cortices presented largely uniform texture with some increased echogenicity expected for his age patient. Medullary structure differed distinctly from that of the cortex and no evidence of pelvic dilation was present. The left kidney measured 2.4 cm with pinpoint mineralization that was non-obstructive. The right kidney measured 3.0 cm.

**AGE**

7 years

**WEIGHT**

9.98 lbs

**Adrenal Glands**

Both **adrenal glands** were visualized and recognized as having normal shape, size, position and echogenicity for this breed. The phrenic vasculature, glandular echogenicity and detail were unremarkable. Capsule, cortex, and medullary definition were normal for this age patient. The left adrenal gland measured 0.39 cm at the cranial pole and 0.47 cm at the caudal pole. The right adrenal gland measured 0.35 cm at the cranial pole and 0.28 cm at the caudal pole.

**INTERPRETED BY**

Eric Lindquist, DMV  
DABVP, Cert. IVUSS

**IMAGING PERFORMED BY**

Ashley Whitesell

**Spleen**

The **spleen** presented a smooth homogeneous parenchyma hyperechoic to liver and renal cortical parenchyma. The capsule was smooth without noticeable expansion or deviation from within the spleen or adjacent pathology. The splenic vasculature demonstrated normal volume without signs of congestion or thrombosis. No sonographic evidence of acute or chronic inflammatory, neoplastic, or infarctual changes was noted.

**HOSPITAL NAME**

Dickson AC

**Liver**

**REFERRING VET**

Dr. Hovis

The **liver** images submitted revealed subjectively normal liver size, contour, and structure. Parenchymal echogenicity was naturally coarse and hypoechoic to the spleen. Vascular and biliary tracts were of normal volume with no evidence of congestion. The gallbladder presented acceptably thin walls with primarily anechoic content. The cystic and common bile ducts were normal. No pathological hepatic lymphadenopathy was evident. No overt structural evidence of inflammatory, infiltrative or regenerative pathology was evident.

**INVOICE**

76349

**DATE**

8/1/23



**PATIENT**

Ellie Dean

**SPECIES**

Canine

**BREED**

Maltese

**SEX**

Spayed female

**AGE**

7 years

**WEIGHT**

9.98 lbs

**Gastrointestinal**

Examination of the **gastrointestinal tract** revealed a stomach and intestine free of stasis, of normal wall thickness, acceptable curvilinear mural detail, and peristaltic activity. Small and large intestine demonstrated normal luminal chyme and stool consistency respectively. No obstructive or overt infiltrative disease was noted. No associated abnormal lymphatic activity was noted.

**Pancreas**

The base and limbs of the **pancreas** were observed to be largely isoechoic to surrounding omental fat. Pancreatic duct and capsular contour were acceptably normal and parenchyma respected normal curvilinear patterns. No overt evidence of active inflammatory or neoplastic disease was noted.

**ULTRASONOGRAPHIC FINDINGS**

Structurally **unremarkable** abdomen.

Mild, degenerative renal changes with pinpoint nephrolithiasis, non-obstructive.

**INTERPRETATION OF THE FINDINGS & FURTHER RECOMMENDATIONS**

There was no structural evidence of Cushing's disease.

**INTERPRETED BY**

Eric Lindquist, DMV  
DABVP, Cert. IVUSS

**IMAGING PERFORMED BY**

Ashley Whitesell

**HOSPITAL NAME**

Dickson AC

**REFERRING VET**

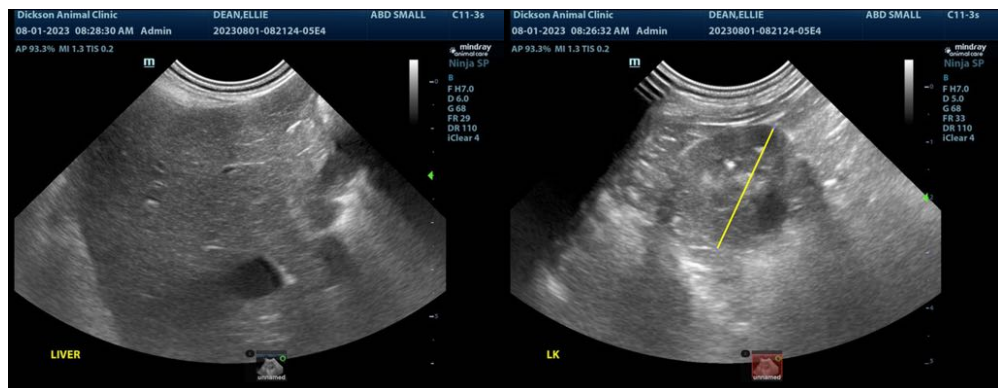
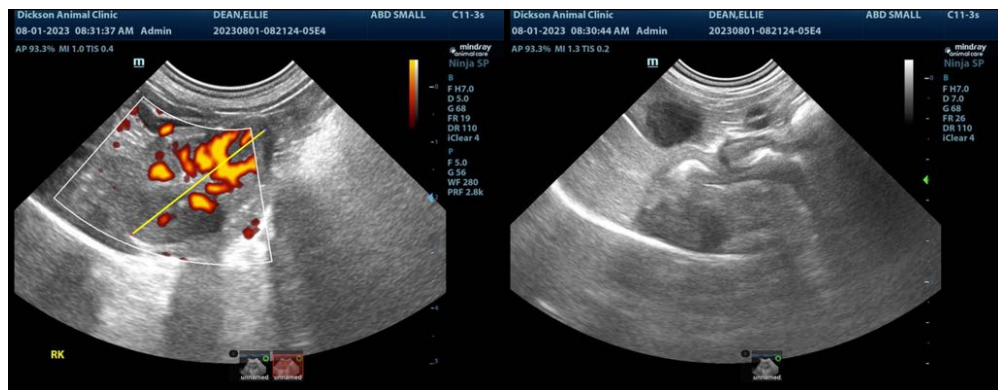
Dr. Hovis

**INVOICE**

76349

**DATE**

8/1/23





**PATIENT**

Ellie Dean

**SPECIES**

Canine

**BREED**

Maltese

**SEX**

Spayed female

**AGE**

7 years

**WEIGHT**

9.98 lbs

**INTERPRETED BY**

Eric Lindquist, DMV  
DABVP, Cert. IVUSS

**IMAGING PERFORMED BY**

Ashley Whitesell

**HOSPITAL NAME**

Dickson AC

**REFERRING VET**

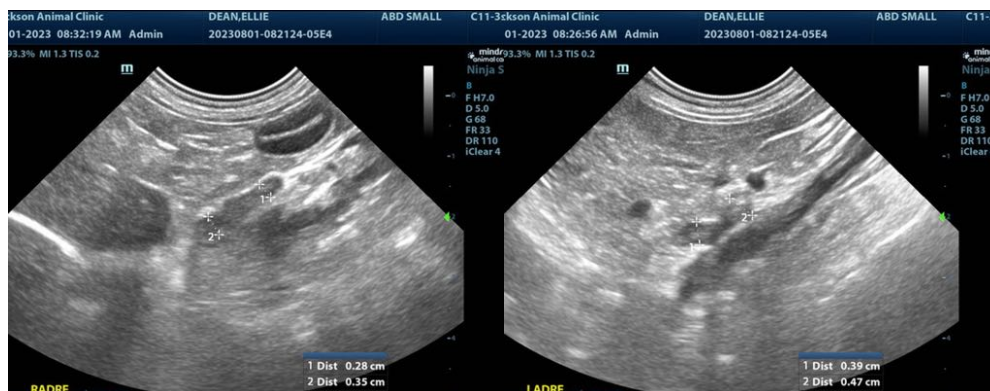
Dr. Hovis

**INVOICE**

76349

**DATE**

8/1/23



The information and recommendations provided are based on the images presented by the referring veterinarian/sonographer. No evaluation can be communicated regarding pathology that was not visible in the image/video clips provided.

Thank you for this referral. If the clinical or image interpretation does not parallel your findings or if I can be of any further assistance please contact me.

**Eric Lindquist**, DMV, DABVP, Cert. IVUSS, CEO of SonoPath.com  
info@SonoPath.com