

**PATIENT**

Cookie Cangialosi

**SPECIES**

Canine

**BREED**

Toy Poodle

**SEX**

Spayed female

**AGE**

1 year

**WEIGHT**

8.5 lbs

**INTERPRETED BY**

Eric Lindquist, DMV  
DABVP, Cert. IVUSS

**IMAGING PERFORMED BY**

Jenn

**HOSPITAL NAME**

Rockaway AH

**REFERRING VET**

Dr. Ascot

**INVOICE**

76338

**DATE**

8/1/23

**PRESENTING CLINICAL SIGNS**

History: anorexia, increased WBC Current meds IVF P Lyte Cerenia, Unasyn  
Abnormal PE/Chem/CBC/UA Results: WBC 24.7 K Neu 18.7 Mono 1.3K remainder WNL CpL normal

**ULTRASONOGRAPHIC EXAMINATION OF THE ABDOMEN**

**Urinary System**

The **urinary bladder**, trigone, and pelvic urethra presented normal thicknesses and normal tone. The ureters were not visible which is normal. No uroliths or sediment were visualized and anechoic urine was present. No evidence of inflammatory or neoplastic changes was noted. Ureteral papillae were normal.

The **kidneys** revealed normal size and structure, corticomedullary definition and ratio for this age. The cortices presented largely uniform texture with normal echogenic relationship to liver and spleen. Medullary structure differed distinctly from the cortex and no evidence of pelvic dilation was present. The capsules were acceptably uniform without significant irregularities. The left kidney measured 3.84 cm. The right kidney measured 4.28 cm.

**Adrenal Glands**

The left **adrenal gland** was subnormal in size and width measuring 1.82 x 0.21 cm at the caudal pole and 0.29 cm at the cranial pole. The right adrenal gland was at the low normal in size and measured 1.26 x 0.33 cm at the caudal pole and 0.84 cm at the cranial pole.

**Spleen**

The **spleen** presented a smooth homogeneous parenchyma hyperechoic to liver and renal cortical parenchyma. The capsule was smooth without noticeable expansion or deviation from within the spleen or adjacent pathology. The splenic vasculature demonstrated normal volume without signs of congestion or thrombosis. No sonographic evidence of acute or chronic inflammatory, neoplastic, or infarctual changes was noted.

**Liver**

The **liver** images submitted revealed subjectively normal liver size, contour, and structure. Parenchymal echogenicity was naturally coarse and hypoechoic to the spleen. Vascular and biliary tracts were of normal volume with no evidence of congestion. The gallbladder presented acceptably thin walls with primarily anechoic content. The cystic and common bile ducts were normal. No pathological hepatic lymphadenopathy was evident. No overt structural evidence of inflammatory, infiltrative or regenerative pathology was evident.



## PATIENT

Cookie Cangialosi

## SPECIES

Canine

## BREED

Toy Poodle

## SEX

Spayed female

## AGE

1 year

## WEIGHT

8.5 lbs

## INTERPRETED BY

Eric Lindquist, DMV  
DABVP, Cert. IVUSS

## IMAGING PERFORMED BY

Jenn

## HOSPITAL NAME

Rockaway AH

## REFERRING VET

Dr. Ascot

## INVOICE

76338

## DATE

8/1/23

## Gastrointestinal

Examination of the **gastrointestinal tract** revealed a stomach and intestine free of stasis, of normal wall thickness, acceptable curvilinear mural detail, and peristaltic activity. Small and large intestine demonstrated normal luminal chyme and stool consistency respectively. No obstructive or overt infiltrative disease was noted. Soft stool was noted in the colon.

## Pancreas

The base and limbs of the **pancreas** were observed to be largely isoechoic to surrounding omental fat. Pancreatic duct and capsular contour were acceptably normal and parenchyma respected normal curvilinear patterns. No overt evidence of active inflammatory or neoplastic disease was noted.

## Free Abdomen

The iliac lymph nodes were mildly enlarged and rounded. FNA and cytology is indicated. The iliac lymph node measured 1.0 x 1.2 cm.

## ULTRASONOGRAPHIC FINDINGS

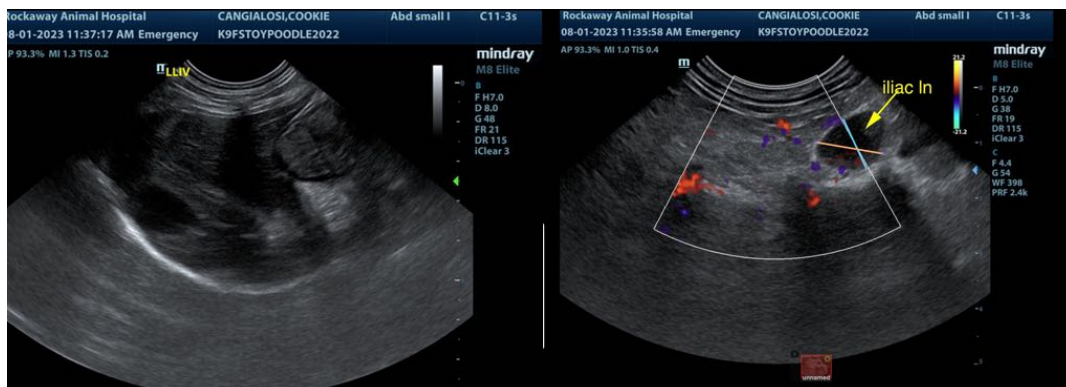
Iliac lymphadenopathy.

Slightly subnormal left adrenal size.

Unremarkable abdomen otherwise.

## INTERPRETATION OF THE FINDINGS & FURTHER RECOMMENDATIONS

FNA, cytology and culture is indicated. Screening for Addison's is indicated; otherwise, no evidence of pathology.





**PATIENT**

Cookie Cangialosi

**SPECIES**

Canine

**BREED**

Toy Poodle

**SEX**

Spayed female

**AGE**

1 year

**WEIGHT**

8.5 lbs

**INTERPRETED BY**

Eric Lindquist, DMV  
DABVP, Cert. IVUSS

**IMAGING PERFORMED BY**

Jenn

**HOSPITAL NAME**

Rockaway AH

**REFERRING VET**

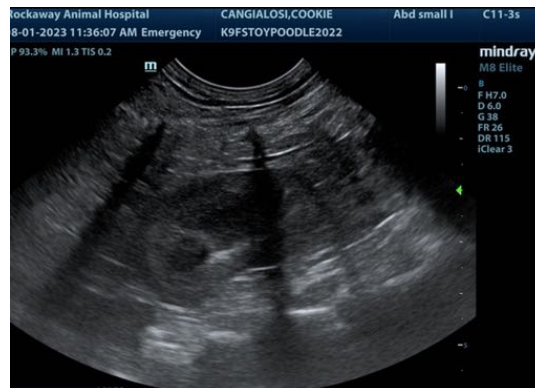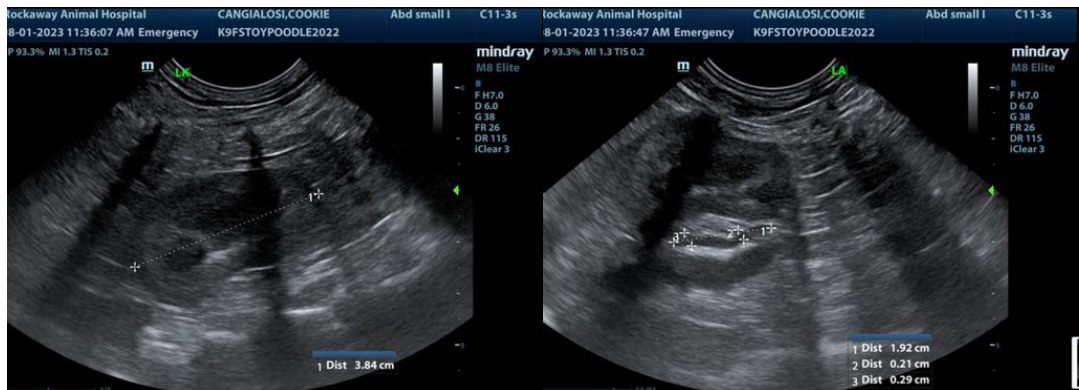
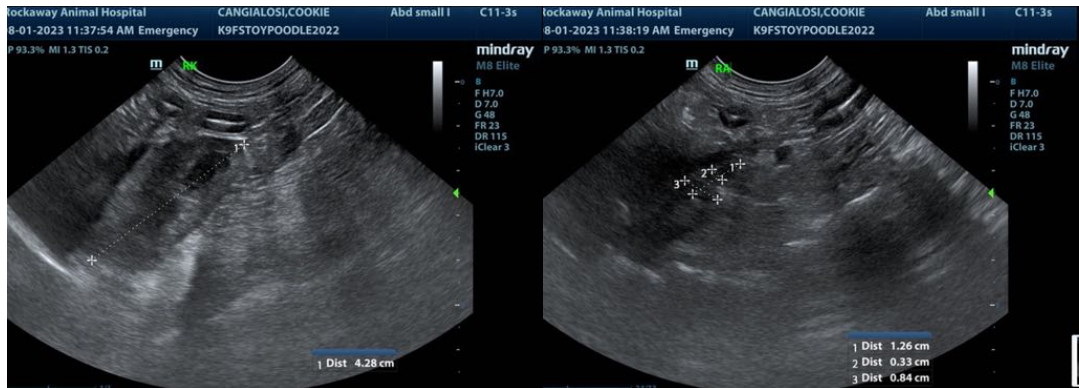
Dr. Ascot

**INVOICE**

76338

**DATE**

8/1/23



The information and recommendations provided are based on the images presented by the referring veterinarian/sonographer. No evaluation can be communicated regarding pathology that was not visible in the image/video clips provided.

Thank you for this referral. If the clinical or image interpretation does not parallel your findings or if I can be of any further assistance please contact me.

**Eric Lindquist**, DMV, DABVP, Cert. IVUSS, CEO of SonoPath.com  
info@SonoPath.com