



**PATIENT**

Bruno Phillips

**SPECIES**

Canine

**BREED**

Golden Retriever

**SEX**

Neutered male

**AGE**

7 ½ years

**WEIGHT**

38.5 kg

**INTERPRETED BY**

Eric Lindquist, DMV  
DABVP, Cert. IVUS

**IMAGING PERFORMED BY**

Dr. Trudeau

**HOSPITAL NAME**

Petworks VH

**REFERRING VET**

Dr. Trudeau

**INVOICE**

76367

**DATE**

8/1/23

**PRESENTING CLINICAL SIGNS**

History: Weight loss at a rapid weight - down over past year or so from 51 kg to 38.5 kg, past month has gone down about 4.5 kg . Recently neutered (about 2 months ago) and bloodwork was all wnl. E/D well, some decrease in energy.

Abnormal PE/Chem/CBC/UA Results: May 2-23 CBC/Chem - WNL

**ULTRASONOGRAPHIC EXAMINATION OF THE ABDOMEN**

**Urinary System**

The **urinary bladder**, trigone, and pelvic urethra presented normal thicknesses and normal tone. The ureters were not visible which is normal. No uroliths or sediment were visualized and anechoic urine was present. No evidence of inflammatory or neoplastic changes was noted. Ureteral papillae were normal.

The prostate was uniform, yet mildly hypoechoic to the surrounding mesentery and measured 1.74 cm. If straining to urinate is an issue then FNA is indicated.

The **kidneys** revealed normal size and structure, corticomedullary definition and ratio for this age. The cortices presented largely uniform texture with normal echogenic relationship to liver and spleen. Medullary structure differed distinctly from the cortex and no evidence of pelvic dilation was present. The capsules were acceptably uniform without significant irregularities. The right kidney measured 6.77 cm.

**Adrenal Glands**

Both **adrenal glands** were visualized and recognized as having normal shape, size, position and echogenicity for this breed. The phrenic vasculature, glandular echogenicity and detail were unremarkable. Capsule, cortex, and medullary definition were normal for this age patient. The right adrenal gland measured 0.39 cm at the caudal pole and 0.42 cm at the cranial pole. The left adrenal gland measured 0.51 cm at the cranial pole and 0.56 cm at the caudal pole.

**Spleen**

The **spleen** in this patient was mildly enlarged with uniform parenchyma and was folded upon itself cranially and caudally. This is a positional variant and is not pathological. There was no evidence of significant disease.

**Liver**

The **liver** images from right and left intercostal as well as subcostal views revealed subjectively normal liver size, contour, and structure. Increased portal markings were noted. Some age-related parenchymal remodeling was noted but likely not clinically significant at this time. Vascular and biliary tracts were of normal volume and no evidence of congestion was noted. The gallbladder presented some dependent debris with essentially normal contour. The cystic and common bile ducts were normal. No overt evidence of active inflammatory, infiltrative or regenerative pathology was noted but should be paired with current or past LE elevations regarding any clinical significance to this presentation. The hepatic lymph nodes were unremarkable.



## PATIENT

Bruno Phillips

## SPECIES

Canine

## BREED

Golden Retriever

## SEX

Neutered male

## AGE

7 ½ years

## WEIGHT

38.5 kg

## INTERPRETED BY

Eric Lindquist, DMV  
DABVP, Cert. IVUSS

## IMAGING PERFORMED BY

Dr. Trudeau

## HOSPITAL NAME

Petworks VH

## REFERRING VET

Dr. Trudeau

## INVOICE

76367

## DATE

8/1/23

## Gastrointestinal

Examination of the **gastrointestinal tract** revealed a stomach and intestine free of stasis, of normal wall thickness, acceptable curvilinear mural detail, and peristaltic activity. Small and large intestine demonstrated normal luminal chyme and stool consistency respectively. No obstructive or overt infiltrative disease was noted. No associated abnormal lymphatic activity was noted.

## Pancreas

The base and limbs of the **pancreas** were observed to be largely isoechoic to surrounding omental fat. Pancreatic duct and capsular contour were acceptably normal and parenchyma respected normal curvilinear patterns. No overt evidence of active inflammatory or neoplastic disease was noted.

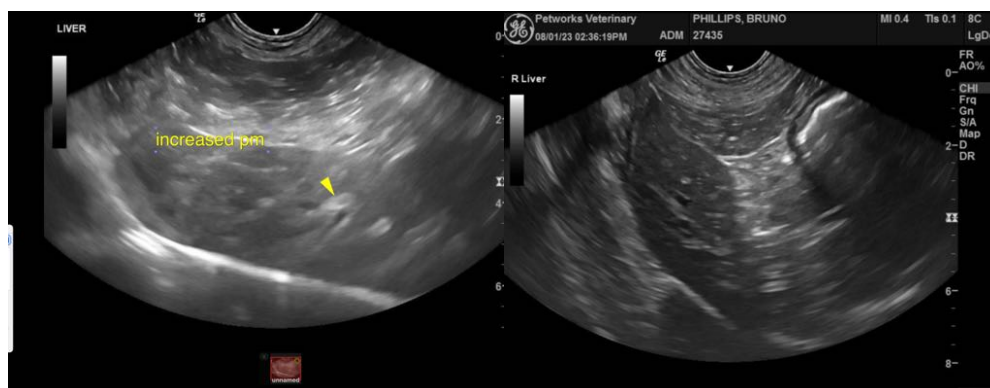
## ULTRASONOGRAPHIC FINDINGS

Unremarkable abdomen with prominent prostate.

## INTERPRETATION OF THE FINDINGS & FURTHER RECOMMENDATIONS

Given that the patient was recently neutered the prostate is likely a normal, progressive reduction in size, yet persistently prominent. The cause of weight loss is unclear.

Maldigestion panel, three view chest radiographs and full CNS examination is recommended to examine for occult disease that could be responsible for the weight loss. Evaluation for competitive eating environments should also be considered.





**PATIENT**

Bruno Phillips

**SPECIES**

Canine

**BREED**

Golden Retriever

**SEX**

Neutered male

**AGE**

7 ½ years

**WEIGHT**

38.5 kg

**INTERPRETED BY**

Eric Lindquist, DMV  
DABVP, Cert. IVUSS

**IMAGING PERFORMED BY**

Dr. Trudeau

**HOSPITAL NAME**

Petworks VH

**REFERRING VET**

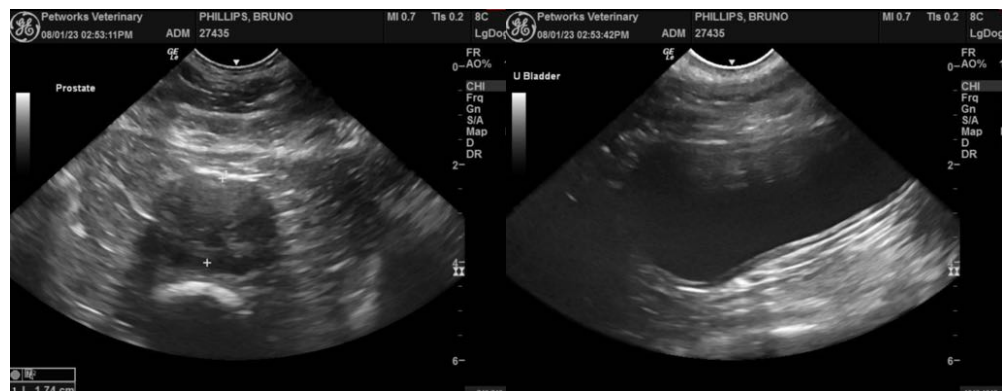
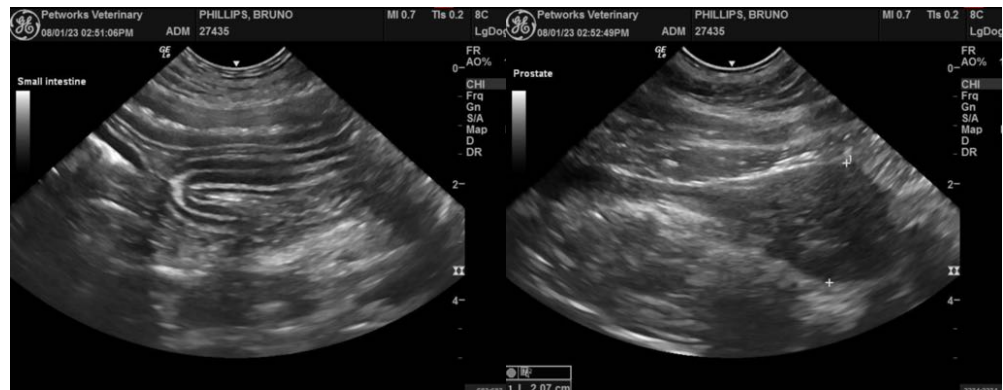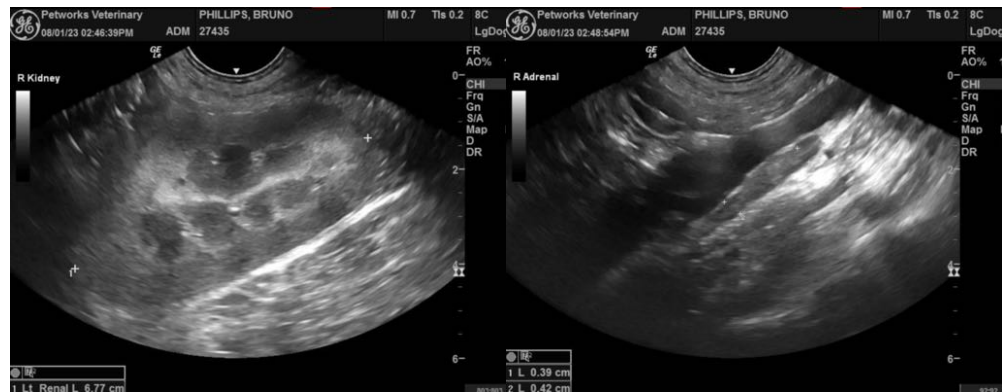
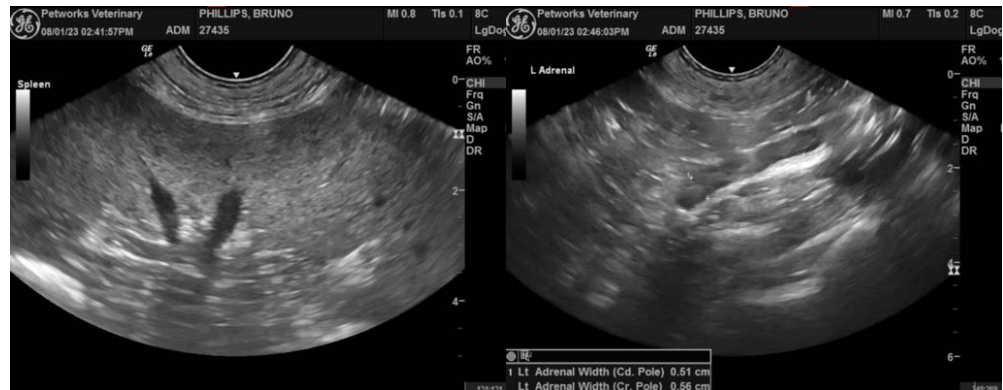
Dr. Trudeau

**INVOICE**

76367

**DATE**

8/1/23





**PATIENT**

Bruno Phillips

**SPECIES**

Canine

**BREED**

Golden Retriever

**SEX**

Neutered male

**AGE**

7 ½ years

**WEIGHT**

38.5 kg

**INTERPRETED BY**

Eric Lindquist, DMV  
DABVP, Cert. IVUSS

**IMAGING  
PERFORMED BY**

Dr. Trudeau

**HOSPITAL NAME**

Petworks VH

**REFERRING VET**

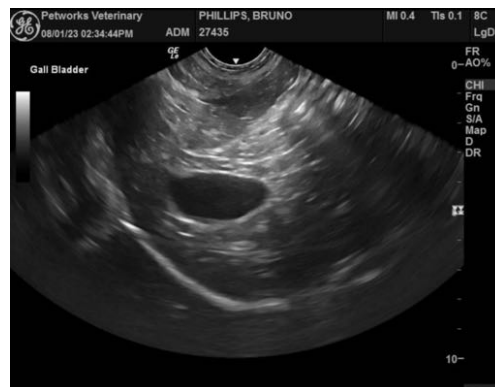Dr. Trudeau

**INVOICE**

76367

**DATE**

8/1/23



The information and recommendations provided are based on the images presented by the referring veterinarian/sonographer. No evaluation can be communicated regarding pathology that was not visible in the image/video clips provided.

Thank you for this referral. If the clinical or image interpretation does not parallel your findings or if I can be of any further assistance please contact me.

**Eric Lindquist**, DMV, DABVP, Cert. IVUSS, CEO of SonoPath.com  
info@SonoPath.com