



PATIENT PRESENTING CLINICAL SIGNS

Stevie ALS recheck cardiac status

SPECIES ULTRASONOGRAPHIC EXAMINATION OF THE HEART

Feline	FELINE CARDIAC PARAMETERS	BODY WEIGHT (kg)	HR (BPM)	IVSd (cm)	LVIDd (cm)	LVWd (cm)	FS (%)	EF (%)
	NORMAL PARAMETER	-----	150-240	0.3-0.6	1.0-2.1	0.25-0.6	35-67	80-100
	PATIENT		240	0.45	1.3	0.45	50	90
DSH	FELINE CARDIAC PARAMETERS	LA/AO (Boon)	LA/AO HEART BASE (Sisson)	LA 2D 4-chamber long axis AS to FW (Sisson) (cm)	LVOT VEL. (m/s)	RVOT VEL. (m/s)	IVRT (m/)	
	NORMAL PARAMETER	<1.5	0.88-1.79	0.7-1.7	<1.6	<1.3	40-60	
	PATIENT	1.13	--	1.2	2.2	3.55	NM	

Adapted from June Boon, Veterinary Echocardiography, 1998
 Sisson D et al. JVIM 1991; 5: 232, Jacobs et al. Am J Vet Res 1985; 46:1705

5.3 Pounds

Cardiac Presentation

The echocardiogram in this patient demonstrated normal **left atrial** size based on 3 separate LA measurements. Minor **mitral** insufficiency noted. The **left ventricle** presented normal thicknesses with linear contour and was not dilated nor restricted. The **myocardium** presented normal echogenicity without subjective evidence of significant fibrotic or ischemic disease. **Contractility** of the ventricular walls was adequate and in normal range for this patient evidenced by the fractional shortening measurement and subjective evaluation of the different regions and angles of the myocardium. The **left ventricular outflow** tract demonstrated normal laminar flow and subjective structural integrity. The **right atrium** was enlarged. **Tricuspid** insufficiency noted at 2.91 m/sec. The **right ventricle** was mildly thickened. **Pulmonic** valve presented excessive outflow velocity. No visible **pericardial** or free pleura fluid was noted or extra cardiac pathology in the visible planes. The cranial **mediastinum** and **pericardial** regions were free of masses in the visible window.

INTERPRETED BY

Eric Lindquist, DMV
 DABVP, Cert. IVUSS

IMAGING PERFORMED BY

Diane McFadden

HOSPITAL NAME

Rockaway AH

REFERRING VET

Dr. Maniar

ULTRASONOGRAPHIC FINDINGS

- Pulmonic stenosis pattern, compensated at this time
- Minor mitral insufficiency

INTERPRETATION OF THE FINDINGS & FURTHER RECOMMENDATIONS

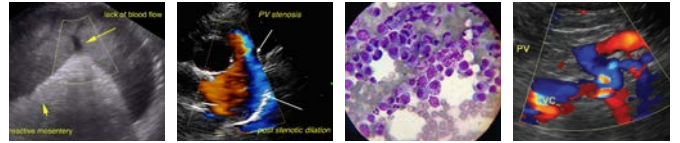
The patient was agitated at the time of the sonogram and minimal views were obtained. However, views obtained were adequate to diagnose pulmonic stenosis. Cardiology referral for potential intervention recommended, yet the velocities are adequately compensated at this time.

INVOICE

40001

DATE

8/1/22



PATIENT

Stevie ALS

SPECIES

Feline

BREED

DSH

SEX

Neutered Male

AGE

5 Months

WEIGHT

5.3 Pounds

INTERPRETED BY

Eric Lindquist, DMV

DABVP, Cert. IVUSS

IMAGING PERFORMED BY

Diane McFadden

HOSPITAL NAME

Rockaway AH

REFERRING VET

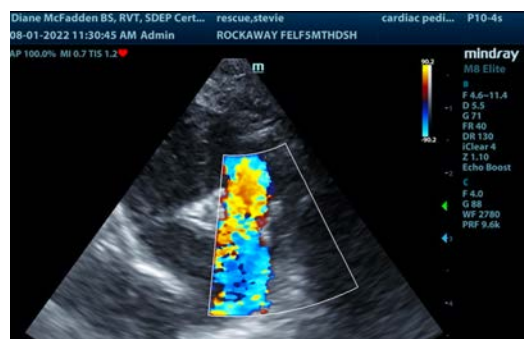
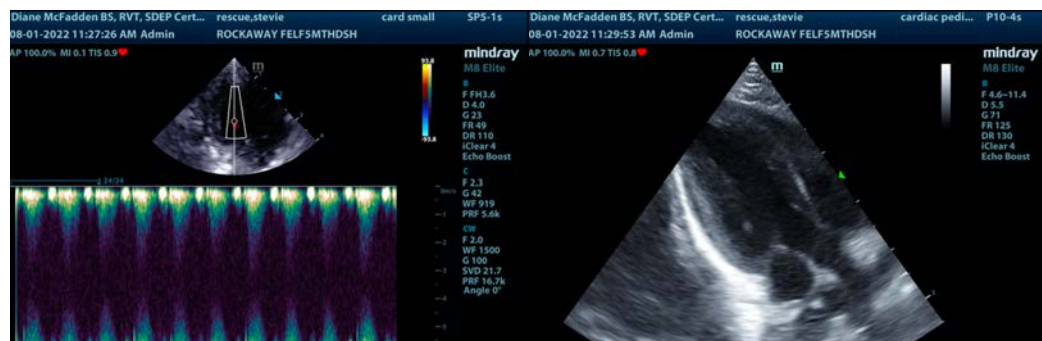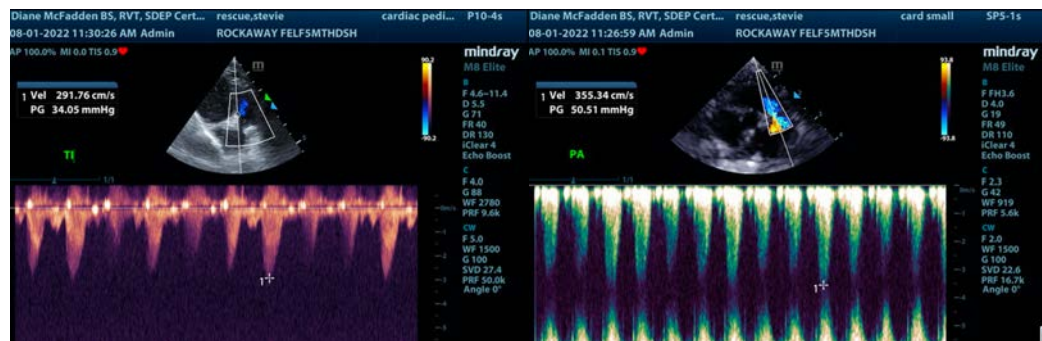
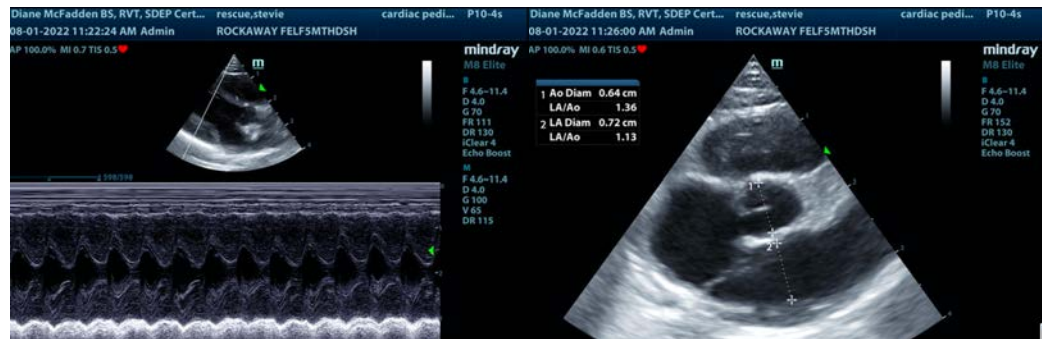
Dr. Maniar

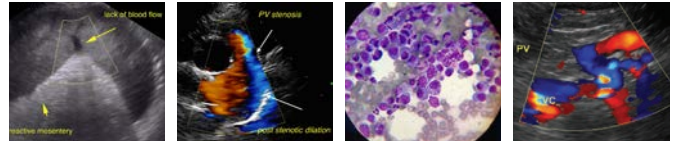
INVOICE

40001

DATE

8/1/22





PATIENT

Stevie ALS

The information and recommendations provided are based on the images presented by the referring veterinarian/sonographer. No evaluation can be communicated regarding pathology that was not visible in the image/video clips provided.

SPECIES

Feline

Thank you for this referral. If the clinical or image interpretation does not parallel your findings or if I can be of any further assistance please contact me.

Eric Lindquist, DMV, DABVP, Cert. IVUSS, CEO of SonoPath.com

info@SonoPath.com

BREED

DSH

Pulmonic Stenosis

SEX

Neutered Male

<http://www.sonopath.com/PS>

<http://www.sonopath.com/EchoModler>

AGE

5 Months

WEIGHT

5.3 Pounds

Description: Pulmonic stenosis (PS) is a congenital anomaly that causes right ventricular outflow obstruction and can be classified as valvular, subvalvular, or supravalvular. It is one of the top three congenital heart defects found in dogs, occurring at a frequency of 11-20%, and is often accompanied by subaortic stenosis (SAS) (25.5-41%) and patent ductus arteriosus (PDA) (11-27.7%). In Boxers and English Bulldogs, the subvalvular form may be accompanied by an anomalous left coronary artery with an enlarged right coronary counterpart. English Bulldogs, Boxers, West Highland White and other Terriers, Miniature Schnauzers, Chihuahuas, Samoyeds, Mastiffs, Boykin Spaniels, and Beagles have a prominent breed predisposition for PS. (Reports suggest that it is inherited in Beagles.) One may occasionally see it in German Shepherds, Spaniels, and Retrievers, and male English Bulldogs and Mastiffs are more commonly affected than females. Although PS can occur in cats, it is very uncommon.

INTERPRETED BY

Eric Lindquist, DMV

DABVP, Cert. IVUSS

IMAGING PERFORMED BY

Diane McFadden

HOSPITAL NAME

Rockaway AH

REFERRING VET

Dr. Maniar

Valvular stenosis is by far the most frequent form of PS; it usually entails the excessive thickening or fusion of the leaflet extremities. More than 80% of dogs with PS have some degree of valvular dysplasia. Thickened valvular conformation causes the valve to be less mobile, whereas thinly fused valves tend to be excessively mobile and bow toward the pulmonary artery during systole. In cases of annulus hypoplasia, there is no fusion of the cusps and minimal valvular mobility. Histologically, one can detect a thickening of the valve's spongiosa along with an overproduction of valvular collagen. Failure of embryonic valve primordial conversion has been postulated as the cause of abundant tissue formation.

INVOICE

40001

DATE

8/1/22

Regardless of the type of obstruction, the pathological trajectory begins with an increased resistance to systolic ejection resulting in concentric right ventricular hypertrophy. Dynamic obstruction during systole can also occur secondary to hypertrophy of the right ventricle and/or the papillary muscles, particularly during exercise or under stress. In severe cases, the left ventricular wall may in fact be thinner than the wall of the right ventricle, which has undergone hypertrophy. In moderate to severe cases, concentric left ventricular hypertrophy may occur due to poor right ventricular output and resultant poor left-sided volume. In rare cases, severe hypertrophy of the ventricular septum can lead to a narrowing of the left ventricular outflow tract



PATIENT

Stevie ALS

SPECIES

Feline

BREED

DSH

SEX

Neutered Male

AGE

5 Months

WEIGHT

5.3 Pounds

(LVOT), which is similar to what transpires in cases of hypertrophic cardiomyopathy. Configuration changes of the right ventricle (RV) lead to tricuspid regurgitation, right atrial dilation, increased right-sided diastolic pressures, and eventual right-sided heart failure in moderate to severe cases. A flattening of the ventricular septum may occur as right-sided pressures approach those of the left side. If right ventricular pressures exceed those of the left ventricle (LV), paradoxical septal motion may be observed. Pulmonary artery dilation may also be present. Impeded coronary artery flow may cause sudden death, especially in English Bulldogs where an anomaly of the left main coronary artery is prominent. An aberrant coronary artery, which can be characterized by a slight bulge at the aortic root, may be detected in English Bulldogs and Boxers during an angiogram; this is known as the “aortic root sign.” This particular aberration of the coronary artery arises from the right coronary ostium, which permits the blood to course across the right ventricular outflow tract (RVOT), making the latter vulnerable to injury during balloon valvuloplasty (BV) or patch graft procedures. In certain cases of subvalvular stenosis, a dilated right coronary artery and anomalous left coronary artery may be seen sonographically.

Clinical Signs: The clinical signs of PS vary with the degree of stenosis in the individual. In moderate to severe cases, exercise intolerance, failure to grow, syncope, ascites, and abnormal jugular pulsations all may occur. A patient with PS presents with a harshly auscultable murmur that is typically found at the left heart base and exhibits a crescendo-decrescendo sound. Differential diagnoses for the murmur include: SAS; an atrial septal defect (ASD) with right-sided volume overload; tetralogy of Fallot; and left-to-right PDA. Although pulses may be diminished in severe cases, they are typically normal. A secondary right apical tricuspid murmur may also be present, as right-sided volume overload contributes to valvular insufficiency.

INTERPRETED BY

Eric Lindquist, DMV

DABVP, Cert. IVUSS

IMAGING PERFORMED BY

Diane McFadden

HOSPITAL NAME

Rockaway AH

REFERRING VET

Dr. Maniar

Diagnostics: ECG changes in moderate to severe cases often reveal deep S waves in leads I, II, and III, as well as aVF, with the occasional presence of premature ventricular complexes. In mild to moderate cases, survey radiographs may not show any visible abnormalities; however, in moderate to severe cases, they will reveal a prominent cranial waist on lateral views and a poststenotic bulge of the pulmonary artery at the one o'clock position on dorsal-ventral or ventral-dorsal views. Right atrial enlargement and tracheal elevation at the cranial heart base may also be present. Pulmonary output will likely be lower, resulting in smaller than normal pulmonary arteries. Pulmonic and aortic stenoses give rise to concentric hypertrophy, which is less apparent on survey radiographs in early and mild cases than eccentric hypertrophy, which is found in cases of volume overload, such as atrial septal defect (ASD) or ventricular septal defect (VSD). Other factors affecting radiographic interpretation are breed-specific thoracic conformation, body score, positioning, practitioner experience, and variations in respiratory and cardiac phases.

INVOICE

40001

DATE

8/1/22

It may be useful to measure NT-proBNP levels in young puppies with murmurs as a means of screening for congenital anomalies.

Echocardiography is the diagnostic test of choice, as it will yield a definitive diagnosis of PS, permit a structural evaluation of the heart, and enable Doppler quantification of the pulmonic velocities and pressure gradients. A normal pulmonic velocity in non-sedated dogs is considered to be less than 1.7 m/s, with RVOT pressures ranging between 20-25 mmHg. Obtaining right parasternal short axis as well as left short and long axis views allows the practitioner to avoid lung air interference, which permits an accurate visualization of



PATIENT

Stevie ALS

SPECIES

Feline

BREED

DSH

SEX

Neutered Male

AGE

5 Months

WEIGHT

5.3 Pounds

INTERPRETED BY

Eric Lindquist, DMV

DABVP, Cert. IVUSS

IMAGING PERFORMED BY

Diane McFadden

HOSPITAL NAME

Rockaway AH

REFERRING VET

Dr. Maniar

INVOICE

40001

DATE

8/1/22

the RVOT. Pulse wave (PW) Doppler is used to identify the location of the murmur, while continuous wave (CW) Doppler demonstrates the severity of the lesion by quantifying the velocity and pressure gradient across the defect. PW may reveal turbulence and localize an increase in outflow velocity at the level of the stenosis, which can later be quantified using CW. Doppler echocardiography yields pressure gradients and velocity measurements of the pulmonic apparatus, measured between the right ventricle and the main pulmonary artery, that enable PS to be classified as follows: mild = 20-50 mmHg (2-3.5 m/sec); moderate = 50-80 mmHg (3.5-4.5 m/sec); and severe = any value greater than 80 mmHg (> 4.5 m/sec). Variable degrees of concurrent pulmonic insufficiency may also be detectable. Further investigation may disclose turbulence and dynamic obstruction in the RVOT as well as identify any secondary tricuspid insufficiency or shunting lesions, such as ASD and VSD, which can occur simultaneously. Typical findings include: concentric hypertrophy of the right ventricular free wall and interventricular septum; a flattened septum due to excessive RV pressure; prominent papillary muscle formation; variable narrowing of the RVOT; varying degrees of right atrial enlargement; and post-stenotic main pulmonary artery dilation. A “double-chambered right ventricle” may be seen in cases of severe obstruction. This term is used to describe the right ventricle when it is structurally divided into a low-pressure region (infundibulum) and a high-pressure region (right ventricular apex) by a fibromuscular ridge.

Treatment: One typically treats moderate to severe cases of PS (i.e., when the pressure gradient is greater than 60 mmHg) with BV, a surgical patch graft technique, or a surgical right ventricle/pulmonary artery (RV/PA) bypass. That said, fully-grown animals with Doppler gradients below 50-80 mmHg that do not suffer from other complicating lesions (i.e., ASD, VSD, or tricuspid insufficiency) can lead relatively normal lives and do not necessarily require treatment. The goal in treatable cases is to reduce the systolic pressure gradient to a mild range (below 60-80 mmHg) prior to the development of heart failure signs. BV should also be considered in patients with pressure gradients greater than 60 mm Hg and concomitant tricuspid dysplasia or significant right ventricular concentric hypertrophy. Beta blockers may prevent sudden death by limiting excessive tachycardia if BV is not an option. BV is most successful when the pulmonary annulus is adequately developed and features thin, fused valves. Results vary when there are complicating lesions, such as annulus hypoplasia, RVOT obstruction, concurrent arrhythmia, double-chambered right ventricle, and anomalous right coronary artery. In these cases, ensuring the safe passage of the balloon catheter is more difficult and carries a higher risk of complications. In dogs afflicted by such complicating lesions, and in those that have previously undergone BV and have recurrent stenosis, patch graft or bypass surgery are better options.

The patch graft technique requires the placement of Gore-Tex® material or a pericardial patch over the pulmonic outflow tract. The procedure entails a left fifth intercostal thoracotomy using either inflow occlusion or cardiopulmonary bypass. Redundant valvular tissue can be removed at this time. This procedure often results in pulmonic insufficiency, but it can be tolerated as long as there is tricuspid integrity and pulmonary hypertension is not a factor. Even in the hands of an experienced surgeon, operative mortality is approximately 20-25%. Dogs with an aberrant coronary artery contributing to their PS are not considered candidates for BV or patch graft techniques, and require surgical cardiopulmonary bypass via an RV/PA conduit placement to circumvent the stenosis. This carries a lower risk than a simple patch graft procedure due to the more direct graft placement enabled by the bypass. Yet, the majority of PS patients are responsive to BV, making it the treatment of choice.



PATIENT

Stevie ALS

References:

SPECIES

Feline

Bussadori C, Amberger G, Le Bobinnec G, Lombard CW. Guidelines for the echocardiographic studies of suspected subaortic and pulmonic stenosis. *J Vet Cardiol* 2000;2:15-22.

BREED

DSH

SEX

Neutered Male

Bussadori C, DeMadron E, Santilli R, et al. Balloon valvuloplasty in 30 dogs with pulmonic stenosis: effect of valvular morphology and annular size on initial and 1-year outcome. *J Vet Intern Med* 2001;15:553-58.

AGE

5 Months

Goodwin J, Tilley L, eds. *Manual of Canine and Feline Cardiology 3rd ed.* Philadelphia, PA: WB Saunders; 2001:282-85.

WEIGHT

5.3 Pounds

Kienle R, Thomas W, Nyland T, Mattoon J. Pulmonic stenosis: anatomy and physiology. In: Nyland TG, Mattoon JS, eds. *Small Animal Diagnostic Ultrasound 2nd ed.* Philadelphia, PA: WB Saunders; 2002:382-84.

INTERPRETED BY

Eric Lindquist, DMV

DABVP, Cert. IVUSS

Orton E, Bonagura J. Current indications for cardiac surgery. In: Bonagura J, ed. *Current Veterinary Therapy XIII.* Philadelphia, WB Saunders; 2000:745-46.

IMAGING PERFORMED BY

Diane McFadden

Oyama M, Sisson D. Evaluation of canine congenital heart disease using an echocardiogram algorithm. *J Am Anim Hosp Assoc* 2001;37:519-35.

HOSPITAL NAME

Rockaway AH

REFERRING VET

Dr. Maniar

INVOICE

40001

DATE

8/1/22