



**PATIENT**

Sasha Fitzpatrick

**SPECIES**

Canine

**BREED**

Mixed

**SEX**

Spayed Female

**AGE**

2 Years

**WEIGHT**

61 Pounds

**PRESENTING CLINICAL SIGNS**

Recheck of PDJ/stomach after 24 hour fast. Last fed at 3:30pm Sunday 7/31.  
Abnormal PE/Chem/CBC/UA Results: N/A

**LIMITED ULTRASONOGRAPHIC EXAMINATION**

The pylorus was moderately thickened (up to 1.0 cm), with concentric thickening up to 2.0 cm. Some retention of ingesta was noted in the stomach. Some reactive mesentery was persistent around the pyloric outflow. The upper duodenum presented increased submucosal echogenicity, as did much of the small intestine, indicative of chronicity. An epigastric lymph node was slightly enlarged, reactive, measuring 0.66 cm in width.

**ULTRASONOGRAPHIC FINDINGS**

- Thickened pylorus

**INTERPRETATION OF THE FINDINGS & FURTHER RECOMMENDATIONS**

The inflammation around the pyloric outflow noted on the prior sonogram appears to have subsided somewhat. However, persistent retention of ingesta noted. I recommend exploratory surgery in this patient with the objective of evacuating the stomach, obtaining gastric biopsies, and manual evaluation of the pylorus. Pyloroplasty may be in order in this patient, depending upon surgical findings. Dysfunctional pylorus suspected. Canned BID feedings warranted. Underlying helicobacter may be an issue. However, significant stasis is noted with pyloric hypertrophy and stenotic pattern. Bilroth procedure may be appropriate as well depending upon surgical findings at the time. GI and lymph node biopsies and culture recommended.

**INTERPRETED BY**

Eric Lindquist, DMV  
DABVP, Cert. IVUSS

**IMAGING PERFORMED BY**

Amy Mayhew, LVT

**HOSPITAL NAME**

SVS Imaging MI

**REFERRING VET**

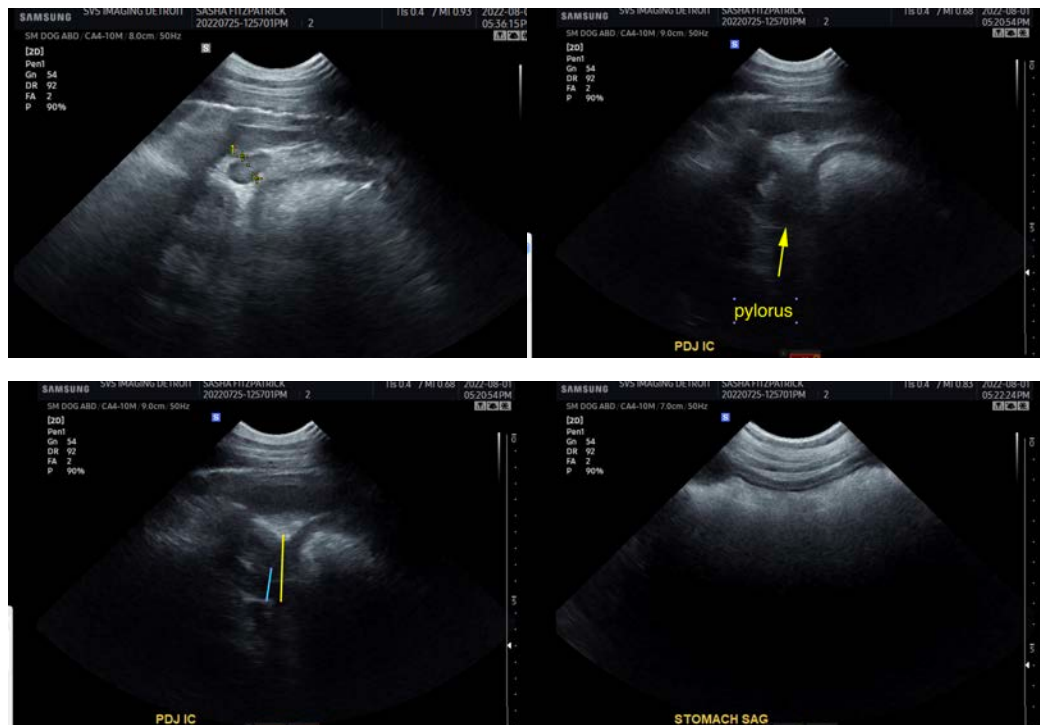
Dr. Fit'z Bayside AC

**INVOICE**

40028

**DATE**

8/1/22



**IMAGING PERFORMED BY**

SVS Mobile Imaging MI 734-637-7711  
svsimagingmi@gmail.com



EDUCATIONAL TELECONSULTATION SERVICES™  
1-800-838-4268 info@sonopath.com SonoPath.com

**PATIENT**

Sasha Fitzpatrick

**SPECIES**

Canine

**BREED**

Mixed

**SEX**

Spayed Female

**AGE**

2 Years

**WEIGHT**

61 Pounds

**INTERPRETED BY**

Eric Lindquist, DMV  
DABVP, Cert. IVUSS

**IMAGING PERFORMED BY**

Amy Mayhew, LVT

**HOSPITAL NAME**

SVS Imaging MI

**REFERRING VET**

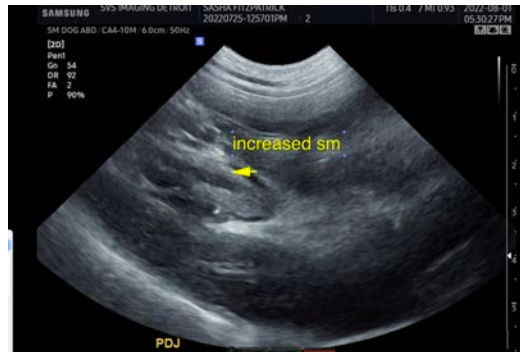
Dr. Fit'z Bayside AC

**INVOICE**

40028

**DATE**

8/1/22



The information and recommendations provided are based on the images presented by the referring veterinarian/sonographer. No evaluation can be communicated regarding pathology that was not visible in the image/video clips provided.

Thank you for this referral. If the clinical or image interpretation does not parallel your findings or if I can be of any further assistance please contact me.

Eric Lindquist, DMV, DABVP, Cert. IVUSS, CEO of SonoPath.com

[info@SonoPath.com](mailto:info@SonoPath.com)