



PATIENT PRESENTING CLINICAL SIGNS

PATIENT Emma Billings Recently rescued from the streets of North Carolina (beginning of July). Previous history unknown. Patient tested positive for heartworm disease. She has a soft, persistent cough and tachypnea (40bpm). She is currently taking Doxycycline and Prednisone

SPECIES Canine Abnormal PE/Chem/CBC/UA Results: CBC -mild eosinophilia CHEM WNL Blood Pressure - normal Thoracic radiographs - moderate, diffuse bronchial pattern fecal - pending

ULTRASONOGRAPHIC EXAMINATION OF THE HEART

BREED

Pit Bull

SEX

Female

AGE

4 Years

WEIGHT

49 Pounds

CANINE CARDIAC PARAMETERS	MR VMAX (m/s)	TR VMAX (m/s)	LA/AO (Boon method)	LA/AO (Heart Base; Swe)	FS (%)	EF (%)	EPSS (cm)
NORMAL PARAMETER	4.5-5.5	<2.7	1.3	<1.6	28-40	40-100	<0.6
PATIENT			1.15	1.35	41	72	0.55
CANINE CARDIAC PARAMETERS	HR (BPM)	AV VMAX (m/s)	PV MAX (m/s)	BODY WEIGHT (kg)	LA 2D short axis Base view (cm)	LVIDd Avg; 2D and m-mode short axis (cm)	LVIDs Avg; 2D and m-mode short axis (cm)
NORMAL PARAMETER	50-100	0.7-1.7	0.7-1.6	BELOW	BELOW	BELOW	BELOW
PATIENT	126	1.6	1.1		3.86	4.37	

INTERPRETED BY

Eric Lindquist, DMV

DABVP, Cert. IVUSS

IMAGING PERFORMED BY

Dr. Gudrun Gunther

HOSPITAL NAME

New Frontier AMC

REFERRING VET

Dr. Gudrun Gunther

INVOICE

40011

DATE

8/1/22

Cardiac Presentation

The echocardiogram in this patient demonstrated normal **left atrial** size based on 3 separate methods of LA evaluation. The cranial and caudal **mitral valve** leaflets presented normal linear structure, extension in systole, and union in diastole with normal kinesis. The **left ventricle** presented thicknesses with linear contour and was not dilated nor restricted. The **myocardium** presented normal echogenicity without subjective evidence of significant fibrotic or ischemic disease. **Contractility** of the ventricular walls was adequate and in normal range for this patient evidenced by the fractional shortening measurement and subjective evaluation of the different regions of the myocardium. The **left ventricular outflow** tract demonstrated normal laminar flow and subjective structural integrity. The **right atrium** and auricle revealed normal size, structure and content. No evidence of masses was noted. **Tricuspid** valvular assessment demonstrated adequate linear morphology and kinesis. The **right ventricle** was of normal size (1/3 diameter of LV), chordae structure, myocardial echogenicity and thickness. **Pulmonary outflow** tract assessment revealed normal valve structure, laminar flow, and diameter (approx. 1:1 pa/ao ratio). No visible **pericardial** or free pleura fluid was noted. The cranial **mediastinum and pericardial and extra-cardiac regions** were free of masses in the visible window.

ULTRASONOGRAPHIC FINDINGS

- Normal echocardiogram

INTERPRETATION OF THE FINDINGS & FURTHER RECOMMENDATIONS

No evidence of heartworm or other pathology.



PATIENT

Emma Billings

SPECIES

Canine

BREED

Pit Bull

SEX

Female

AGE

4 Years

WEIGHT

49 Pounds

INTERPRETED BY

Eric Lindquist, DMV
DABVP, Cert. IVUSS

IMAGING PERFORMED BY

Dr. Gudrun Gunther

HOSPITAL NAME

New Frontier AMC

REFERRING VET

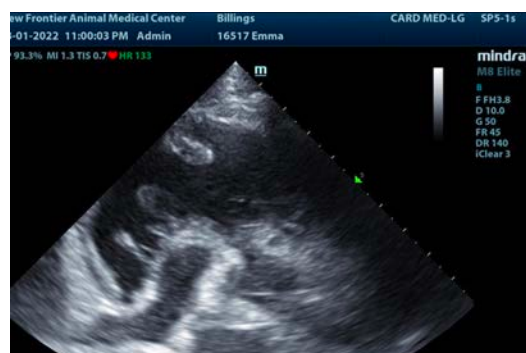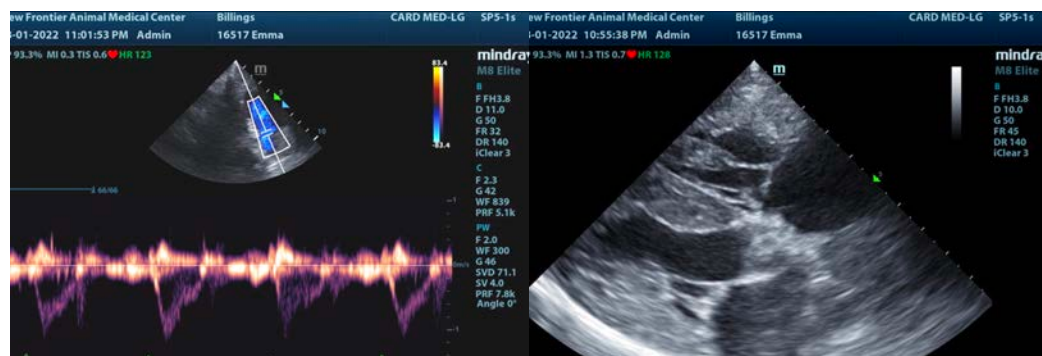
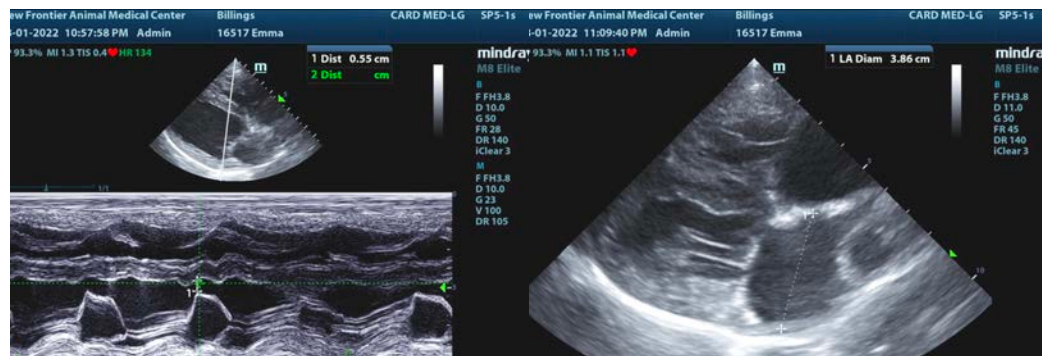
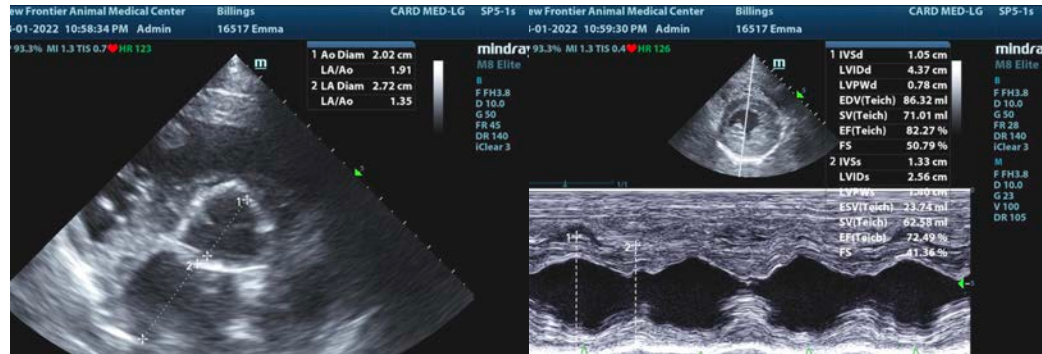Dr. Gudrun Gunther

INVOICE

40011

DATE

8/1/22





PATIENT

Emma Billings

SPECIES

Canine

BREED

Pit Bull

SEX

Female

AGE

4 Years

WEIGHT

49 Pounds

INTERPRETED BY

Eric Lindquist, DMV

DABVP, Cert. IVUSS

**IMAGING
PERFORMED BY**

Dr. Gudrun Gunther

HOSPITAL NAME

New Frontier AMC

REFERRING VET

Dr. Gudrun Gunther

INVOICE

40011

DATE

8/1/22

The information and recommendations provided are based on the images presented by the referring veterinarian/sonographer. No evaluation can be communicated regarding pathology that was not visible in the image/video clips provided.

Thank you for this referral. If the clinical or image interpretation does not parallel your findings or if I can be of any further assistance please contact me.

Eric Lindquist, DMV, DABVP, Cert. IVUSS, CEO of SonoPath.com

info@SonoPath.com